

## JAK inhibitors for the treatment of VEXAS syndrome

Sara Bindoli<sup>1</sup> , Chiara Baggio<sup>1</sup>, Andrea Doria<sup>1</sup> , Eugenia Bertoldo<sup>2,3</sup> and Paolo Sfriso<sup>1</sup>

<sup>1</sup>Rheumatology Unit, Department of Medicine, University of Padova, 35128 Padova, Italy; <sup>2</sup>Rheumatology Unit, Department of Medicine, University of Verona, 37129 Verona, Italy; <sup>3</sup>Internal Medicine Unit, Department of Medicine, Mater Salutaris Hospital, 37045, Legnago, Italy  
Corresponding author: Paolo Sfriso. Email: paolo.sfriso@unipd.it

### Impact Statement

Vacuoles, E1 enzyme, X-linked, autoinflammatory, somatic (VEXAS) syndrome is a new described and genetically proven entity for which the therapeutic approach is still debated. Our work provides a description of a case in which the therapeutic choice was directed toward the selective JAK-1 inhibitor filgotinib. Indeed, Janus kinase inhibitors (JAK-I) represent a promising option for the treatment of several VEXAS manifestations, and there are only a few cohorts of patients affected by VEXAS for which this therapeutic strategy was adopted, with satisfactory results. However, to our knowledge, this is the first described case in which filgotinib was employed. Since the JAK-STAT pathway, involved in several inflammatory disorders, is a key element in the pathophysiology of this disorder and, in turn, in the expression of the clinical manifestations, we included a mini review that illustrates the VEXAS cases treated with JAK-I so far.

### Abstract

Vacuoles, E1 enzyme, X-linked, autoinflammatory, somatic (VEXAS) syndrome is a novel described autoinflammatory entity for which the diagnosis is defined by somatic mutations of the *UBA1* X-linked gene in hematopoietic progenitor cells. The clinical manifestations are heterogeneous since they range from autoinflammatory symptoms to the presence of underlying hematologic disorders such as myelodysplastic syndromes. Response to treatment in VEXAS is very poor and to date, the therapeutic strategies adopted are only partially effective. However, recently described cohorts of subjects with VEXAS treated with Janus kinase inhibitors (JAK-I) proved that these drugs can be effective in the treatment of several manifestations related to the disease. Herein, we carried out a brief literature review that includes cohorts and single cases in which JAK-I were adopted as a promising strategy to manage VEXAS patients. Subsequently, we described our experience with JAK-I in VEXAS, illustrating the first case, to our knowledge, of a 65-year-old man who was successfully treated with the selective JAK-1 inhibitor filgotinib.

**Keywords:** VEXAS, JAK inhibitors, filgotinib, autoinflammatory syndrome, myelodysplastic syndrome, chondritis

**Experimental Biology and Medicine 2023; X: 1–5. DOI: 10.1177/15353702231165030**

VEXAS syndrome is a novel described autoinflammatory hematological disease<sup>1</sup> that embodies a mosaic of different clinical and biological manifestations that can make the diagnosis quite challenging. VEXAS syndrome was first described in 2020, in 25 males with inflammatory features developed after the fifth decade of life, presenting with various hematological abnormalities; they all had somatic mutations affecting methionine-41 (p.Met41) in the *UBA1* gene (on chromosome X), which encodes for the major E1 enzyme that initiates the ubiquitylation cascade.<sup>2</sup> Several VEXAS cases have been described in single reports or in larger case series to date.<sup>3–6</sup> Once established that only the genetic analysis can confirm the diagnosis, the main challenge remains how to properly treat patients with VEXAS at present. Different approaches have been proposed, from hypomethylating agents,<sup>7</sup> passing by glucocorticoids and biologic

disease-modifying antirheumatic drugs (bDMARDs) such as anti-interleukin (IL)-6 or anti-IL-1, although the latter with conflicting evidences,<sup>6,8,9</sup> but particular attention has recently focused on JAK-I.<sup>5</sup>

The use of JAK-I for the treatment of VEXAS syndrome has hardly been reported to date. The current literature reports only a few case series on the topic, and the number of patients treated with JAK-I as a second line strategy, after multidrug failures (mostly steroids, conventional synthetic [cs] disease-modifying antirheumatic drug [DMARDs], bDMARDs, azacytidine, and calcineurin inhibitors), is very limited (Table 1). The relative literature was searched in PubMed and Embase in December 2022. The terms related to “VEXAS” and all the synonyms for “JAK-I” were matched. The largest cohort of VEXAS subjects treated with JAK-I is described in a multicenter international study by Heiblig

*et al.*<sup>5</sup> In this retrospective analysis carried out in 30 patients, 12 were treated with ruxolitinib, 11 with tofacitinib, four with baricitinib, and three with upadacitinib. In general, 50% of the patients had a clinical response after one month of treatment; a marked laboratory improvement, reported as 50% reduction in C-reactive protein (CRP) levels, was observed in 20 patients, while a complete response was assessed in 11 of them. According to a subgroup analysis carried out by the authors, ruxolitinib appeared to have a better efficacy compared to other JAK-I at one and six months, especially on the hematologic side (mean hemoglobin levels) regardless of the association or not with an underlying myelodysplastic syndrome (MDS). In addition, at 6.9 months, the 75% of the patients were still receiving ruxolitinib, while only the 28% were still on therapy with a JAK-I other than ruxolitinib.<sup>5</sup> This effect probably relies on the mechanism of action on JAK1 and JAK2, rather than JAK1 and JAK3 (as for tofacitinib), and on the inhibitory activity exerted on tyrosine kinases 2 (TYK-2), a member of the Janus kinase (JAK) family of receptor-associated tyrosine kinases ubiquitously expressed in blood cells.<sup>10,11</sup> The largest VEXAS cohort reported by the French VEXAS Study Group consists of 116 patients.<sup>3</sup> Of these, 15 received JAK-I (no type specified). The use of JAK-I in this cohort was restricted to 10 patients belonging to cluster 1 and five of cluster 3, regardless of the type of mutation. JAK-I were indeed employed in patients with mild-to-moderate disease with fewer constitutional symptoms, less lung involvement, lymph node enlargement and/or unprovoked venous thrombosis, but also in those characterized by older age, more frequent weight loss, less chondritis, more cutaneous vasculitis, and higher CRP median values.<sup>3</sup> In another report of 11 genetically proven VEXAS, three patients received JAK-I (one tofacitinib and two ruxolitinib); ruxolitinib, administered in monotherapy after azacytidine failure, resulted in a spectacular regression of skin lesions in one patient.<sup>6</sup> Other small case series or reports described the use of baricitinib,<sup>12</sup> upadacitinib,<sup>4</sup> ruxolitinib,<sup>13</sup> and tofacitinib<sup>14-18</sup> (see Table 1).

In our experience, we aimed to employ filgotinib, a selective JAK-1 inhibitor, to treat our patient. A 65-year-old man was admitted to the general hospital for hyperpyrexia (max. 39°C), unilateral pleural effusion, worsening dyspnea in the last 20 days, and moderate asthenia, despite several courses of large-spectrum antibiotics. Two months earlier, an episode of chondritis of the ears occurred along with a discrete tenosynovitis of both wrists. His past history included a radical prostatectomy due to prostate cancer in 2012 and subsequently radiation therapy (70 Gy) treatment, following remission. Over the past two years, he developed a lower limbs leukocytoclastic vasculitis presenting with erythematous macules with palpable purpura bilaterally, treated with azathioprine and low dose glucocorticoids (methylprednisolone 8 mg/day). In October 2021, he had an episode of deep vein thrombosis (DVT) on the left femoral-iliac axis, treated with apixaban. In November 2020 due to progressive asthenia, fatigue, and the finding of cytopenia in laboratory exams, he underwent bone marrow biopsy (BMB). The histological analysis showed a reduction in cellularity (20%) and described maturation and topographical disorders aspects. Subsequently, the karyotype was analyzed (normal) and the

paroxysmal nocturnal hemoglobinuria (PNH) clone resulted negative as well.

During hospitalization, laboratory data revealed a marked macrocytic anemia (lowest Hb 7.7 g/L with MCV 104 fL), which required multiple blood transfusions; white blood cell count (WBC) was 2300 mmc/L, with platelets count 200,000 mmc/L, and a slight increase in CRP 16 mg/L (normal value < 5 mg/L) was observed. The autoimmunity panel was negative (rheumatoid factor [RF], antineutrophil cytoplasmic antibodies [ANCA], and antinuclear antibodies [ANA]). Furthermore, the serological tests to detect viral and bacterial antigens and antibodies of the most common pathogens resulted negative, as well as urine microbiological analysis and multiple blood cultures. A chest X-ray revealed a conspicuous unilateral pleural effusion; therefore, after a confirmatory chest computed tomography (CT), that also detected pulmonary infiltrates, he underwent suction-assisted thoracentesis with consistent exudative fluid drainage (negative serology). To exclude other infectious foci, an echocardiography was performed, and a positron emission tomography (PET)-CT showed an area of hypermetabolism at the inferior left lung lobe, at wrists, and a general activation of the bone marrow was detected (standardized uptake values [SUVs] not available); neoplastic processes or occult infections were ruled out. In addition, a review of the specimen derived from the BMB executed for the MDS, did not reveal the presence of vacuolization in myeloid precursors. Therefore, after the exclusion of potential mimics and given the mosaic of clinical manifestations (macrocytic anemia, chondritis, tenosynovitis, leukocytoclastic vasculitis, DVT, pleural effusion, and MDS, see Figure 1), evoking an inflammatory syndrome compatible with VEXAS, a genetic analysis was requested. Meanwhile, the patient was discharged afebrile, but still complained of marked asthenia (requiring several blood transfusions after the discharge) and dyspnea due to the persistence of the pleural effusion, despite two thoracenteses. His therapy at discharge included methylprednisolone 16 mg/day, indomethacin 50 mg/day, and apixaban 10 mg/day. Genetic analysis was conducted via next-generation sequencing (NGS)-based panel (69 genes) and subsequently whole exome sequencing. The analysis showed the variant c.121A>C (Met41Leu) on *UBA1* gene (Xp11.3). Furthermore, the heterozygous variant c.144del p.(Arg49Glyfs \* 4) in the *CECR1* gene (22q11.1) was detected together with the unknown variant c.3G>T p.(Met1?) on *PRF1* gene (10q22.1). After a few weeks, the patient started filgotinib at a dose of 200 mg/day in association with methylprednisolone 16 mg/day. After 1.5 month of therapy, the patient reported a substantial clinical improvement on asthenia and dyspnea. The laboratory exams showed an initial improvement: Hb 9.4 g/L, MCV 106 fL, platelets  $126,000 \times 10^3/\mu\text{L}$ , CRP 2.2 mg/L; after two months his clinical conditions generally ameliorated, and he did not complain fever, chondritis, dyspnea, or asthenia. The cytology obtained from the peripheral blood smear of our patient is shown in Figure 1.

It is well-known that components of the JAK/STAT pathway can be mutated or upregulated in several hematologic malignancies, and specifically, JAK-1 inhibitors are currently approved for use in the treatment of different

**Table 1.** Described cohorts of VEXAS patients treated with JAK-I (up to December 2022).

Number of patients treated with JAK-I employed in second line	Outcome	UBA1 mutation	Coexisting hematological disorder	References
12 ruxolitinib 11 tofacitinib 4 baricitinib 3 upadacitinib	Overall, the 50% of the patients had a clinical response after one month of treatment, while a marked laboratory improvement, reported as 50% reduction of C-reactive protein levels, was observed in 20 patients Ruxolitinib treated: at last FU, nine still on therapy, one HSCT, and two deaths Other JAK-I treated: at last FU, five still on therapy, one withdrawal, and one death	c.122T>C (p.Met41Thr) c.121A>C (p.Met41Leu) c.121A>G (p.Met41Val) c.118-1G>C (splice) c.118-2T>C (splice)	MDS Atypical MDS Essential thrombocytopenia	Heiblig <i>et al.</i> <sup>5</sup>
15 received JAK-I (no class or type is specified) - 10 patients cluster 1 (mild-to-moderate disease) - 5 patients cluster 3 (older patients)	Not specified for the sub-cohorts of JAK-I treated	p.Met41Thr (c.122T>C) p.Met41Val (c.121A>G) p.Met41Leu (c.121A>C)	MDS (not specified for each JAK-I treated)	Georgin-Lavialle <i>et al.</i> <sup>3</sup>
1 tofacitinib 2 ruxolitinib	Spectacular regression of the cutaneous lesions in the patient treated with ruxolitinib Death in patient treated with tofacitinib, 83 years old	(Met41Leu, Met41thr) (met41Thr)	MDS-MLD R-IPSS score 0 (on one ruxolitinib treated)	Bourbon <i>et al.</i> <sup>6</sup>
1 upadacitinib 15 mg/day	Disease remission after upadacitinib starting	c.122T>C (p.Met41Thr)	MDS with multilineage dysplasia	Muratore <i>et al.</i> <sup>4</sup>
1 baricitinib	Still transfusion dependent	c.122T>C (p.Met41Thr)	low-risk MDS IPSS-R: 3	Islam <i>et al.</i> <sup>12</sup>
1 tofacitinib	Resolution of inflammation	NA	MDS	Beecher <i>et al.</i> <sup>18</sup>
1 tofacitinib 5 mg twice/day	Unknown	p.Met41Val missense mutation	myeloid dysplasia	Habershon <i>et al.</i> <sup>14</sup>
Tofacitinib Ruxolitinib	Unknown	Unknown for the JAK-treated	Unknown	Casal Moura <i>et al.</i> <sup>15</sup>
1 tofacitinib up to 20 mg day	No clinical benefit during the three months applied. HSCT later considered due to multidrug failure	p.Met41Thr (c.122T>C)	MDS with multilineage dysplasia (MDS-MLD)	Lötscher <i>et al.</i> <sup>17</sup>
1 ruxolitinib 15 mg twice day	Improvement with ruxolitinib, later died for sepsis	c.122T>C (p.Met41Thr)	HLH-MAS	Kao <i>et al.</i> <sup>13</sup>
1 tofacitinib unknown posology	Unknown	c.122T>C (p.Met41Thr)	No	Koster <i>et al.</i> <sup>16</sup>
1 filgotinib 200 mg/day	General biological and clinical improvement after two months of treatment	p.Met41Leu, (c.121A>C)	MDS	Current case

VEXAS: vacuoles, E1 enzyme, X-linked, autoinflammatory, somatic; FU: follow up; JAK-I: Janus kinase inhibitors; HSCT: hematopoietic stem-cell transplantation; MDS: myelodysplastic syndrome; MLD: multilineage dysplasia; IPSS: revised international prognostic scoring system; HLH: hemophagocytic lymphohistiocytosis; MAS: macrophage activation syndrome.

blood disorders such as myelofibrosis and polycythemia vera.<sup>19,20</sup> Filgotinib is a second-generation preferential JAK-1 inhibitor that modulates a subset of pro-inflammatory cytokines within the JAK-STAT pathway, which differ from those inhibited by anti-JAK-2 or anti-JAK-3 drugs. To our knowledge, our case is the first to describe the successful employment of filgotinib; therefore, we can postulate that the efficacy of filgotinib relies on the satisfactory outcomes recently observed with other selective JAK-1 inhibitors such as upadacitinib or the JAK-1/2 and tyrosine kinase blocker ruxolitinib. Regarding safety, it is difficult to

establish, as VEXAS syndrome itself can also lead to infectious and thromboembolic events; however, the safety and tolerability of filgotinib have been widely assessed and no major concerns about safety have arisen in the last months.<sup>21</sup> In our description, it is interesting that two other variants were contextually detected at whole exome sequencing: c.144del p.(Arg49Glyfs\*4) on the *CECR1* gene (heterozygous) is associated with deficiency of adenosine deaminase (*DADA*) 2. However, as the sole heterozygous variant is not sufficient to explain the clinical phenotype since the autosomal recessive inheritance. The second single nucleotide

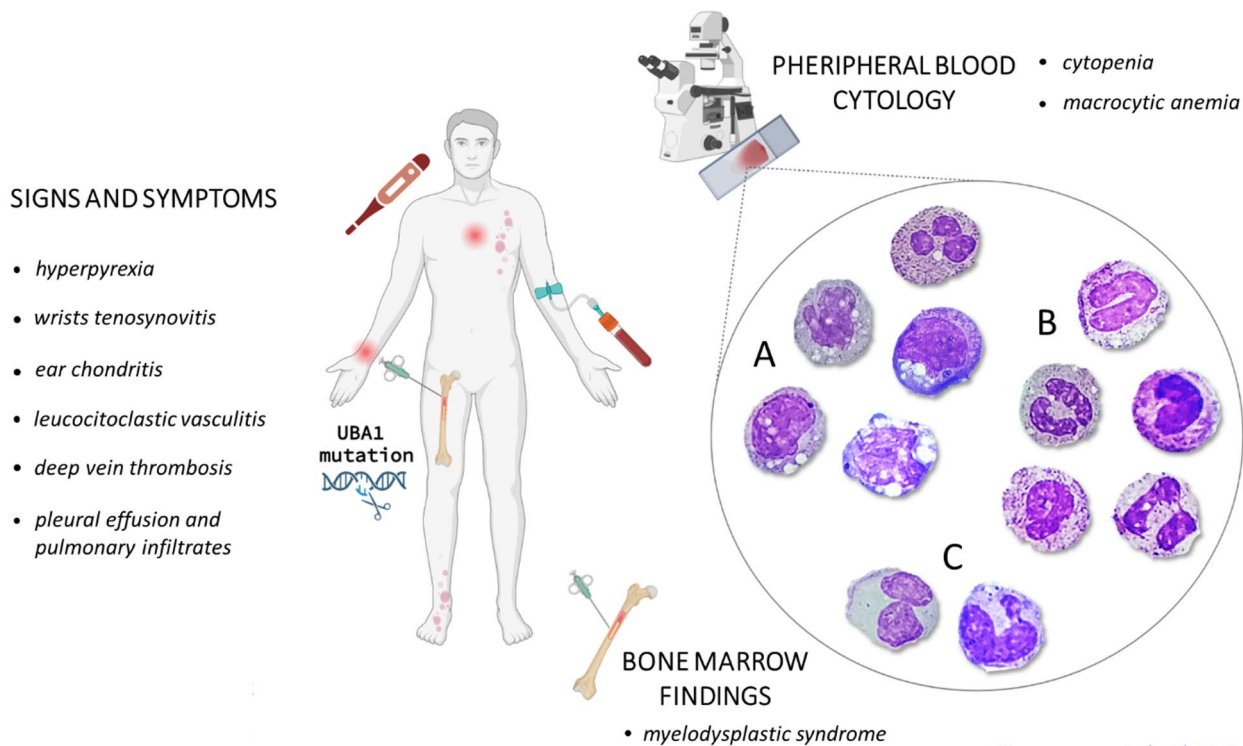


Figure was created with BioRender.com

**Figure 1.** Peripheral blood smear of our patient and clinical manifestations. In the circle are observed granulocytes with morphological changes, including (A) cytoplasmic vacuoles (2%) and (B) immature neutrophils (29.8%) such as band neutrophils, hyposegmented neutrophils, and pseudo Pelger–Huët-like morphology. Vacuolated/activated monocytes (4.5%) (A) and nuclear abnormality–included binucleated cells and buds (2.5%) (C) were also observed. May Grunwald–Giemsa staining was used for studying cellular morphology in and to perform a cytogenic evaluation of leucocytes. Oil immersion microscopy with 1000 $\times$  magnification was applied for the analysis.

variant detected, c.3G>T p.(Met1?) on the *PRF1* gene has not been reported until now; however, more variants localized at the same aminoacidic codon related to methionine loss have been reported, and may be associated with familial hemophagocytic lymphohistiocytosis. Likewise, the sole heterozygosity of this variant is not sufficient to explain the clinical phenotype since the autosomal recessive inheritance. Our patient presented with typical VEXAS symptoms and no signs of hemophagocytosis in BMB or other clinical manifestations were compatible with *DADA2* (despite vasculitic manifestations can occur in both the pathologies). Therefore, the final diagnosis of VEXAS was confirmed based on the mutation in *UBA1*.

In conclusion, larger cohorts are necessary to establish if, due to the lack of specific therapies and based on the remarkable outcomes, JAK-I are candidable as first-line therapy in VEXAS. The wide heterogeneity of the clinical presentations of the syndrome requires an accurate and more extensive clusterization of patients that will be essential for the correct clinical and therapeutic management.

#### AUTHORS' CONTRIBUTIONS

SB and PS contributed to the conception and design of the work, and interpretation of data; CB carried out the laboratory part and revised the work; EB contributed to the conception of the work and revised the work; AD revised the work. All the authors approved the final version to be published.

#### DECLARATION OF CONFLICTING INTERESTS

The author(s) declared no potential conflicts of interest with respect to the research, authorship, and/or publication of this article.

#### ETHICAL APPROVAL

The study was performed in accordance with the principles of the Declaration of Helsinki. The participant gave the fully informed written consent for images publication.

#### FUNDING

The author(s) received no financial support for the research, authorship, and/or publication of this article.

#### ORCID IDS

Sara Bindoli  <https://orcid.org/0000-0002-9409-3329>

Andrea Doria  <https://orcid.org/0000-0003-0548-4983>

#### REFERENCES

- Grayson PC, Patel BA, Young NS. VEXAS syndrome. *Blood* 2021;137:3591–4
- Beck DB, Ferrada MA, Sikora KA, Ombrello AK, Collins JC, Pei W, Balanda N, Ross DL, Ospina Cardona D, Wu Z, Patel B, Manthiram K, Groarke EM, Gutierrez-Rodrigues F, Hoffmann P, Rosenzweig S, Nakabo S, Dillon LW, Hourigan CS, Tsai WL, Gupta S, Carmona-Rivera C, Asmar AJ, Xu L, Oda H, Goodspeed W, Barron KS, Nehrebecky M, Jones A, Laird RS, Deutch N, Rowczenio D, Rominger E, Wells KV, Lee C-CR, Wang W, Trick M, Mullikin J, Wigerblad G,

- Brooks S, Dell'Orso S, Deng Z, Chae JJ, Dulau-Florea A, Malicdan MCV, Novacic D, Colbert RA, Kaplan MJ, Gadina M, Savic S, Lachmann HJ, Abu-Asab M, Solomon BD, Retterer K, Gahl WA, Burgess SM, Aksentijevich I, Young NS, Calvo KR, Werner A, Kastner DL, Grayson PC. Somatic mutations in UBA1 and severe adult-onset autoinflammatory disease. *N Engl J Med* 2020;383:2628–38
3. Georjin-Lavialle S, Terrier B, Guedon AF, Heiblig M, Comont T, Lazaro E, Lacombe V, Terriou L, Ardois S, Bouaziz JD, Mathian A, Le Guenno G, Aouba A, Outh R, Meyer A, Roux-Sauvat M, Ebbo M, Zhao LP, Bigot A, Jamilloux Y, Guillotin V, Flamarion E, Hennequin P, Vial G, Jachiet V, Rossignol J, Vinzio S, Weitten T, Vinit J, Deligny C, Humbert S, Samson M, Magy-Bertrand N, Moulinet T, Bourguiba R, Hanslik T, Bachmeyer C, Sebert M, Kostine M, Bienvenu B, Biscay P, Liozon E, Sailler L, Chasset F, Audemard-Verger A, Duroyon E, Sarrabay G, Borlot F, Dieval C, Cluzeau T, Marianetti P, Lobbes H, Boursier G, Gerfaud-Valentin M, Jeannel J, Servettaz A, Audia S, Larue M, Henriot B, Faucher B, Graveleau J, de Sainte Marie B, Galland J, Bouillet L, Arnaud C, Ades L, Carrat F, Hirsch P, Fenaux P, Fain O, Sujobert P, Kosmider O, Mekinian A. Further characterization of clinical and laboratory features in VEXAS syndrome: large-scale analysis of a multicentre case series of 116 French patients. *Br J Dermatol* 2022; **186**:564–74
  4. Muratore F, Marvisi C, Castrignanò P, Nicoli D, Farnetti E, Bonanno O, Longo R, Zaldini P, Galli E, Balandà N, Beck DB, Grayson PC, Pipitone N, Boiardi L, Salvarani C. VEXAS syndrome: a case series from a single-center cohort of Italian patients with vasculitis. *Arthritis Rheumatol* 2022;74:665–70
  5. Heiblig M, Ferrada MA, Gerfaud-Valentin M, Barba T, Mékinian A, Koster M, Coelho H, Fossard G, Barraco F, Galicier L, Bienvenu B, Hirsch P, Vial G, Boutin AB, Le guenno G, Bigot A, Warrington K, Kermani T, Jamilloux Y, Grayson PC, Patel BA, Beck DB, Fenaux P, Sujobert P. Clinical efficacy of JAK inhibitors in patients with VEXAS syndrome: a multicenter retrospective study. *Blood* 2021;138:2608
  6. Bourbon E, Heiblig M, Gerfaud Valentin M, Barba T, Durel CA, Lega JC, Barraco F, Sève P, Jamilloux Y, Sujobert P. Therapeutic options in VEXAS syndrome: insights from a retrospective series. *Blood* 2021;137:3682–4
  7. Raaijmakers MHGP, Hermans M, Aalbers A, Rijken M, Dalm VASH van Daele P, Valk PJM. Azacytidine treatment for VEXAS syndrome. *Hemasphere* 2021;5:e661
  8. Kirino Y, Takase-Minegishi K, Tsuchida N, Hirahara L, Kunishita Y, Yoshimi R, Nakajima H. Tocilizumab in VEXAS relapsing polycondritis: a single-center pilot study in Japan. *Ann Rheum Dis* 2021;80:1501–2
  9. van der Made CI, Potjewijd J, Hoogstins A, Willems HPJ, Kwakernaak AJ, de Sevaux RGL, van Daele PLA, Simons A, Heijstek M, Beck DB, Netea MG, van Paassen P, Elizabeth Hak A, van der Veken LT, van Gijn ME, Hoischen A, van de Veerdonk FL, Leavis HL, Rutgers A. Adult-onset autoinflammation caused by somatic mutations in UBA1: a Dutch case series of patients with VEXAS. *J Allergy Clin Immunol* 2022;149:432–9.e4
  10. Burke JR, Cheng L, Gillooly KM, Strnad J, Zupa-Fernandez A, Catlett IM, Zhang Y, Heimrich EM, McIntyre KW, Cunningham MD, Carman JA, Zhou X, Banas D, Chaudhry C, Li S, D'Arienzo C, Chimalakonda A, Yang XX, Xie JH, Pang J, Zhao Q, Rose SM, Huang J, Moslin RM, Wroblewski ST, Weinstein DS, Salter-Cid LM. Autoimmune pathways in mice and humans are blocked by pharmacological stabilization of the TYK2 pseudokinase domain. *Sci Transl Med* 2019;11:eaaw1736
  11. Winthrop KL. The emerging safety profile of JAK inhibitors in rheumatic disease. *Nat Rev Rheumatol* 2017;13:234–43
  12. Islam S, Cullen T, Sumpton D, Damodaran A, Heath D, Bosco A, Doo NW, Kidson-Gerber G, Cheong A, Lawford R, Walsh R, Sammel A. VEXAS syndrome: lessons learnt from an early Australian case series. *Intern Med J* 2022;52:658–62
  13. Kao RL, Jacobsen AA, Billington CJ Jr, Yohe SL, Beckman AK, Vercellotti GM, Pearson DR. A case of VEXAS syndrome associated with EBV-associated hemophagocytic lymphohistiocytosis. *Blood Cells Mol Dis* 2022;93:102636
  14. Habershon C, Budzillo M, Wong R, Tate C, Warwick R, Drone L. VEXAS syndrome: a case of treatment refractory, severe autoinflammatory disease. *Intern Med J* 2022;52:26
  15. Casal Moura M, Baqir M, Tandon Y, Samec MJ, Reichard KK, Mangaonkar A, Go RS, Warrington KJ, Patnaik M, Koster MJ, Ryu JH. Lung involvement in VEXAS syndrome. *Arthritis Rheumatol* 2022;74
  16. Koster MJ, Kourelis T, Reichard KK, Kermani TA, Beck DB, Cardona DO, Samec MJ, Mangaonkar AA, Begna KH, Hook CC, Oliveira JL, Nasr SH, Tiong BK, Patnaik MM, Burke MM, Michet CJ Jr, Warrington KJ. Clinical heterogeneity of the VEXAS syndrome. *Mayo Clin Proc* 2021;96:2653–9
  17. Lötscher F, Seitz L, Simeunovic H, Sarbu A-C, Porret NA, Feldmeyer L, Borradori L, Bonadies N, Maurer B. Case report: genetic double strike: VEXAS and TET2-positive myelodysplastic syndrome in a patient with long-standing refractory autoinflammatory disease. *Front Immunol* 2022;12:800149
  18. Beecher MB, Tong JY, Halliday LA, Hissaria P, Selva D. Recurrent orbital inflammation associated with VEXAS syndrome. *Orbit*. Epub ahead of print 27 September 2022. DOI: 10.1080/01676830.2022.2126501
  19. Mascarenhas J. Selective Janus associated kinase 1 inhibition as a therapeutic target in myelofibrosis. *Leuk Lymphoma* 2015;56:2493–7
  20. Koschmieder S, Isfort S, Wolf D, Heidel FH, Hochhaus A, Schafhausen P, Griesshammer M, Wolleschak D, Platzbecker U, Döhner K, Jost PJ, Parmentier S, Schaich M, von Bubnoff N, Stegelmann F, Maurer A, Crysandt M, Gezer D, Kortmann M, Franklin J, Frank J, Hellmich M, Brümmendorf TH. Efficacy and safety of ruxolitinib in patients with newly-diagnosed polycythemia vera: futility analysis of the Ruxo-BEAT clinical trial of the GSG-MPN study group. *Ann Hematol* 2023; **102**:349–58
  21. Alves C, Penedones A, Mendes D, Marques FB. The risk of infections associated with JAK inhibitors in rheumatoid arthritis. *JCR J Clin Rheumatol* 2022;28:e407–14