

# Rare Neoplasm Mimicking Neuroendocrine Pancreatic Tumor: A Case Report of Solitary Fibrous Tumor with Review of the Literature

FRANCESCO E. D'AMICO<sup>1,2</sup>, CESARE RUFFOLO<sup>2</sup>, MAURIZIO ROMANO<sup>1</sup>,  
MARINA DI DOMENICO<sup>3,4</sup>, MARTA SBARAGLIA<sup>5</sup>, ANGELO P. DEI TOS<sup>5</sup>,  
TIZIANA GAROFALO<sup>6</sup>, ANTONIO GIORDANO<sup>4</sup>, NICCOLÒ BASSI<sup>1,2</sup> and MARCO MASSANI<sup>2</sup>

<sup>1</sup>Department of Surgical, Gastrointestinal and Oncological Sciences (DiSCOG),  
University of Padua, Padova, Italy;

Departments of <sup>2</sup>Surgery (IV unit) and <sup>5</sup>Pathology, Regional Hospital "Ca' Foncello", Treviso, Italy;

<sup>3</sup>Department of Biochemistry, Biophysics and General Pathology,  
University of Campania "Luigi Vanvitelli", Naples, Italy;

<sup>4</sup>Sbarro Institute for Cancer Research and Molecular Medicine,  
Center of Biotechnology, Temple University, Philadelphia, PA, U.S.A.;

<sup>6</sup>UOC Oncology, AORN dei Colli "Monaldi", Naples, Italy

**Abstract.** *Background:* Solitary fibrous tumors (SFTs) are rare biological entities described mainly in the pleura. To date, in the pancreas, only 14 cases have been reported in the English literature. *Case Report:* A 52-year-old male was diagnosed incidentally with a suspected neuroendocrine tumor (NET) of the pancreas. He underwent pancreatic enucleation of the mass, which, at final pathology, showed spindle cell proliferation set in a collagenous background and featuring the presence of hemangiopericytoma-like blood. Immunohistochemistry showed cytoplasmic expression of CD34 and nuclear expression of STAT6. As mitotic activity was of 1 mitoses/10 high-power fields (HPFs) a diagnosis of conventional SFT was made. The patient was discharged without major complications and is alive and free of disease after 24 months. *Conclusion:* SFTs of pancreas are rare tumors, often mimicking pancreatic NET.

Primary mesenchymal tumors of the pancreas are extremely rare. In particular, solitary fibrous tumors (SFTs) are even more

This article is freely accessible online.

*Correspondence to:* Marina Di Domenico, Department of Biochemistry, Biophysics and General Pathology, University of Campania "Luigi Vanvitelli" Via L. De Crecchio, 3, 80128, Naples (NA), Italy. Tel: +39 0815667558, Fax: +39 081450169/+39 0815667555, e-mail: marina.didomenico@unina2.it

*Key Words:* Pancreas neoplasm, mesenchymal tumors, solitary fibrous tumor, neuroendocrine tumor, sarcoma.

rarely reported in the English literature. The most frequent site where SFT, also known as benign localized mesothelioma, has been reported is the pleura (1). Further studies have documented that this tumor lacks mesothelial markers and is currently classified within the group of "fibroblastic" mesenchymal neoplasms. The actual incidence of SFT is difficult to estimate as, in the past, most cases have been collected under the now abolished label "hemangiopericytoma" (2, 3). Extra-pleural sites represent approximately 50% of cases; however, to our knowledge, only 17 pancreatic SFTs have been reported in the literature, of which 14 in the English literature. Due to possible complications related with pancreatic surgery, even rare and almost anecdotal, it is important to pay special attention to this entity.

## Case Report

A previously healthy 52-year-old man was referred to our Department for a dysplastic polyp of the right colon that was considered endoscopically non-removable. A preoperative computerized tomography (CT) scan documented a 12-mm hypodense lesion of the pancreatic body (Figure 1) during the arterial phase and hypervascular during the venous phase (Figure 2). CT appearance of the lesion was compatible with a neuroendocrine tumor (NET) and this impression was confirmed by magnetic resonance imaging (MRI). Blood tests did not show any alteration of the neoplastic markers carcinoembryonic antigen (CEA) and carbohydrate antigen (CA)19-9. The patient underwent right hemicolectomy along with enucleation of the pancreatic lesion. His postoperative

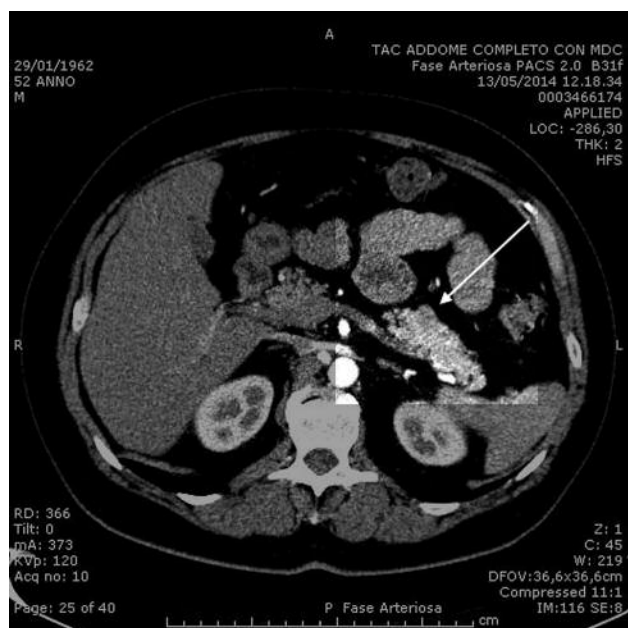


Figure 1. Arterial phase of computed tomography (CT) scan. The arrow shows a hypodense mass in the pancreatic body.

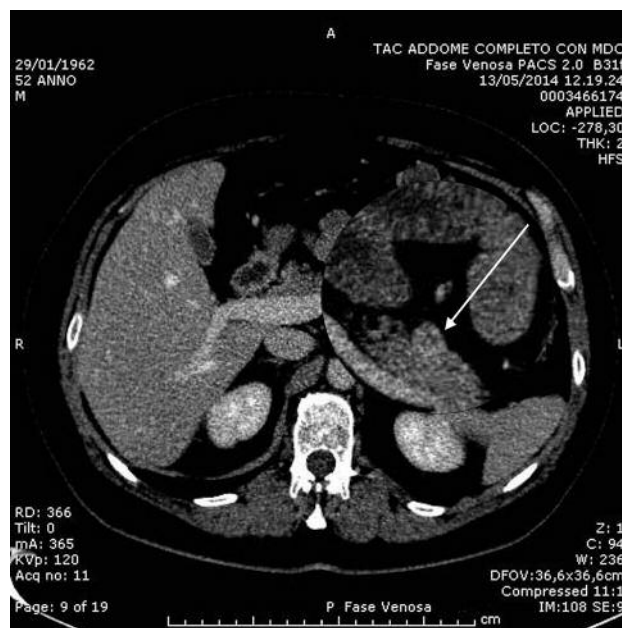


Figure 2. Venous phase of computed tomography (CT) scan. The arrow shows a hypervascular mass in the pancreatic body.

course was complicated by anemia, conservatively treated, and low output pancreatic fistula. The patient was discharged on postoperative day 14 with an abdominal drainage in place, subsequently removed during the outpatient follow-up. The patient is alive with no evidence of disease after 24 months of follow-up.

**Pathology.** The lesion was 2 cm in size and represented by a spindle cell proliferation set in a collagenous background featuring the presence of hemangiopericytoma-like blood vessels (Figure 3). Immunohistochemically, the tumor showed the typical immunophenotype represented by cytoplasmic expression of CD34 and nuclear expression of STAT6 (Figure 4). As mitotic activity was of 1 mitoses/10 high-power fields (HPFs), a diagnosis of conventional SFT was made.

## Discussion

SFT is a mesenchymal neoplasm currently classified by the World Health Organization (WHO) within the fibroblastic subgroup (4, 5). It typically affects adults between 20 and 70 years. The pleura is the site most frequently reported; however, SFT can also arise in the peritoneum, meninges, soft tissue of the extremities as can be basically found in any body site (6-8). Recently, it has been shown that SFT is also characterized by the presence of a *NAB2-STAT6* gene fusion

(9). Approximately 12-22% of SFTs are malignant. However, assessment of metastatic risk is still a source of debate. England *et al.* and Vallat-Decouvelaere *et al.* defined SFT malignancy on the basis of nuclear atypia, hypercellularity, mitotic activity greater than 4 mitosis/10 HPFs and necrosis (10, 11). Unfortunately, even in the absence of these criteria, aggressive behavior is still possible. As a consequence, no SFT should be labeled as benign.

As already mentioned, the pleura is the site where SFT arises most frequently. In the literature, there are less than 800 cases of pleural SFTs described so far. At this site, SFT shows an unpredictable behavior as, in a case series by Sung *et al.*, 30.2% of the specimens showed malignant features according with the 2003 classification. Disease control is frequently achieved with local resection for tumors not featuring malignant features; however, when overt histologic findings of malignancy are present, a 63% recurrence rate - even with complete resection- is observed. Unfortunately, in consideration of small numbers, data about recurrence or survival are not that accurate and no established treatment modality or follow-up plan has been agreed on.

To our knowledge, there are 17 cases of primary SFTs of the pancreas, of which only 14 in the English literature. Herein, we describe a further case of this rare entity reported for the first time by Lüttges *et al.* in 1999 (12). Pancreatic SFT is often an incidental finding, relatively often mistaken for a NET due to its radiological appearance. Sometimes,

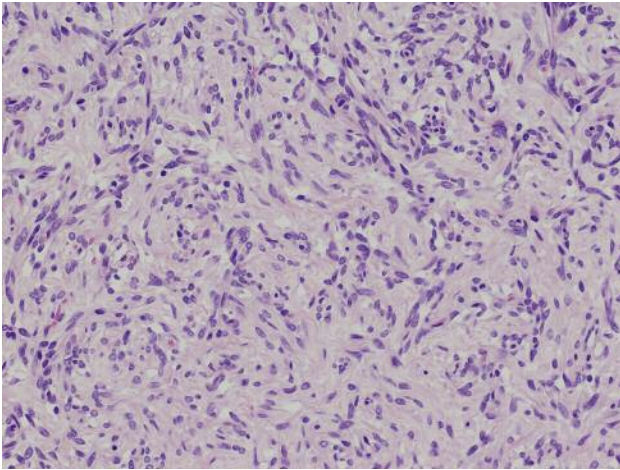


Figure 3. Patternless spindle cell neoplastic proliferation. Hematoxylin and Eosin staining, 20× magnification.

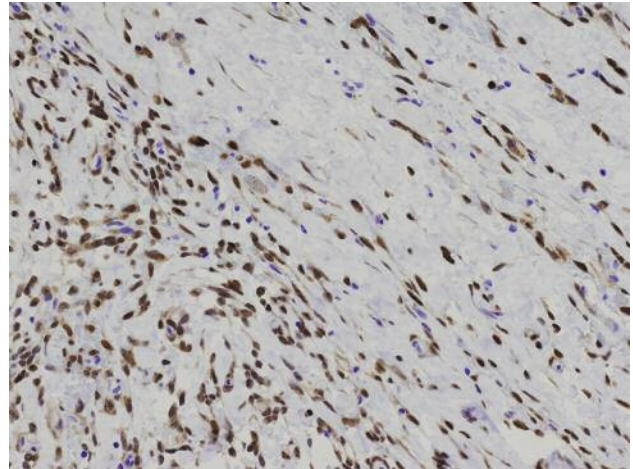


Figure 4. Neoplastic cells exhibit nuclear expression of STAT6. Immunohistochemistry, 20× magnification.

patients complain of vague pain or discomfort, which is difficult to relate to the nodule. As shown in Table I, median diameter of pancreatic SFT is 5.2 cm but the nodule can attain significant dimensions, as documented by Tasdemir *et al.* who described a 18.5-cm tumor (13) and by Estrella *et al.* who described a 15-cm mass causing painless jaundice (14). Patients who have been diagnosed with pancreatic SFT were in their middle age (median age=53 years) with a higher number of females compared to male sex (female:male=13:4). The head and pancreatic body are the “preferred” location with only one tumor documented in the pancreatic tail. All patients, but one (15), have been surgically treated, with one patient dying of surgical complications. Tumor enucleation is the most frequently performed surgical procedure (7 cases) followed by distal pancreatectomy (4 cases), Whipple procedure (4) and segmental pancreatic resection (1). As already mentioned, one patient was not fitted for surgery and did not undergo resection (15). In the literature, follow-up is not commonly reported; available data have shown that local recurrence or metastasis have never been described. All patients with available follow-up are alive with no evidence of disease with a median follow-up of 12 months. The only patient with malignant SFT diagnosis at pathology is still alive with no evidence of disease at 40 months (14).

Non-functional NET of the pancreas share similar epidemiological characteristics with SFT, with the mean age at presentation being 45 years and an equal distribution between men and women. Traditionally, SFTs are described as large tumors and, similarly with many other pancreatic lesions with the widespread use of high-resolution abdominal imaging, being increasingly identified as small, asymptomatic

tumors (16). Several studies explored the safety and feasibility of a non-operative management approach for asymptomatic sporadic non-functional NET  $\leq 2$  cm when a major pancreatic resection is required. A conservative approach seems to be safe as the majority of the observed tumors does not show any significant changes during follow-up (17). For larger lesions, instead, surgical treatment is usually recommended.

Although our patient did not suffer of any particular complication, pancreatic surgery could itself generate significant postoperative morbidity, especially because the tumor was located in the pancreatic head requiring, therefore, a Whipple procedure to remove it. As complete local resection may represent an adequate therapeutic approach when dealing with low-grade malignancies, and in consideration of the potentially broad range of differential diagnoses, upfront histologic confirmation should be recommended. Unfortunately, data regarding pancreatic SFT's outcome are very limited, to the extent that is almost impossible to establish a standard of care. Considering the relatively low rate of metastatic spread of conventional SFTs, complete resection of the mass -associated with follow-up- may currently represent an acceptable therapeutic approach.

In conclusion, herein, we report a further case of pancreatic SFT, reviewing its clinical behavior reported in the English and not English literature. Due to the scarcity of this tumor in the pancreas and the fact that it is currently regarded as most often having a low-grade malignant clinical behavior, in borderline-fit patients, candidates to pancreatic surgery, careful preoperative evaluation is needed. This is even more important because, frequently, a non-functional NET of the pancreas is suspected. There is limited

Table I. Clinical features of SFTs of pancreas as reported in the literature.

Reference #	Age (years)	Gender	Site	Size	CT appearance	Symptoms	Surgical procedure	Follow-up (months)	Status at last follow-up
(6)	67	F	Head	2.6	NET	Incidental	Whipple	6	NED
(7)	54	M	Body	7.6	NET/solid pseudo-papillary tumor	Incidental	Segmental pancreatectomy	NA	NA
(8)	78	F	Body	5	NET	Back pain, weight loss	Distal pancreatectomy	7	NED
(12)	50	F	Body	5.5	NET	Incidental	Distal pancreatectomy	20	NED
(13)	24	F	Head	18.5	Mesenchymal tumor	Pain	Enucleation	NA	NA
(14)	52	F	Head	15	NET	Jaundice	Whipple	40	NED
(15)	77	F	Head	1.5	NET	Incidental	None	NA	NA
(18)	66	M	Body	5.5	Adenocarcinoma/metastasis	Incidental	Enucleation	60	NED
(19)	41	M	Body	13	NET	Discomfort	Enucleation	0.1	DOD
(20)	62	F	Head	3	NET	Incidental	Whipple	16	NED
(21)	41	F	Body	2	NET	Abdominal pain	Enucleation	7	NED
(22)	55	F	Head	7	NET	Incidental	Whipple	NA	NA
(23)	40	F	Body	3	NR	Incidental	Distal pancreatectomy	NA	NA
(24)	67	F	Head	2.8	NET	Abdominal pain	Enucleation	0.1	NED
(25)	53	F	Head	5.2	Pseudopapillary epithelial neoplasm/NET	Incidental	Enucleation	NA	NA
(26)	53	M	Body	7.5	GIST/NET	Incidental	Enucleation	88	NED
(26)	52	F	Tail	2	NET	Incidental	Distal pancreatectomy	12	NED
Present	52	M	Body	2	NET	Incidental	Enucleation	20	NED

SFTs, Solitary fibrous tumors; CT, computed tomography; NR, not reported; NED, no evidence of disease; AWD, alive with disease; DOD, death of disease; NET, neuroendocrine tumor; GIST, gastrointestinal stromal tumor.

information on the clinicopathologic characteristics, benefits of various treatment modalities or prognostic factors of this lesion. Thus, more studies with accumulated data from multiple centers are important to improve our understanding of these neoplasms.

## References

- Sung SH, Chang JW, Kim J, Lee KS, Han J and Park SI: Solitary fibrous tumors of the pleura: Surgical outcome and clinical course. *Ann Thorac Surg* 79: 303-307, 2005.
- Schweizer L, Koelsche C, Sahm F, Piro RM, Capper D, Reuss DE, Pusch S, Habel A, Meyer J, Gock T, Jones DT, Mawrin C, Schittenhelm J, Becker A, Heim S, Simon M, Herold-Mende C, Mechtersheimer G, Paulus W, König R, Wiestler OD, Pfister SM and von Deimling A: Meningeal hemangiopericytoma and solitary fibrous tumors carry the NAB2-STAT6 fusion and can be diagnosed by nuclear expression of STAT6 protein. *Acta Neuropathol* 125: 651-658, 2013.
- Chan JK: Solitary fibrous tumour – everywhere, and a diagnosis in vogue. *Histopathology* 31: 568-576, 1997.
- Jo VY and Fletcher CD: WHO classification of soft tissue tumours: An update based on the 2013 (4th) edition. *Pathology* 46: 95-104, 2014.
- DeVito N, Henderson E, Han G, Reed D, Bui MM, Lavey R, Robinson L, Zager JS, Gonzalez RJ, Sondak VK, Letson GD and Conley A: Clinical characteristics and outcomes for solitary fibrous tumor (SFT): A single center experience. *PLoS One* 10: e0140362, 2015.
- Chetty R, Jain R and Serra S: Solitary fibrous tumor of the pancreas. *Ann Diagn Pathol* 13: 339-343, 2009.
- Kwon HJ, Byun JH, Kang J, Park SH and Lee MG: Solitary fibrous tumor of the pancreas: Imaging findings. *Korean J Radiol* 9(Suppl): S48-S51, 2008.
- Srinivasan VD, Wayne JD, Rao MS and Zynger DL: Solitary fibrous tumor of the pancreas: Case report with cytologic and surgical pathology correlation and review of the literature. *JOP* 9: 526-530, 2008.
- Robinson DR, Wu YM, Kalyana-Sundaram S, Cao X, Lonigro RJ, Sung YS, Chen CL, Zhang L, Wang R, Su F, Iyer MK, Roychowdhury S, Siddiqui J, Pienta KJ, Kunju LP, Talpaz M, Mosquera JM, Singer S, Schuetze SM, Antonescu CR and Chinnaiyan AM: Identification of recurrent NAB2-STAT6 gene fusions in solitary fibrous tumor by integrative sequencing. *Nat Genet* 45: 180-185, 2013.
- England DM, Hochholzer L and McCarthy MJ: Localized benign and malignant fibrous tumors of the pleura. A clinicopathologic review of 223 cases. *Am J Surg Pathol* 13: 640-658, 1989.
- Vallat-Decouvelaere AV, Dry SM and Fletcher CD: Atypical and malignant solitary fibrous tumors in extrathoracic locations: Evidence of their comparability to intra-thoracic tumors. *Am J Surg Pathol* 22: 1501-1511, 1998.
- Lüttges J, Mentzel T, Hübner G and Klöppel G: Solitary fibrous tumour of the pancreas: A new member of the small group of mesenchymal pancreatic tumours. *Virchows Archiv* 435: 5, 1999.

- 13 Tasdemir A, Soyuer I, Yurci A, Karahanli I and Akyildiz H: A huge solitary fibrous tumor localized in the pancreas: A young women. *JOP* 13: 304-307, 2012.
- 14 Estrella JS, Wang H, Bhosale PR, Evans HL and Abraham SC: Malignant solitary fibrous tumor of the pancreas. *Pancreas* 44: 988-994, 2015.
- 15 Han SH, Baek YH, Han S-y, Lee SW, Jeong JS, Cho JH and Kwon H-J: Solitary fibrous tumor of the pancreas: A case report and review of the literature. *Korean J Med* 88: 293, 2015.
- 16 Ehehalt F, Saeger HD, Schmidt CM and Grutzmann R: Neuroendocrine tumors of the pancreas. *The Oncologist* 14: 456-467, 2009.
- 17 Gaujoux S, Partelli S, Maire F, D'Onofrio M, Larroque B, Tamburrino D, Sauvanet A, Falconi M and Ruszniewski P: Observational study of natural history of small sporadic nonfunctioning pancreatic neuroendocrine tumors. *J Clin Endocrinol Metab* 98(12): 4784-4789, 2013.
- 18 Adachi T, Sugiyama Y and Saji S: Solitary fibrous benign mesothelioma of the peritoneum: Report of a case. *Surg Today* 29: 915-918, 1999.
- 19 Chatti K, Nouira K, Ben Reguigua M, Bedioui H, Oueslati S, Laabidi B, Alaya M and Ben Abdallah N: Tumeur fibreuse solitaire du pancréas. *Gastroentérol Clin Biol* 30: 317-319, 2006.
- 20 Gardini A, Dubini A, Saragoni L, Padovani F, and Garcea D: Benign solitary fibrous tumor of the pancreas: A rare location of extra-pleural fibrous tumor. Single case report and review of the literature. *Pathologica* 99: 15-18, 2007.
- 21 Miyamoto H, Molena DA, Schoeniger LO and Haodong X: Solitary fibrous tumor of the pancreas: A case report. *Int J Surg Pathol* 15: 311-314, 2007.
- 22 Sugawara Y, Sakai S, Aono S, Takahashi T, Inoue T, Ohta K, Tanada M and Teramoto N: Solitary fibrous tumor of the pancreas. *Jpn J Radiol* 28: 479-482, 2010.
- 23 Santos LA, Santos VM, Oliveira OC and De Marco M: Solitary fibrous tumour of the pancreas: a case report. *An Sist Sanit Navar* 35: 133-136, 2012.
- 24 van der Vorst JR, Vahrmeijer AL, Hutteman M, Bosse T, Smit VT, van de Velde CJ, Frangioni JV and Bonsing BA: Near-infrared fluorescence imaging of a solitary fibrous tumor of the pancreas using methylene blue. *World J Gastrointest Surg* 4: 180-184, 2012.
- 25 Hwang JD, Kim JW and Chang JC: Imaging findings of a solitary fibrous tumor in pancreas: A case report. *J Korean Soc Radiol* 70: 53, 2014.
- 26 Kim JY, Song JS, Park H, Byun JH, Song KB, Kim KP, Kim SC and Hong SM: Primary mesenchymal tumors of the pancreas: Single-center experience over 16 years. *Pancreas* 43: 959-968, 2014.

*Received March 20, 2017*

*Revised May 1, 2017*

*Accepted May 2, 2017*