

Available online at www.sciencerepository.org

Science Repository



Case Report

Management of a 12-Year-Old Patient with Complex Odontoma, Impacted First Molar, Pericoronal Dentigerous Cyst and Involvement of Inferior Alveolar Nerve: A Case Report

Cerrato Alessia, Zanette Gastone, Sbricoli Luca and Bacci Christian*

Oral Surgery and Pathology, Section of Clinical Dentistry, Department of Neurosciences, University of Padova, Italy

ARTICLE INFO

Article history:

Received: 2 April, 2020

Accepted: 13 April, 2020

Published: 22 April, 2020

ABSTRACT

Complex odontoma, associated with an impacted tooth and a dentigerous cyst is a rare condition, especially in children. The management of such young patients could be difficult, and many aspects must be taken into consideration, like the patient's collaboration during the procedures and the possibility of nerve damage. In this case report, we describe how to manage these kinds of patients, in order to reduce the risks and improve cooperation, taking advantage of the great benefits of conscious sedation.

© 2020 Christian Bacci. Hosting by Science Repository.

Introduction

Tooth impaction is a relatively rare condition, which has been addressed in several studies. Thilander and Myrberg examined more than 6,000 Swedish school children and found a 5.4% prevalence of impacted teeth, excluding third molars [1]. Almost all studies agree that third molars are the most commonly impacted teeth, followed by maxillary canines. According to Dachi and Howell, the incidence of impacted tooth, excluding third molars and maxillary canines, is 0.38% [2]. Many causes are recognized for teeth impaction, but in most cases this condition suggests the presence of an obstacle to the eruption path [3].

According to a study performed by Shiun-yin Cho *et al.* in 2005, the impaction of the first and second mandibular molars is extremely rare among children without systemic syndromes [4]. As reported by the authors, impaction of one or both permanent mandibular second molars was found in 34 children in a sample of 3,053 Chinese children aged between 11 and 14 (with a mean of 12.0 years and an SD of 0.6 years), so the resulting prevalence was 1%.

A 6-month delay in eruption of a permanent mandibular molar compared with its contralateral counterpart or a 1-year delay in eruption of both molars should indicate a need for further radiographic investigation [5].

According to the WHO Classification of Odontogenic Tumors, odontomas are malformations in which all the dental tissues are represented. There are two kinds of odontoma, complex and compound. The distinction between complex and compound odontomas is arbitrary, being based on a preponderance of disorganised dental tissues in the former as against a preponderance of well-organised denticles in the latter rather than on any absolute difference [6]. Odontomas are one of the most common mandibular lesions, and the most common odontogenic tumours of the mandible, typical of young age (0-30 years), without sex predilection. They account for up to two-thirds of all such tumors, followed by ameloblastomas [6, 7]. In many cases, if the tumor is associated with an unerupted tooth, whose eruption path is obstructed, the tooth tends to erupt spontaneously after having enucleated the lesion, regardless of the degree of root formation [7].

The aim of the present article is to report on the management of a complex case of Odontoma, associated with impacted first molar and inferior alveolar nerve involvement.

Case Presentation

A 12-year-old Chinese patient came to our hospital in February 2014, referring to the appearance of swelling, charged to the posterior side of

*Correspondence to: Christian Bacci, Via Giustiniani, 1, Section Clinical Dentistry, Department of Neurosciences, University of Padova, 35128 Padova, Italy; E-mail: christian.bacci@unipd.it

the left mandible. The medical history didn't record any disease or drug intake. The intraoral examination showed the presence of a painful unresectable lesion, on the buccal side of the left mandible and the absence of the first and second left molars (unlike the contralateral counterparts, which were erupted into their normal functioning position). The mucosa was reddened, hypertrophic and painful. Oral hygiene was poor, with the presence of plaque and calculus.

A radiograph was taken (Figure 1). The orthopantomography shows the presence of a wide radiodense lesion with a lucent rim, in which various components could be distinguished. A tooth, probably the first permanent inferior molar, surrounded by a radiolucent lesion, could be identified mesially to the lesion and apically to the lower second premolar.

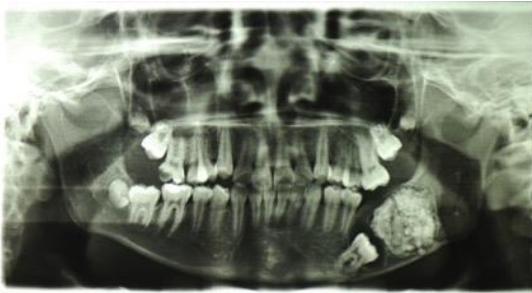

Figure 1

The radiological findings, which identified irregular masses of calcified materials, and the absence of the second permanent mandibular molar, suggested that the lesion could consist of a complex odontoma. The patient and her parents manifested their intention to go back to China to undergo surgery. The patient came back to Italy for a visit in March 2014, showing the postoperative radiograph (Figure 2) and the results of the histological examination, that confirmed the diagnosis of odontoma.

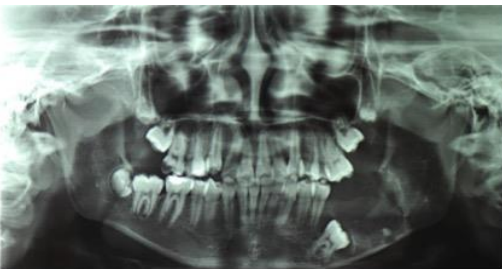


Figure 2

In July 2014, four months after surgery, the patient was radiographed again (Figure 3).

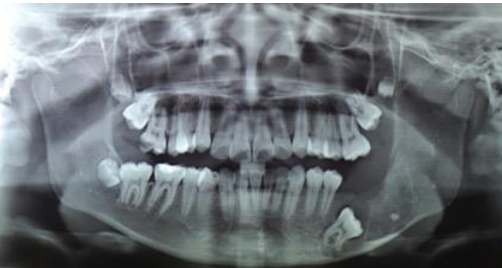


Figure 3

The orthopantomography showed the post-surgical site in a phase of healing and ossification, but the inferior first molar was still impacted in the initial position. The radiolucent lesion surrounding the crown of the impacted tooth, on the contrary, had increased in size. The radiological appearance of a circumscribed pericoronal radiolucency was compatible with the prospect of a dentigerous cyst, an epithelial-lined pathologic cavity that develops in association with the crown of an unerupted tooth [8]. The patient reported a mild anaesthesia, charged to the chin and the lower left lip. The patient was subjected to another surgery to extract the impacted tooth and to enucleate the lesion. A Computer Tomography (Figures 4 & 5) was taken in December 2014, in order to evaluate the relationship between the impacted tooth and the mandibular canal and the mental foramen. The radiological exam showed that the roots of the impacted inferior first molar surrounded the mandibular canal (Figures 4 & 5).

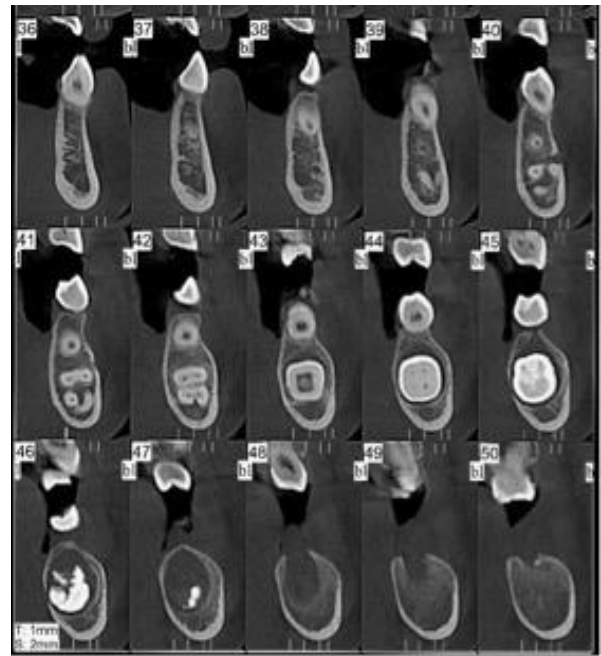


Figure 4

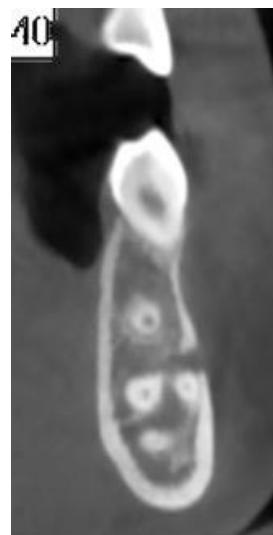

Figure 5

The patient underwent surgery in June 2015, after anesthesiologic evaluation.

Both the parents gave their informed consent to the conscious sedation, in order to avoid general anesthesia, and to the surgical procedure [9, 10]. The extraction was performed under local anesthesia: inferior alveolar nerve block and lingual nerve block using mepivacaine chlorhydrate without vasoconstrictor, infiltration of buccal nerve with mepivacaine 2% with epinephrine (5.6ml) and postsurgical infiltration with bupivacaine 0.5% without vasoconstrictor (2ml). A thin layer of EMLA cream (lidocaine 2.5% and prilocaine 2.5%) was applied before the injection on the oral mucosa in order to prevent pain, which might be caused by the injections.

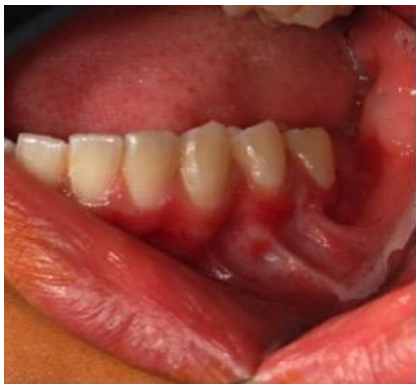

Figure 6

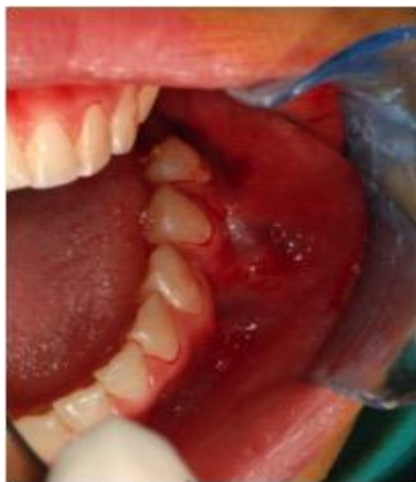

Figure 7

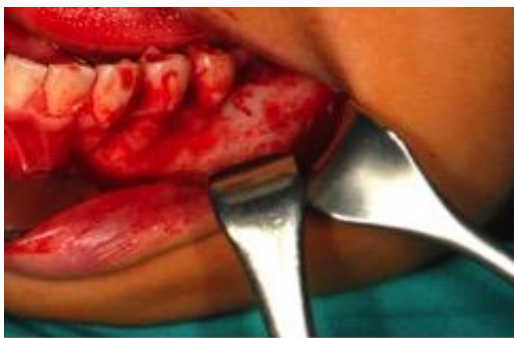

Figure 8

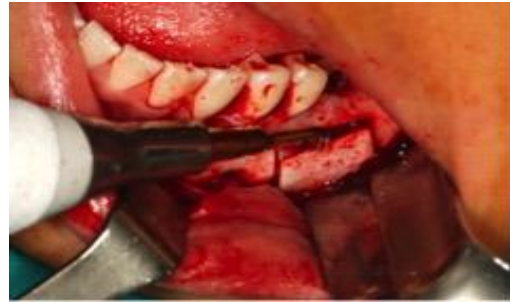

Figure 9

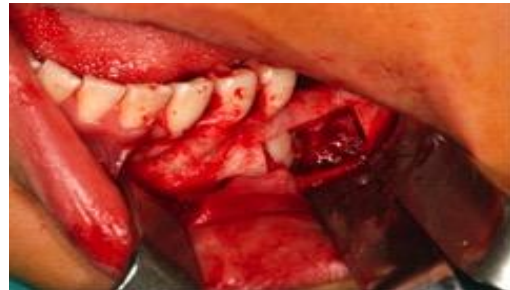

Figure 10

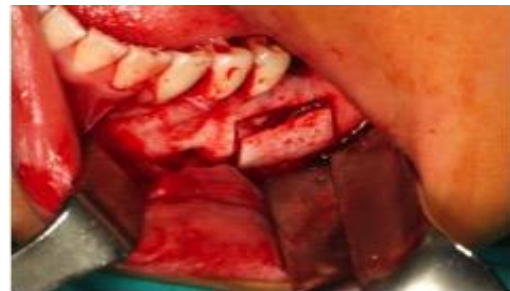

Figure 11

Full-thickness intrasulcular triangular flap was performed (Figure 8), from the mesial side of the lower canine to the distal side of the lower second premolar, with a disto-vestibular and a mesio-vestibular release cut. This procedure offered the maximum visibility and didn't harm neighboring teeth, nor the mental and the lingual nerves.

After the elevation of the flap, the oral surgeon performed a bony window (15 × 10 mm) using a piezoelectric device (Figures 9-11) irrigated with saline solution, to guarantee the most atraumatic detachment of the vestibular cortical of the mandible [11, 12].

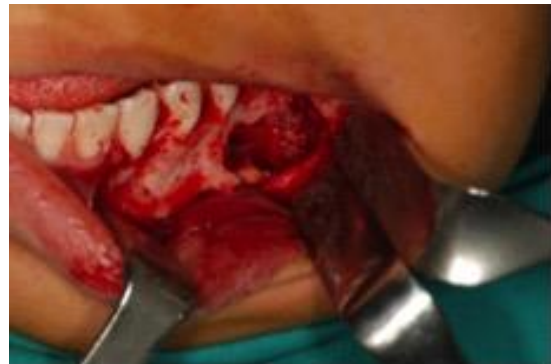

Figure 12

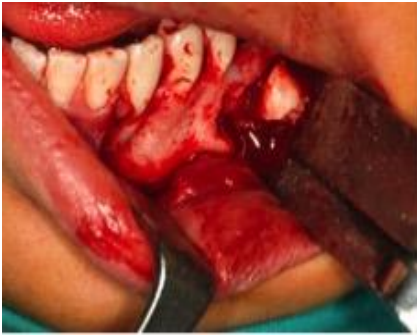

Figure 13

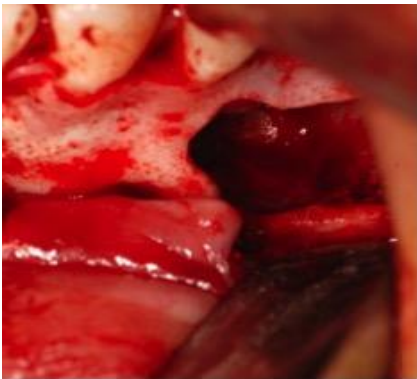

Figure 14

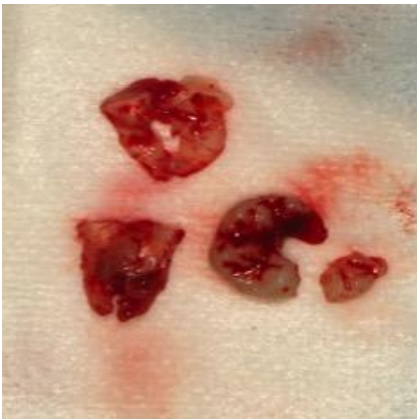

Figure 15

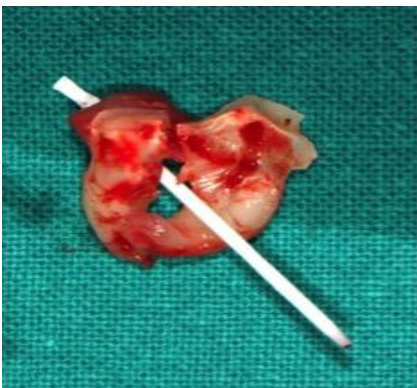

Figure 16

The tooth was sectioned and extracted in pieces (Figures 12-16), together with the lesion, sent for the histological examination.

The inferior alveolar nerve is visible and uninjured on the bottom side of the post-extraction site and the mental nerve wasn't damaged (Figures 17 & 18).

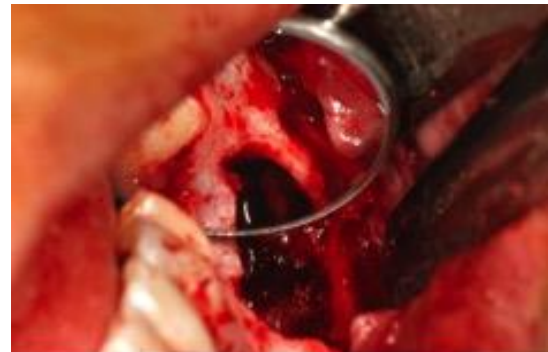

Figure 17

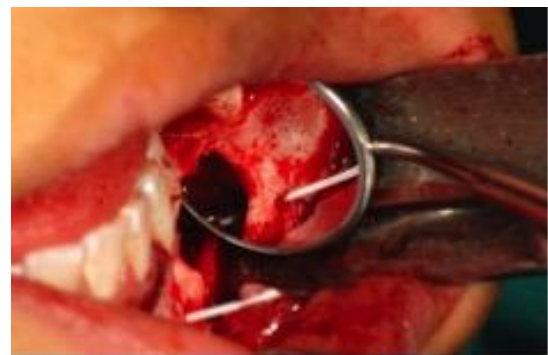

Figure 18

The bony window was repositioned and fixed by osteosynthesis screws (Figure 19), and the flap was sutured using a mid-term absorbable synthetic suture.

The total duration of the surgery was 1 hour and 30 minutes. 8mg of Betamethasone was administered immediately after surgery. A postoperative orthopantomography was taken (Figure 20).

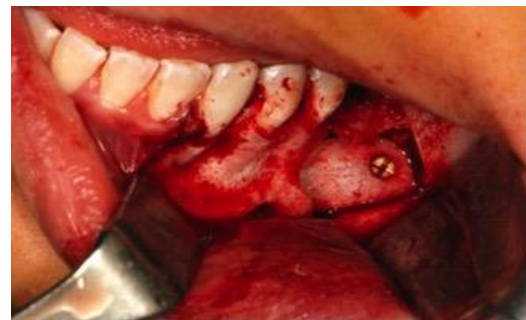

Figure 19

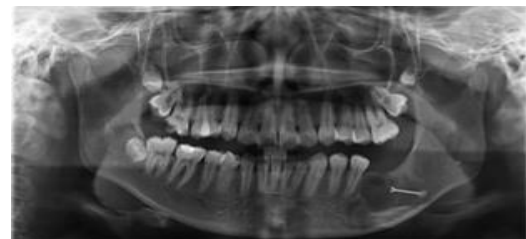


Figure 20

The following medications were used: Amoxicillin (2g 1 hour before surgery and 1g every 12 hours for the six days following the surgery) and Acetaminophen 600mg as a painkiller, if necessary. Postoperative instructions were given to the patient and her parents and a soft diet was recommended in order to avoid complications, such as mandibular fracture.

A control visit was performed one week after surgery. The intraoral examination showed a mucosa in the phase of healing (Figure 21). Although the suture was resorbable, it was removed two weeks after surgery. The results of the histological examination reported the final diagnosis of odontogenic cyst, with a disepithelization of the epithelium and chronic inflammation (compatible with follicular cyst).

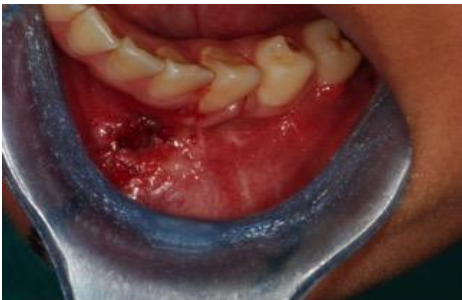

Figure 21

The patient reported paresthesia charged to the innervation area of the mental nerve (Figures 22-24). Another orthopantomography was taken in December 2015, showing a quite complete ossification (Figure 25).

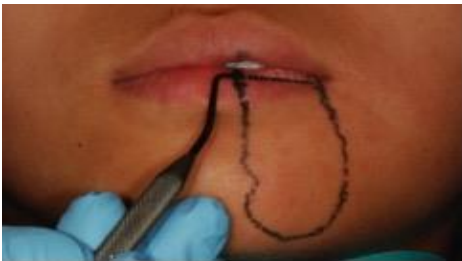

Figure 22

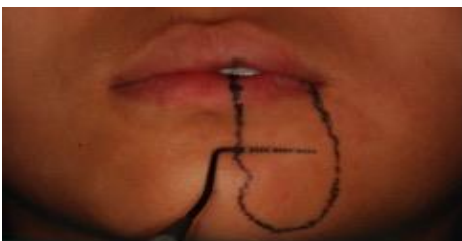

Figure 23

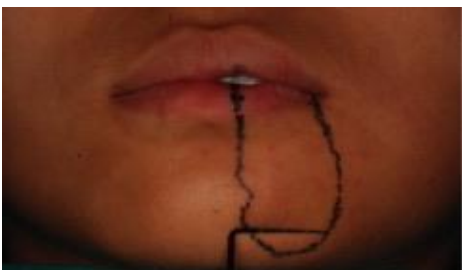

Figure 24

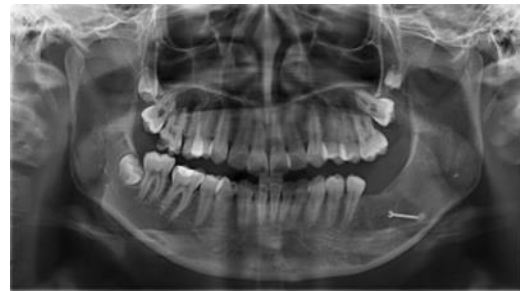


Figure 25

Discussion

The aim of the present article is to report on the management of a complex case of odontoma, associated with impacted first molar and inferior alveolar nerve involvement. The diagnosis of odontoma is quite simple, even with orthopantomography, considering the predilection for this lesion to occur in the posterior mandible [7, 13]. Unerupted teeth are associated with complex odontomas from 10.0% to 44.4% of the cases [14, 15]. Conservative surgical resection is the treatment of choice for this kind of lesions [13].

According to Manani *et al.*, we decided to perform the surgery with the use of conscious sedation in order to avoid the risks related to general anesthesia [10]. The patient had reported no anxiety or agitation, and the use of benzodiazepines produced slight amnesia.

The surgical procedure, like almost all dental procedures, implies various risks and benefits. According to Greenstein *et al.*, the most frequent position (63%) of the mental foramen is on the buccal side of the mandible body, in line with the longitudinal axis of the second premolars or between apices of premolars, but multiple mental foramina are observed in 17% of the cases [16]. We decided to perform a full-thickness intrasulcular triangular flap, from the mesial side of the lower canine to the distal side of the lower second premolar.

Both the extraction of the molar and the enucleation of the cyst could increase the risk of pathological mandibular fracture, but appropriate recommendations have proven to be enough to avoid such complications [17]. Another possible risk includes inferior alveolar nerve damage during the tooth extraction and the cyst enucleation, so the young patient and her parent have been adequately informed. In order to reduce this risk, a piezoelectric device was used. It allowed a minimally invasive approach, and only bone substance was resected with high precision thanks to ultrasounds, whereas the surrounding soft tissues remained uninjured.

Conclusion

The use of conscious sedation, together with a minimally invasive surgical approach, have proved to be effective for the management of young patients affected by wide oral lesions. No postoperative complications, such as mandibular fracture and bleeding, have occurred. A mild anesthesia charged to the mental nerve's innervation area was recorded, but it was already present after the first surgery.

Conflicts of Interest

None.

REFERENCES

1. Thilander B, Myrberg N (1973) The prevalence of malocclusion in Swedish schoolchildren. *Scand J Dent Res* 81: 12-21. [[Crossref](#)]
2. Dachi SF, Howell FV (1961) A survey of 3,874 routine full-mouth radiographs: II. A study of impacted teeth. *Oral Surg Oral Med Oral Pathol* 14: 1165- 1169. [[Crossref](#)]
3. Raghoebar GM, Boering G, Vissink A, Stegenga B (1991) Eruption disturbances of permanent molars: a review. *J Oral Pathol Med* 20: 159-166. [[Crossref](#)]
4. Cho SY, Ki Y, Chu V, Chan J (2008) Impaction of permanent mandibular second molars in ethnic chinese schoolchildren. *J Can Dent Assoc* 74: 521. [[Crossref](#)]
5. Proffit WR (1993) Early stages of development. Contemporary orthodontics, 2nd ed. St. Louis: Mosby Yearbook Inc 1993: 56-86.
6. Kramer IR, Pindborg JJ, Shear M (1992) The WHO Histological Typing of Odontogenic Tumours. A commentary on the Second Edition. *Cancer* 70: 2988-2994. [[Crossref](#)]
7. Hisatomi M, Asaumi J, Konouchi H, Honda Y, Wakasa T et al. (2002) A case of complex odontoma associated with an impacted lower deciduous second molar and analysis of the 107 odontomas. *Oral Diseases* 8: 100-105. [[Crossref](#)]
8. Ko KS, Dover DG, Jordan RC (1999) Bilateral dentigerous cysts-report of an unusual case and review of the literature. *J Can Dent Assoc* 65: 49-51. [[Crossref](#)]
9. Facco E, Stellini E, Bacci C, Manani G, Pavan C et al. (2013) Validation of visual analogue scale for anxiety (VAS-A) in preanesthesia evaluation. *Minerva Anestesiol* 79: 1388-1395. [[Crossref](#)]
10. Manani G, Bacci C, Zanette G, Facco E (2012) Contemporary state of sedation in dentistry [Stato attuale della sedazione cosciente in odontoiatria]. *Dental Cadmos* 80: 357-369.
11. Sivoletta S, Brunello G, Berengo M, De Biagi M, Bacci C (2015) Rehabilitation With Implants After Bone Lid Surgery in the Posterior Mandible. *J Oral Maxillofac Surg* 73: 1485-1492. [[Crossref](#)]
12. Bacci C, Sivoletta S, Brunello G, Stellini E (2014) Maxillary sinus bone lid with pedicled bone flap for foreign body removal: the piezoelectric device. *Br J Oral Maxillofac Surg* 52: 987-989. [[Crossref](#)]
13. Philipsen HP, Reichart PA, Praetorius F (1997) Mixed odontogenic tumours and odontomas. Considerations on interrelationship. Review of the literature and presentation of 134 new cases of odontomas. *Oral Oncol* 33: 86-99. [[Crossref](#)]
14. Or S, Yiicetas S (1987) Compound and complex odontomas. *Int J Oral Maxillofac Surg* 16: 596-599. [[Crossref](#)]
15. Morning P (1980) Impacted teeth in relation to odontomas. *Int J Oral Surg* 9: 81-91. [[Crossref](#)]
16. Greenstein G, Tarnow D (2006) The mental foramen and nerve: clinical and anatomical factors related to dental implant placement: a literature review. *J Periodontol* 77: 1933-1943. [[Crossref](#)]
17. Daley TD, Wysocki GP (1995) The small dentigerous cyst. A diagnostic dilemma. *Oral Surg Oral Med Oral Pathol Oral Radiol Endod* 79: 77-81. [[Crossref](#)]