

Janssen-Sponsored Satellite Symposium at the 37<sup>th</sup> ECTRIMS 2021

## **The future is today: Reflecting on an optimized patient journey based on clinical scenarios**

This virtual satellite symposium focused on how to personalise treatment using prognostic profiling in multiple sclerosis (MS). It explored the evolving world of MS treatment through the use of dynamic patient cases and discussed the latest in prognostic biomarkers and cognitive testing, how COVID-19 vaccines fit into patients' priorities and how to account for patients' future family plans.

**The symposium report  
has now been published in  
*Key Opinions in Medicine***



*Access the publication*

**KO** Key Opinions in Medicine  
Neurology

**janssen**  **Neuroscience**

PHARMACEUTICAL COMPANIES OF 

**WILEY**

CP-280719

Date of preparation: December 2021

## CASE REPORT

# First-line steroid treatment for spontaneous intracranial hypotension

Simone Tonello<sup>1</sup> | Ugo Grossi<sup>2,3</sup>  | Elena Trincia<sup>4</sup> | Giacomo Zanus<sup>2,3</sup>

<sup>1</sup>Neurology Unit, Regional Hospital Treviso, Treviso, Italy

<sup>2</sup>II Surgery Unit, Regional Hospital Treviso, Treviso, Italy

<sup>3</sup>Department of Surgery, Oncology and Gastroenterology - DISCOG, University of Padua, Padova, Italy

<sup>4</sup>Neuroradiology Unit, Regional Hospital Treviso, Treviso, Italy

**Correspondence**

Ugo Grossi, II Surgery Unit, Regional Hospital Treviso, Piazzale dell'Ospedale 1, 31100 Treviso, Italy.  
Email: ugo.grossi@aulss2.veneto.it

**Funding information**

None

**Abstract**

**Background:** Spontaneous intracranial hypotension (SIH) is a syndrome characterized by low cerebrospinal fluid (CSF) pressure and postural headaches, and affects 1 per 20,000 individuals every year.

**Case report:** We report an otherwise healthy 38-year-old man admitted to the hospital with orthostatic headache that developed 48 h after a short-haul flight during which he sustained a neck injury due to turbulence. Neurological examination, blood analysis and computed tomography scan performed at the emergency service were normal. Brain and spine magnetic resonance imaging (MRI) showed diffuse pachymeningeal enhancement and contrast medium egress from the subarachnoid space into the epidural space at the level of C2. The patient was treated with bed rest, hydration and 1 mg/kg/day oral prednisone for 5 days, with a gradual withdrawal in the following 7 days. Complete symptomatic relief was observed after 16 days, with resolution of the pathological findings on brain and spinal MRI after 1 month, except for localized pachymeningeal enhancement. Clinical relief was maintained over time until last follow-up visit 9 months later.

**Conclusion:** Successful conservative treatment barely exceeds one quarter of cases of SIH. The clinical benefits of steroids may result from several mechanisms of action, for example, improving brain oedema and inflammation, determining fluid retention, and facilitating reabsorption of the CSF from extradural space. Notwithstanding that epidural blood patch remains the most successful treatment for SIH, future studies should explore the effectiveness of steroids as first-line therapy in addition to the most commonly suggested measures of bed rest and hydration.

**KEYWORDS**

blood patch, spontaneous intracranial hypotension (SIH), steroids

**INTRODUCTION**

Spontaneous intracranial hypotension (SIH) is a syndrome characterized by low cerebrospinal fluid (CSF) pressure and debilitating postural

headaches. The diagnostic criteria recommended by the Headache Classification Committee of the International Headache Society have changed significantly throughout the last few decades, explaining current uncertainty on how to reliably diagnose and treat this condition [1].

This is an open access article under the terms of the Creative Commons Attribution-NonCommercial License, which permits use, distribution and reproduction in any medium, provided the original work is properly cited and is not used for commercial purposes.

© 2021 The Authors. *European Journal of Neurology* published by John Wiley & Sons Ltd on behalf of European Academy of Neurology.



## CASE REPORT

A 38-year-old male presented with orthostatic headache that developed 48 h after a short-haul flight during which he sustained a neck injury due to turbulence. He complained of severe headache, nausea and photophobia, exacerbated by an upright position and relieved on lying down. No comorbidities were reported. The patient had a non-complicated COVID-19 infection 10 months before hospital admission. Neurological examination, blood analysis and computed tomography scan performed at the emergency department were normal. Brain and spine magnetic resonance imaging (MRI) after intravenous gadolinium administration showed diffuse pachymeningeal enhancement and contrast medium egress from the subarachnoid space into the epidural space at the level of C2 (Figure 1). The patient was treated with bed rest, hydration and 1 mg/kg/day oral prednisone for 5 days, with a gradual withdrawal in the following 7 days. Complete symptomatic relief was observed after 16 days, with resolution of the pathological findings on brain and spinal MRI after 1 month, except for localized pachymeningeal enhancement. Clinical relief has been maintained over time until the last follow-up visit 9 months later.

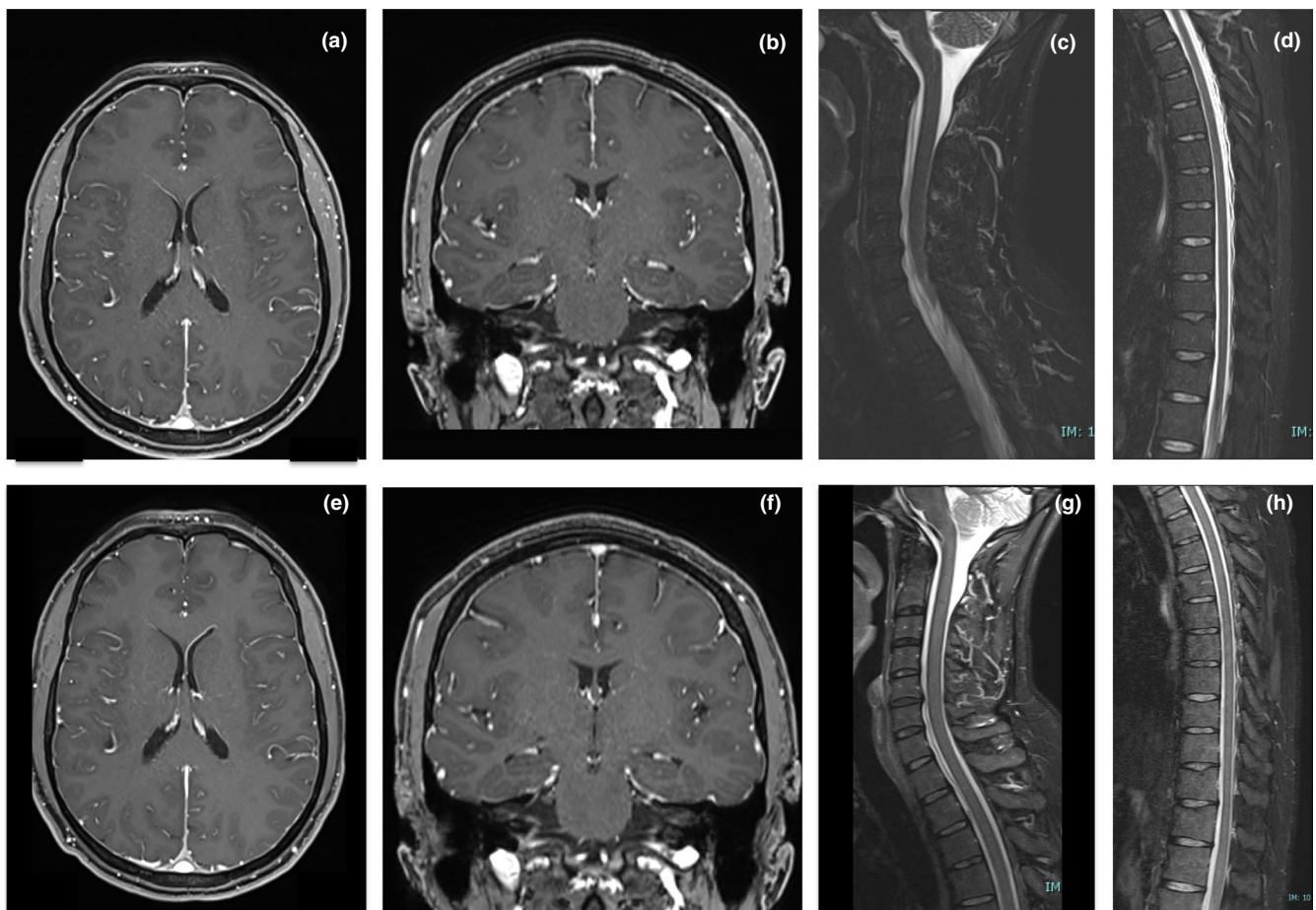
## Ethics approval

Written informed consent in respect of this case report was obtained in accordance with the Declaration of Helsinki. No ethics board approval was required for this case report.

## DISCUSSION

Spontaneous intracranial hypotension affects 1 per 20,000 individuals every year, and is diagnosed when headache has developed spontaneously and in temporal relation to a CSF leak demonstrated on imaging and/or lumbar puncture (opening pressure <60 mm H<sub>2</sub>O) [1].

Schievink et al. [2] reviewed the patho-aetiology of SIH in a large series of 568 consecutive patients, identifying three main types: the dural tear, the meningeal diverticulum and the CSF-venous fistula, which may or not be associated with extradural CSF collection. None of the patients exhibited coexistence of ventral and dorsal tears as observed in the present case.



**FIGURE 1** Magnetic resonance imaging (MRI) showing supratentorial and infratentorial diffuse pachymeningeal enhancement; T1-weighted axial (a) and coronal (b) images. Spinal STIR images showing small cerebrospinal fluid leaks in the extradural space, both in the ventral cervical spine (c) and dorsal thoracic spine (d). MRI at 1-month follow-up showing reduced pachymeningeal enhancement (e and f) and no evidence of extradural fluid collection (g and h) [Colour figure can be viewed at [wileyonlinelibrary.com](http://wileyonlinelibrary.com)]

In a recent systematic review and meta-analysis of 144 articles, D'Antona et al. [1] provided a summary of the evidence on SIH. Based on their findings, successful conservative treatment was reported in only 28% of cases. This mainly consisted of bed rest and hydration in 88% and 83% of included patients, respectively. The impact of other types of conservative treatment on the success rate was in fact notably lower, thereby potentially underestimating the overall effectiveness. As a result of the arbitrary cut-off of at least 10 patients for study eligibility, the use of steroids, for instance, accounted for only 4% ( $N = 30/748$ ) of patients treated conservatively. This pragmatic threshold excluded several case reports and small case series reporting early clinical improvement of SIH after administration of steroids [3–5].

The clinical benefits of steroids may result from several mechanisms of action. These include: (a) improving brain oedema and inflammation consequent to sagging of the brain and cranial nerves; (b) determining fluid retention, decreasing vascular leakage or inflammatory response to the presence of proteins or cells in the CSF; (c) avoiding CSF hyperabsorption; (d) and facilitating reabsorption of the CSF from extradural space, thus increasing its volume.

There is large heterogeneity in the type (prednisone, methylprednisolone, fludrocortisone or dexamethasone), direction (intramuscular, oral or intravenous) and dose of steroids used in previous reports, with treatment period ranging from days to several weeks. Adverse effects are both dose- and time-dependent. Ecchymosis, cushingoid features, parchment-like skin, leg oedema, and sleep disturbance typically follow a linear dose–response pattern [6]. An elevated frequency of other events (e.g., weight gain, epistaxis, glaucoma, depression and hypertension) occurs instead beyond a specific threshold dose.

Coexistence of ventral and dorsal tears may occur in the same patient. Similar to previous reports, our experience suggests that steroids may be used as first-line therapy for SIH in addition to the most commonly suggested measures of bed rest and hydration. According to published evidence, epidural blood patches remain the most successful treatment of SIH. Prospective, randomized studies are needed to establish the safety and effectiveness of steroids to avoid the need for more invasive treatments.

#### ACKNOWLEDGMENTS

Open Access Funding provided by Università degli Studi di Padova within the CRUI-CARE Agreement.

#### CONFLICT OF INTEREST

None.

#### AUTHOR CONTRIBUTIONS

**Simone Tonello:** Conceptualization (equal); Data curation (equal); Formal analysis (equal); Investigation (equal); Methodology (equal); Writing – original draft (equal); Writing – review and editing (equal). **Ugo Grossi:** Conceptualization (equal); Formal analysis (equal); Methodology (equal); Writing – original draft (equal); Writing – review and editing (equal). **Elena Trincia:** Data curation (equal); Formal analysis (equal); Methodology (equal); Supervision (equal); Writing – review and editing (equal). **Giacomo Zanusi:** Conceptualization (equal); Supervision (equal); Writing – review and editing (equal).

#### DATA AVAILABILITY STATEMENT

The data that support the findings of this study are available from the corresponding author upon reasonable request.

#### ORCID

Ugo Grossi  <https://orcid.org/0000-0001-5372-2873>

#### REFERENCES

1. D'Antona L, Jaime Merchan MA, Vassiliou A, et al. Clinical presentation, investigation findings, and treatment outcomes of spontaneous intracranial hypotension syndrome. A systematic review and meta-analysis. *JAMA Neurol.* 2021;78(3):329.
2. Schievink WI, Maya MM, Jean-Pierre S, Nuno M, Prasad RS, Moser FG. A classification system of spontaneous spinal CSF leaks. *Neurology.* 2016;87(7):673–679.
3. Ozyigit A, Michaelides C, Natsiopoulos K. Spontaneous intracranial hypotension presenting with frontotemporal dementia: a case report. *Front Neurol.* 2018;9:673.
4. Goto S, Ohshima T, Yamamoto T, Shimato S, Nishizawa T, Kato K. Successful steroid treatment of coma induced by severe spontaneous intracranial hypotension. *Nagoya J Med Sci.* 2016;78(2):229–236.
5. Russo C, Buono V, Fenza G, Zandolino A, Serino A, Manto A. Spontaneous intracranial hypotension: two steroid-responsive cases. *Pol J Radiol.* 2018;83:e229–e233.
6. Yasir M, Goyal A, Bansal P, Sonthalia S. *Corticosteroid adverse effects.* Statpearls; 2021.

**How to cite this article:** Tonello S, Grossi U, Trincia E, Zanusi G. First-line steroid treatment for spontaneous intracranial hypotension. *Eur J Neurol.* 2022;29:947–949. doi:[10.1111/ene.15195](https://doi.org/10.1111/ene.15195)



# MANAGE-PD

Tool for Making Informed Decisions to  
Aid Timely Management of Parkinson's Disease



**MANAGE-PD** allows you to:

- Identify PD patients inadequately controlled on oral medications
- Determine which patients with PD may be adequately controlled on their current treatment regimen or may require changes to their treatment regimen



Scan the QR code to  
access to the web

Click here to  
access to the web



MANAGE-PD is an AbbVie Inc. registered Medical Device. It is a collaborative research and development effort between AbbVie Medical Affairs and Health Economics and Outcomes, the Parkinson's Foundation and an international panel of Movement Disorder Specialists.

©2022 AbbVie Inc. All rights reserved. The Parkinson's Foundation logo is the sole property of the Parkinson's Foundation used with written permission. Any use of the Parkinson's Foundation name or logo without Foundation permission is prohibited. All content in <https://www.managepd.eu/> is intended only for informational use by healthcare professionals and is not offered as or intended to be medical advice for any particular patient. This information is not intended for patients. Only a healthcare professional exercising independent clinical judgement can make decisions regarding appropriate patient care and treatment options considering the unique characteristics of each patient.

PD: Parkinson's Disease