




STANDARD ARTICLE

Echocardiographic evaluation of the right ventricular dimension and systolic function in dogs with pulmonary hypertension

Tommaso Vezzosi¹  | Oriol Domenech² | Giulia Costa¹ | Federica Marchesotti²  |
Luigi Venco⁵ | Eric Zini^{2,3,4}  | Maria Josefa Fernández del Palacio⁶ | Rosalba Tognetti¹

¹Department of Veterinary Sciences,
University of Pisa, Pisa, Italy

²Istituto Veterinario di Novara, Novara, Italy

³Clinic for Small Animal Internal Medicine,
Vetsuisse Faculty, University of Zurich, Zurich,
Switzerland

⁴Department of Animal Medicine, Production
and Health, University of Padova, Padova, Italy

⁵Veterinary Hospital Città di Pavia, Pavia, Italy

⁶Veterinary Teaching Hospital, Department of
Animal Medicine and Surgery, Murcia, Spain

Correspondence

Tommaso Vezzosi, Department of Veterinary
Sciences, University of Pisa, via Livornese lato
monte, 56122 San Piero a Grado, Pisa, Italy.
Email: tommaso.vezzosi86@gmail.com

Funding information

University of Pisa

Background: Right ventricular (RV) enlargement and dysfunction are associated with prognosis in humans with pulmonary hypertension (PH).

Hypothesis/Objectives: To assess RV size and systolic function in dogs with PH and to determine if they are associated with disease severity and right-sided congestive heart failure (R-CHF).

Animals: 89 dogs with PH and 74 healthy dogs.

Methods: Prospective observational study. PH was classified according to the tricuspid regurgitation pressure gradient. RV end-diastolic area (RVEDA) index was calculated as RVEDA divided by body surface area. RV systolic function was assessed with the tricuspid annular plane systolic excursion (TAPSE) and the RV fractional area change (FAC) normalized for body weight (TAPSEn and FACn, respectively).

Results: RVEDA index was higher in dogs with moderate PH (10.8 cm²/m²; range, 6.2-14.4 cm²/m²) and severe PH (12.4 cm²/m²; range, 7.7-21.4 cm²/m²) than in those with mild PH (8.4 cm²/m²; range, 4.8-11.6 cm²/m²) and control dogs (8.5 cm²/m²; range, 2.8-11.6 cm²/m²; $P < .001$). RVEDA index was significantly higher in dogs with R-CHF (13.7 cm²/m²; range, 11.0-21.4 cm²/m²) than in dogs without R-CHF (9.4 cm²/m²; range, 4.8-17.1 cm²/m²; $P < .001$). The severity of tricuspid regurgitation (TR) was the only independent predictor of the RVEDA index ($P < .001$). TAPSEn and FACn were not significantly different among varying degrees of PH severity and between dogs with and without R-CHF.

Conclusions and Clinical Importance: The RVEDA index can be used to evaluate RV size in dogs. It can provide additional information in dogs with PH and predict R-CHF. Severity of TR is the main determinant of RV enlargement in dogs with PH.

KEYWORDS

congestive heart failure, right ventricular enlargement, right ventricular size, tricuspid regurgitation

Abbreviations: 2D, two-dimensional; 3D, three-dimensional; BSA, body surface area; BW, body weight; FAC, fractional area change; FACn, fractional area change normalized for body weight; PH, pulmonary hypertension; RV, right ventricle; RVEDA, right ventricular end-diastolic area; R-CHF, right-sided congestive heart failure; TAPSE, tricuspid annular plane systolic excursion; TAPSEn, tricuspid annular plane systolic excursion normalized for body weight; TR, tricuspid regurgitation; TRPG, tricuspid regurgitation pressure gradient.

This is an open access article under the terms of the Creative Commons Attribution-NonCommercial License, which permits use, distribution and reproduction in any medium, provided the original work is properly cited and is not used for commercial purposes. © 2018 The Authors. Journal of Veterinary Internal Medicine published by Wiley Periodicals, Inc. on behalf of the American College of Veterinary Internal Medicine.

1 | INTRODUCTION

Pulmonary hypertension (PH) in dogs is associated with various conditions, including idiopathic pulmonary arterial hypertension, pulmonary diseases, heartworm disease, thromboembolic diseases, and congenital or acquired cardiac diseases.¹ Chronic PH can lead to changes of the

right heart, including right ventricular (RV) hypertrophy, dilatation, and RV dysfunction, and can lead to right-sided congestive heart failure (R-CHF).^{2,3} RV enlargement and systolic dysfunction are associated with poor prognosis in humans.⁴⁻⁹

Transthoracic echocardiography is the main non-invasive method for diagnosing PH both in humans and in dogs.^{1,10} In humans, RV size and function are quantitatively assessed mainly using M-mode, 2-dimensional (2D), 3-dimensional (3D), and Doppler echocardiography.¹¹⁻¹³ 3D echocardiography is superior to 2D echocardiography to evaluate RV size, however it is time-consuming, not readily available, and the equipment is expensive. Thus, in clinical practice, 2D evaluation of linear and area dimensions of the RV are the most commonly used variables to assess RV size.¹¹⁻¹⁷

3D echocardiography is also the gold standard non-invasive tool for assessing systolic function. However, the tricuspid annular plane systolic excursion (TAPSE) and the fractional area change (FAC) are commonly used variables of RV systolic function in clinical practice.^{11,12,18,19}

In dogs with PH, RV size and function are typically assessed by subjective assessment or M-mode evaluation.²⁰⁻²⁴ However, in humans, 2D echocardiography is more accurate than M-mode for evaluating RV size and function, and the subjective approach is relatively inaccurate.^{11-14,25} Reference ranges for the quantitative assessment (M-mode and 2D) of RV size and function in healthy dogs have recently been proposed, and weight-specific reference intervals provided.^{16,26}

The aim of this study was to evaluate the RV end-diastolic area (RVEDA) as a 2-dimensional indicator of RV size, and TAPSE and FAC, as indicators of RV systolic function in dogs with PH. Our hypothesis was that RV size increases with both the severity of PH and tricuspid regurgitation (TR), and that RV size is a predictor of R-CHF. In addition, we hypothesized that RV systolic function decreases with the severity of PH.

2 | MATERIALS AND METHODS

The investigation was prospective, multicenter, and observational. Dogs were recruited at the Department of Veterinary Sciences of the University of Pisa, at the Istituto Veterinario di Novara, at the Veterinary Hospital Città di Pavia, and at the Department of Animal Medicine and Surgery of the University of Murcia. The study protocol was reviewed and approved by the Institutional Welfare and Ethics Committee of the University of Pisa (permission number 38/2015).

2.1 | Animals

Over a 2-year period, client-owned dogs affected by PH or clinically healthy were prospectively included in the study. Dogs were clinically healthy based on the absence of complaints and unremarkable physical, cardiovascular assessment and transthoracic echocardiogram. Dogs were deemed to have PH if during echocardiography a tricuspid regurgitation pressure gradient (TRPG) ≥ 36 mm Hg was identified.^{21,23,27} The TR jet velocity was measured by continuous-wave Doppler from the view that lead to the best alignment with the

direction of the jet. The TRPG was derived from the peak systolic tricuspid regurgitation jet velocity via the simplified Bernoulli equation ($PG = 4 \times \text{velocity}^2$).

Dogs with PH were divided into 3 groups: mild PH if TRPG was 36-50 mm Hg, moderate PH if TRPG was 51-75 mm Hg, and severe PH if TRPG was >75 mm Hg.^{21,23,27} Dogs with PH were divided into 2 subgroups, namely precapillary and postcapillary, according to history, physical examination, complete blood count, biochemical profile, urinalysis, heartworm test, thoracic radiography, echocardiography, abdominal ultrasound and, if necessary, computed tomography, bronchoscopy and bronchoalveolar lavage, as previously described.^{1,28} If presenting with pulmonary arterial hypertension (heartworm disease, congenital systemic-to-pulmonary shunts, idiopathic), pulmonary disease or hypoxia (chronic obstructive pulmonary disease, interstitial pulmonary fibrosis, neoplasia, high-altitude disease, reactive pulmonary artery vasoconstriction), pulmonary thrombotic and/or embolic disease, compressive mass lesions (neoplasia, granuloma), without signs of left-sided congestive heart failure, dogs were assigned to the precapillary group. If presenting with severe left heart disease with signs of increased pulmonary venous pressure and/or left-sided congestive heart failure, dogs were assigned to the postcapillary group.¹

The presence of R-CHF was based on the presence of ascites associated with jugular venous distension, hepatomegaly, and a subjectively dilated caudal vena cava.

Exclusion criteria for this study were the identification of a congenital heart disease, acquired cardiomyopathies, pericardial disease, severe pleural effusion, atrial fibrillation, and breeds typically prone to arrhythmogenic right ventricular cardiomyopathy (boxers and bulldogs). In addition, all dogs receiving sildenafil or pimobendan were excluded from the study, due to the potential influence of these drugs on TRPG and RV systolic function.^{29,30}

2.2 | Echocardiographic assessment

All examinations were performed by 4 experienced operators (TV, OD, LV, and JFP). Unsedated dogs were examined in right and left lateral recumbency. Each dog underwent a complete echocardiographic examination, which included transthoracic 2D, M-mode, spectral and color flow Doppler imaging.³¹ In all dogs, the echocardiographic characterization of the RV was obtained from the left apical 4-chamber view optimized for the right heart.^{11,16,26} RVEDA was measured by planimetry at the end of ventricular diastole, tracing from the lateral aspect of the tricuspid annulus to the septal aspect, excluding the area of the annulus and trabecular structures, following the RV endocardium (Figure 1).^{11,13} The RVEDA index was calculated as the ratio of RVEDA and body surface area (BSA).^{13,14} The BSA was calculated as $0.101 \times \text{body weight (kg)}^{2/3}$, as previously described.³² The TAPSE was measured from M-mode recordings of the lateral aspect of the tricuspid valve annulus seen from the left apical 4-chamber view optimized for the right heart.^{11,26}

The fractional area change (FAC) was derived from RV chamber areas using the formula: $FAC = [(RV \text{ diastolic area} - RV \text{ systolic area}) / RV \text{ diastolic area}] \times 100$.^{11,26} Normalized FAC and TAPSE (FACn and TAPSEn) were calculated as the ratio of FAC or TAPSE and body

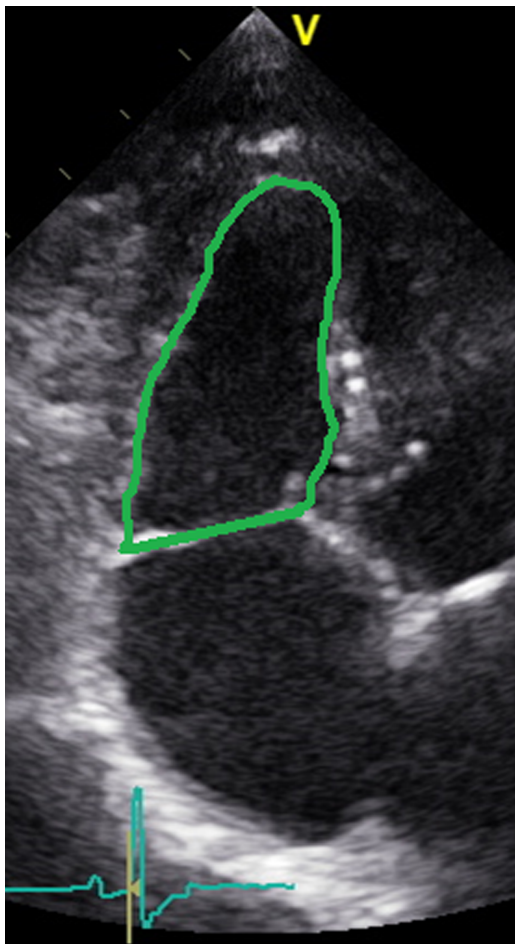


FIGURE 1 Left apical 4-chamber view optimized for the right heart. The right ventricular end-diastolic area (RVEDA) was measured by planimetry at the end of ventricular diastole

weight (BW) using allometric scaling ($TAPSE_n = TAPSE/BW^{0.297}$ and $FAC_n = FAC/BW^{-0.097}$, respectively).²⁶

TR severity was evaluated qualitatively, using color Doppler and continuous wave Doppler of the TR jet. Briefly, TR was considered mild when a small TR jet on the color Doppler and a faint parabolic TR jet signal on the continuous wave Doppler were detected. Moderate TR was considered when an intermediate TR jet on the color Doppler and a dense parabolic TR jet signal on the continuous wave Doppler were present. Severe TR was considered when a very large central jet or eccentric wall impinging jet on the color Doppler and a dense triangular, early peaking TR jet signal on the continuous wave Doppler were present.³³

The echocardiographic images were stored as digital data for later analysis. All measurements were performed offline by the same operator (TV) evaluating 3 cardiac cycles, and the mean values were calculated.

2.3 | Statistical analysis

Statistical analysis was performed with a commercially available statistical software.^a Descriptive statistics were generated. The normality of data distribution was tested using the Shapiro-Wilk test. Parametric

or nonparametric tests were used in accordance with the Gaussian distribution. Linear regression was used to evaluate relationships between RVEDA and BSA. The chi-squared or Fisher's exact tests were used to compare categorical variables. Continuous variables were compared using the unpaired t test or the Mann-Whitney U test, based on data distribution.

Differences in echocardiographic continuous data among PH groups were determined by one-way analysis of variance with subsequent pair-wise comparisons using Tukey's multiple comparison test (for normally distributed data) or by the Kruskal-Wallis test with subsequent pair-wise comparisons using the Dunn test (for nonnormally distributed data). In addition, receiver operating characteristic curve analysis was used to identify the best diagnostic cut-off of the RVEDA index to identify R-CHF, and the optimal combination of sensitivity and specificity was determined using the Youden index.

In dogs with PH, simple (univariate) linear regression analyses were performed to determine the strength of association of selected clinical (age, sex, and heart rate) and echocardiographic indices (TRPG and TR severity) with the RVEDA index. Multiple linear regression analysis was used to identify significant independent predictors of the RVEDA index.

The variables were entered into a multiple linear regression model in a backward stepwise manner if P was $<.2$ based on univariate linear regression analysis.

Finally, to verify the applicability of the RVEDA, TAPSE, and FAC in a clinical setting, intra- and interobserver measurement variability were determined with the coefficient of variation (CV). For the intraobserver variability, 1 operator (TV) calculated RVEDA, TAPSE, and FAC from 6 randomly selected echocardiographic studies on 2 different occasions 30 days apart. The interobserver variability was carried out by 2 operators (TV and OD) measuring the RVEDA, TAPSE, and FAC from 6 randomly selected blinded echocardiographic studies. A value of $P < .05$ was considered statistically significant.

3 | RESULTS

3.1 | Study population

A total of 163 dogs of 22 breeds were included: 89 dogs with PH and 74 healthy dogs (Table 1). Dogs with PH were significantly older than controls ($P < .001$) and had a lower BW ($P < .001$). Regarding sex, no differences were found between dogs with PH and healthy controls ($P = .16$).

In the PH group, 25 dogs had mild PH, 25 had moderate PH, and 39 had severe PH, based on TRPG. R-CHF was present in 22 dogs, 8 with moderate PH and 14 with severe PH. Fifty-eight dogs had precapillary PH (65%) and 31 dogs had postcapillary PH (35%), with all dogs with postcapillary PH affected by myxomatous mitral valve disease. Regarding etiology, dogs with precapillary PH were affected by heartworm disease ($n = 21$), idiopathic PH ($n = 12$), pulmonary fibrosis ($n = 7$), angiostrongylosis ($n = 5$), chronic bronchitis ($n = 5$), heart base tumor ($n = 4$), and chronic pulmonary thromboembolism ($n = 4$). Dogs with precapillary PH had a higher TRPG compared to postcapillary PH ($P < .05$; Table 2).

TABLE 1 Clinical and echocardiographic data of all study dogs (n = 163)

| | Control | Mild PH | Moderate PH | Severe PH |
|--|----------------|---------------------------|--------------------------------|--------------------------------|
| N cases | 74 | 25 | 25 | 39 |
| Sex (male/female) | 33/41 | 15/10 | 17/8 | 18/21 |
| Age (years) | 2.9 (1-13) | 11.5 (2-15) ^a | 11 (2-16) ^a | 12.2 (1-18) ^a |
| BW (kg) | 25.7 (1.8-57) | 12.6 (5-41.2) | 7.9 (2.7-34) ^a | 10.8 (2.2-40) ^a |
| TRPG (mm Hg) | 0 (0-25) | 44 (37.7-49) ^a | 59.6 (51.8-74) ^{a,b} | 96 (77-149) ^{a,b,c} |
| Severe TR | 0 (0%) | 0 (0%) | 8/25 (32%) ^{a,b} | 20/39 (51%) ^{a,b} |
| RVEDA index (cm ² /m ²) | 8.5 (2.8-11.6) | 8.4 (4.8-11.6) | 10.8 (6.2-17.4) ^{a,b} | 12.4 (7.7-21.4) ^{a,b} |
| TAPSEn | 6.4 (4.8-10.3) | 6.3 (4.9-10.1) | 6.9 (2.3-10.9) | 6.0 (3.1-10.2) |
| FACn | 62 (47.6-82.1) | 61.4 (48.0-99.5) | 67.9 (38.6-93.4) | 62.8 (22.3-95.8) |
| R-CHF | 0 (0%) | 0 (0%) | 8/25 (32%) ^{a,b} | 14/39 (36%) ^{a,b} |

Abbreviations: FACn, fractional area change normalized for body weight; R-CHF, right-sided congestive heart failure; RI, reference interval; RVEDA, right ventricular end-diastolic area; TAPSEn, tricuspid annular plane systolic excursion normalized for body weight; TR, tricuspid regurgitation; TRPG, tricuspid regurgitation systolic pressure gradient.

^a P < .001 compared to control group.

^b P < .001 compared to mild PH group.

^c P < .001 compared to moderate PH group.

Data represent median (min-max) or number (percentage).

3.2 | Right ventricular size

The RVEDA showed a strong positive linear correlation with BSA in healthy dogs ($r = .91$; $r^2 = .86$; $P < .001$). The 95% reference range of the RVEDA index in healthy dogs was 4.9-10.9 cm²/m². No differences in RVEDA index were found between dogs with mild PH and controls ($P = .98$). Conversely, the RVEDA index was significantly higher in dogs with moderate and severe PH compared to dogs with mild PH and healthy controls ($P < .001$; Figure 2). No differences in RVEDA index were found between dogs with moderate and severe PH ($P = .056$). In the univariate analysis, among the clinical and echocardiographic variables, TRPG ($P = .002$) and TR severity ($P < .001$) showed a positive association with the RVEDA index. However, only TR severity maintained a significant ($P < .001$) and independent association with an increased RVEDA index based on multivariate analysis (Table 3).

The RVEDA index was significantly higher in dogs with R-CHF (13.7 cm²/m²; range, 11.0-21.4 cm²/m²) than in dogs without R-CHF (9.4 cm²/m², range: 4.8-17.1 cm²/m²; $P < .001$; Figure 3). The most accurate cut-off value of the RVEDA index in the prediction of R-CHF

TABLE 2 Clinical and echocardiographic data of dogs with precapillary and postcapillary PH

| | Precapillary PH | Postcapillary PH |
|--|------------------|-------------------------------|
| N cases | 58 | 31 |
| TRPG (mmHg) | 79 (38-149) | 60 (37-96) ^a |
| Severe TR | 18 (31%) | 10 (32%) |
| RVEDA index (cm ² /m ²) | 10.7 (4.8-21.4) | 10.6 (6.2-14.8) |
| TAPSEn | 5.8 (2.3-10.1) | 7.9 (3.8-11) ^b |
| FACn | 60.6 (22.3-85.5) | 65.8 (39.1-97.5) ^a |
| R-CHF | 12/58 (21%) | 10/31 (32%) |

Abbreviations: FACn, fractional area change normalized for body weight; R-CHF, right-sided congestive heart failure; RI, reference interval; RVEDA, right ventricular end-diastolic area; TAPSEn, tricuspid annular plane systolic excursion normalized for body weight; TR, tricuspid regurgitation; TRPG, tricuspid regurgitation systolic pressure gradient.

^a P < .05 compared to pre-capillary group.

^b P < .001 compared to pre-capillary group.

Data represent median (min-max) or number (percentage).

was >10.9 cm²/m², with a sensitivity of 100% and a specificity of 73% (Table 4). No differences in the RVEDA index were found between dogs with precapillary and postcapillary PH ($P = .81$).

3.3 | Right ventricular systolic function

The TAPSEn and FACn did not significantly differ among dogs with mild, moderate, and severe PH compared to healthy dogs ($P = .54$ and $P = .67$, respectively). No differences in TAPSEn and FACn were found between dogs with R-CHF and dogs without R-CHF ($P = .32$ and $P = .64$, respectively). TAPSEn and FACn were significantly higher in dogs with postcapillary PH compared to dogs with precapillary PH ($P < .001$ and $P < .05$, respectively) (Table 2). However, even when analyzing dogs with precapillary and postcapillary PH as separate groups, TAPSEn and FACn did not significantly differ among dogs with different levels of PH, nor between dogs with and without R-CHF.

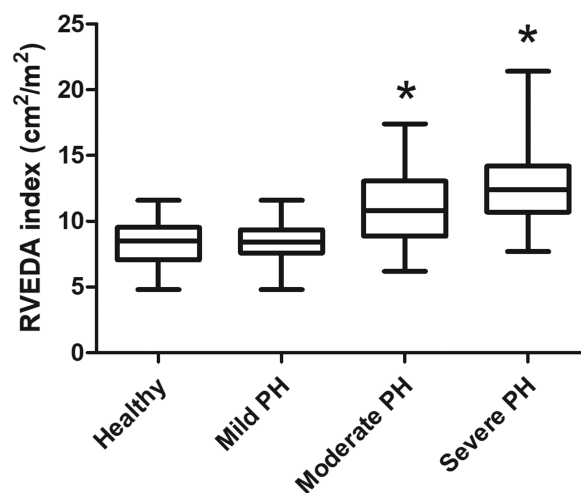


FIGURE 2 Box and whiskers plot for right ventricular end-diastolic area (RVEDA) index in control dogs in comparison to dogs with different degrees of pulmonary hypertension (PH). The RVEDA index was significantly higher in dogs with moderate and severe PH than in dogs with mild PH and the control group (* $P < .001$)

TABLE 3 Multivariate analysis of echocardiographic variables used to predict right ventricular end-diastolic area index in dogs with pulmonary hypertension

| Dependent variable | Independent variables | B coefficient | P value |
|--|-----------------------|---------------|---------|
| RVEDA index (cm ² /m ²) | TRPG | -0.83 | .13 |
| | TR severity | 2.47 | <.001 |

Abbreviations: RVEDA, right ventricular end-diastolic area; TRPG, tricuspid regurgitation systolic pressure gradient; TR, tricuspid regurgitation.

3.4 | Tricuspid regurgitation severity

Among dogs with PH, 35/89 (39%) presented mild TR, 26/89 (29%) moderate TR, and 28/89 (32%) severe TR. The prevalence of severe TR was significantly higher in dogs with moderate and severe PH than in dogs with mild PH ($P < .001$; Table 1). The TRPG was significantly higher in dogs with moderate and severe TR than in dogs with mild TR ($P < .001$; Table 5).

The prevalence of severe TR was higher in dogs with R-CHF (20/22, 91%) than in dogs without R-CHF (8/67, 12%; $P < .001$). Dogs with severe TR presented a higher RVEDA index than in dogs with mild and moderate TR ($P < .001$). TAPSEn and FACn did not significantly differ among dogs with mild, moderate and severe TR ($P = .50$ and $P = .63$, respectively).

Finally, TR severity was not different between dogs with precapillary (mild TR: 25/58, 43%; moderate TR: 15/58, 26%; severe TR: 18/58, 31%) and postcapillary PH (mild TR: 10/31, 32%; moderate TR 11/31, 36%; severe TR: 10/31, 32%) ($P = .20$).

3.5 | Reproducibility of measurements

Intraobserver and interobserver measurement variability for RVEDA yielded an average CV of 7.4% and 9.1%, respectively. Intraobserver and interobserver measurement variability for TAPSE yielded an average CV of 3.2% and 4.7%, respectively. Intraobserver and interobserver measurement variability for FAC yielded an average CV of 6.6% and 12.9%, respectively.

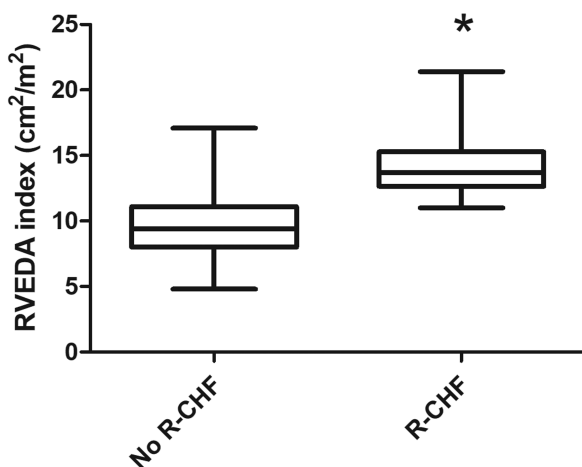


FIGURE 3 Box and whiskers plot for right ventricular end-diastolic area (RVEDA) index in dogs with and without right-sided congestive heart failure (R-CHF). The RVEDA index was significantly higher in dogs with R-CHF than in dogs without R-CHF (* $P < .001$)

4 | DISCUSSION

The major findings of this prospective study are that ¹ RV size, when evaluated with the RVEDA index, increases in dogs with moderate and severe PH, and it predicts R-CHF; ² TR severity is the only independent determinant of RV size in dogs with PH; and ³ RV systolic function, assessed with TAPSEn and FACn, does not seem to be a predictor of R-CHF in dogs with PH.

In line with the fact that cross-sectional areas within the heart are likely to correlate positively with BSA (proportional to $BW^{2/3}$), we found that RVEDA correlated positively with BSA, showing a very high coefficient of determination ($r^2 = .86$). There is a linear correlation between RVEDA and BSA in humans, and the normalization of the RVEDA to the BSA is recommended to account for the different biometric characteristics of human patients.^{13,34,35} Thus, considering the clinically acceptable measurement variability, as found in this study, RVEDA indexed to BSA can be used to objectively evaluate RV size in dogs. We identified a normal reference range for this index in healthy dogs.

This study uses a 2D echocardiographic index of RV size in dogs with PH. Similar to previous investigations in humans and in dogs,^{22,23,36,37} in our study the RV size increases in dogs with moderate-to-severe PH and not in those with mild PH. In contrast, a recent study in dogs did not detect any differences in RV size in dogs with a different severity of PH,²⁴ but the authors of that study assessed RV size using linear dimensions obtained by M-mode. This finding could reflect the inaccuracy of M-mode in assessing RV size. Another study in dogs reported RV dilation not only in moderate-to-severe PH but also in dogs with mild PH.²⁰ However, in this study, RV dilation was only based on a subjective assessment, which is relatively inaccurate compared to objective assessment, as demonstrated in humans.^{9-12,25}

In our study, the RVEDA index was significantly higher in dogs with R-CHF compared to those without R-CHF, and an RVEDA index of >10.9 cm²/m², best predicted R-CHF. In line with our results, a previous study in dogs with induced PH by pulmonary artery banding reported a significant increase in RVEDA in onset R-CHF.³⁸ This result is in accordance with the literature for humans, where RV enlargement is of clinical importance as it reflects RV pressure and volume overload, and is associated with prognosis with PH.^{3,5,7,8}

Multivariate analysis revealed that RV size is mainly influenced by TR severity (volume-overload) rather than by TRPG (pressure-overload) in dogs with PH. This is in line with the literature on humans, where RV size and remodeling in patients with PH is mostly influenced by TR severity.^{39,40} In patients with PH, TR is mainly caused by tricuspid annulus dilation and papillary muscle displacement secondary to RV remodeling.^{39,41} The development of TR leads to RV volume overload and presumably triggers a cycle of progressive annular dilation, RV remodeling, and worsening of TR.^{38,39} In addition, considering that in our study almost all the dogs with R-CHF exhibited a severe TR, we can hypothesize that the severity of the TR is more important for the development of the R-CHF rather than RV systolic dysfunction. Again, this is in line with the literature on humans, where TR severity is negative prognostic factor.^{40,42,43}

TAPSE and FAC are reproducible indices of RV systolic function in veterinary practice.²⁶ In our study, TAPSEn and FACn did not

TABLE 4 Sensitivity and specificity of different cut-off points of the RVEDA index for the prediction of R-CHF in 89 dogs with PH

| | AUC | 95% CI | P | Cut-off | Se (%) | Sp (%) | Youden index |
|-------------|------|-----------|-------|---------|--------|--------|--------------|
| RVEDA index | 0.90 | 0.84-0.96 | <.001 | 10.9* | 100 | 73.1 | 73.1 |
| | | | | 17.2 | 18.2 | 100 | |

Abbreviations: AUC, area under receiver operating characteristic curve; RVEDA, right ventricular area index; Se, sensitivity; Sp, specificity. The value with the asterisk (*) represents the clinically significant cut-off, with the least amount of overlap between groups (optimal combination of sensitivity and specificity, and highest Youden index).

TABLE 5 Clinical and echocardiographic data of dogs with pulmonary hypertension according to tricuspid regurgitation severity (n = 89)

| | Mild TR | Moderate TR | Severe TR |
|--|------------------|----------------------------|---------------------------------|
| N cases | 35 | 26 | 28 |
| TRPG (mmHg) | 49 (38-139) | 75.5 (40-130) ^a | 87.5 (52-149) ^a |
| RVEDA index (cm ² /m ²) | 8.5 (4.8-15.7) | 9.7 (6.2-14.5) | 13.4 (10.7-21.4) ^{a,b} |
| TAPSEn | 6.0 (3.3-10.3) | 6.1 (3.4-9.7) | 7.2 (2.3-10.9) |
| FACn | 61.4 (32.7-99.5) | 58.7 (22.3-93.4) | 65.5 (32.6-95.8) |
| R-CHF | 0 (0%) | 2 (8%) | 20 (71%) ^{a,b} |

Abbreviations: FACn, fractional area change normalized for body weight; R-CHF, right-sided congestive heart failure; RVEDA, right ventricular end-diastolic area; TAPSEn, tricuspid annular plane systolic excursion normalized for body weight; TR, tricuspid regurgitation; TRPG, tricuspid regurgitation pressure gradient.

^a P < .001 compared to mild TR.

^b P < .001 compared to moderate TR.

Data represent median (min-max).

significantly differ among dogs with and without PH, irrespectively of severity. Similarly, in our sample population no differences in TAPSEn and FACn were found between dogs with and without R-CHF. In the veterinary literature, there is contrasting data regarding RV systolic function in dogs with PH. Two studies reported a significant reduction in TAPSE²⁰ and FAC²³ in dogs with severe PH. In contrast, in other studies on PH in dogs with myxomatous mitral valve disease, TAPSE did not significantly change with PH severity.^{22,24} Possible reasons for this discrepancy are different reference intervals for TAPSE, different sample population size, different underlying etiology of PH, and possibly different clinical severity among dogs with severe PH. Moreover, severe TR can influence the Doppler estimation of pulmonary arterial pressure^{44,45} and is a significant confounding factor when applying TAPSE to assess RV function.⁴⁶ As is known,⁴⁶ TAPSE increases with TR severity irrespectively of RV function. Consequently, differences in TR severity among studies could potentially influence the estimation and interpretation of RV systolic function. Our results highlight that dogs with postcapillary PH showed higher RV systolic function measurements than dogs with precapillary PH. Other studies in dogs with myxomatous mitral valve disease have also found that TAPSE did not change with PH severity.^{22,24} This result could be due to the hyperdynamic left ventricle in myxomatous mitral valve disease which causes a traction on the RV free wall and subsequently a shift in the tricuspid annulus toward the left due to ventricular interdependence.^{24,47}

Our study has some limitations. First, the sample population was not homogeneous, in fact, the healthy group was younger and weighed relatively more than the dogs with PH. Second, the body condition score was not evaluated in the study population, and since the RVEDA index is calculated using the BSA, the body condition score could have influenced this index. Similarly, the presence of ascites could have influenced the RVEDA index; however, the body weight was always evaluated after paracentesis. Third, in our study PH was classified according to the TRPG and not by invasive

measurements of pulmonary artery systolic pressures (ie, right heart catheterization), which represents the gold standard. However, quantification of the TRPG is currently used by most cardiologists to estimate pulmonary artery systolic pressure in small animals.¹ In addition, a TRPG cut-off value of 36 mm Hg was used to diagnose PH in line with the literature^{21,23,27}; however, there is no consensus regarding the best echocardiographic cut-off to diagnose PH in dogs. Thus, if a different TRPG cut-off had been used, our results might possibly have been different. Fourth, the RV outflow tract was not included in the evaluation of RV size, as the RVEDA was measured from the left apical 4-chamber view optimized for the right heart as previously described.^{11,16,26} Thus, a possible dilation of the RV outflow tract could have been missed using the RVEDA as the only measurement of RV size. Lastly, dogs were divided into precapillary and postcapillary PH only based on clinical findings. Right heart catheterization is the gold standard for this classification and to identify possible cases of mixed PH (precapillary and postcapillary), however it is invasive and not commonly used in the veterinary clinical practice.

In conclusion, we believe that the RVEDA index can be used in the quantitative assessment of RV size in dogs. It can provide beneficial complementary information in dogs with PH and predict R-CHF. TR severity is the main determinant of RV enlargement in dogs with PH, and it seems to play a key role in the occurrence of R-CHF. RV systolic function, assessed with TAPSE and FAC, does not seem to be a predictor of R-CHF. Further longitudinal studies are needed to evaluate the prognostic role of the RVEDA index and to evaluate a less load-independent variable of RV systolic function, such as the RV strain rate, in dogs with PH.

ACKNOWLEDGMENTS

The authors are grateful to Valentina Meucci for the statistical analysis. The work was carried out at the Department of Veterinary

Sciences, University of Pisa (Italy), the Istituto Veterinario di Novara (Italy), the Veterinary Hospital Città di Pavia (Italy), and the Department of Animal Medicine and Surgery, University of Murcia (Spain). Part of the study was presented as an oral communication at the 27th ECVIM-CA Congress, September 2017, St. Julian's, Malta.

CONFLICT OF INTEREST DECLARATION

Authors declare no conflict of interest.

OFF-LABEL ANTIMICROBIAL DECLARATION

Authors declare no off-label use of antimicrobials.

INSTITUTIONAL ANIMAL CARE AND USE COMMITTEE (IACUC) OR OTHER APPROVAL DECLARATION

The study protocol was approved by the Institutional Welfare and Ethics Committee of the University of Pisa (permission number 38/2015).

ORCID

Tommaso Vezzosi  <http://orcid.org/0000-0001-8301-6582>

Federica Marchesotti  <http://orcid.org/0000-0002-8267-5137>

Eric Zini  <http://orcid.org/0000-0002-7580-1297>

REFERENCES

- Kellihan HB, Stepien RL. Pulmonary hypertension in dogs: diagnosis and therapy. *Vet Clin North Am Small Anim Pract.* 2010;40:623-641.
- Gaynor SL, Maniar HS, Bloch JB, et al. Right atrial and ventricular adaptation to chronic right ventricular pressure overload. *Circulation.* 2005;112:212-218.
- Vonk-Noordegraaf A, Haddad F, Chin KM, et al. Right heart adaptation to pulmonary arterial hypertension: physiology and pathobiology. *J Am Coll Cardiol.* 2013;62:D22-D33.
- Ghio S, Gavazzi A, Campana C, et al. Independent and additive prognostic value of right ventricular systolic function and pulmonary artery pressure in patients with chronic heart failure. *J Am Coll Cardiol.* 2001;37:183-188.
- van Wolferen SA, Marcus JT, Boonstra A, et al. Prognostic value of right ventricular mass, volume, and function in idiopathic pulmonary arterial hypertension. *Eur Heart J.* 2007;28:1250-1257.
- Brierre G, Blot-Souletie N, Degano B, et al. New echocardiographic prognostic factors for mortality in pulmonary arterial hypertension. *Eur J Echocardiogr.* 2010;11:516-522.
- Ghio S, Pazzano AS, Klersy C, et al. Clinical and prognostic relevance of echocardiographic evaluation of right ventricular geometry in patients with idiopathic pulmonary arterial hypertension. *Am J Cardiol.* 2011;107:628-632.
- Kassem E, Humpl T, Friedberg MK. Prognostic significance of 2-dimensional, M-mode, and Doppler echo indices of right ventricular function in children with pulmonary arterial hypertension. *Am Heart J.* 2013;165:1024-1031.
- Grünig E, Peacock AJ. Imaging the heart in pulmonary hypertension: an update. *Eur Respir Rev.* 2015;24:653-664.
- Bossone E, D'Andrea A, D'Alto M, et al. Echocardiography in pulmonary arterial hypertension: from diagnosis to prognosis. *J Am Soc Echocardiogr.* 2013;26:1-14.
- Rudski LG, Lai WW, Afilalo J, et al. Guidelines for the echocardiographic assessment of the right heart in adults: a report from the American society of echocardiography endorsed by the European association of echocardiography, a registered branch of the European society of cardiology, and the Canadian society of echocardiography. *J Am Soc Echocardiogr.* 2010;23:685-713.
- Kossaify A. Echocardiographic Assessment of the Right Ventricle, from the Conventional Approach to Speckle Tracking and Three-Dimensional Imaging, and Insights into the "Right Way" to Explore the Forgotten Chamber. *Clin Med Insights Cardiol.* 2015;9:65-75.
- Lang RM, Badano LP, Mor-Avi V, et al. Recommendations for cardiac chamber quantification by echocardiography in adults: an update from the American Society of Echocardiography and the European Association of Cardiovascular Imaging. *Eur Heart J Cardiovasc Imaging.* 2015;16:233-270.
- Grünig E, Biskupek J, D'Andrea A, et al. Reference ranges for and determinants of right ventricular area in healthy adults by two-dimensional echocardiography. *Respiration.* 2015;89:284-293.
- Marra AM, Egenlauf B, Ehlken N, et al. Change of right heart size and function by long-term therapy with riociguat in patients with pulmonary arterial hypertension and chronic thromboembolic pulmonary hypertension. *Int J Cardiol.* 2015;195:19-26.
- Gentile-Solomon JM, Abbott JA. Conventional echocardiographic assessment of the canine right heart: reference intervals and repeatability. *J Vet Cardiol.* 2016;18:234-247.
- Vezzosi T, Domenech O, Iacona M, et al. Echocardiographic evaluation of the right atrial area index in dogs with pulmonary hypertension. *J Vet Intern Med.* 2018;32:42-47.
- Anavekar NS, Gerson D, Skali H, et al. Two-dimensional assessment of right ventricular function: an echocardiographic-MRI correlative study. *Echocardiography.* 2007;24:452-456.
- Visser LC. Right ventricular function: imaging techniques. *Vet Clin North Am Small Anim Pract.* 2017;47:989-1003.
- Pariat R, Saelinger C, Strickland KN, et al. Tricuspid annular plane systolic excursion (TAPSE) in dogs: reference values and impact of pulmonary hypertension. *J Vet Intern Med.* 2012;26:1148-1154.
- Borgarelli M, Abbott J, Braz-Ruivo L, et al. Prevalence and prognostic importance of pulmonary hypertension in dogs with myxomatous mitral valve disease. *J Vet Intern Med.* 2015;29:569-574.
- Tidholm A, Höglund K, Häggström J, et al. Diagnostic value of selected echocardiographic variables to identify pulmonary hypertension in dogs with myxomatous mitral valve disease. *J Vet Intern Med.* 2015;29:1510-1517.
- Visser LC, Im MK, Johnson LR, et al. Diagnostic value of right pulmonary artery distensibility index in dogs with pulmonary hypertension: comparison with doppler echocardiographic estimates of pulmonary arterial pressure. *J Vet Intern Med.* 2016;30:543-552.
- Poser H, Berlanda M, Monacoli M, et al. Tricuspid annular plane systolic excursion in dogs with myxomatous mitral valve disease with and without pulmonary hypertension. *J Vet Cardiol.* 2017;19:228-239.
- Ling LF, Obuchowski NA, Rodriguez L, et al. Accuracy and interobserver concordance of echocardiographic assessment of right ventricular size and systolic function: a quality control exercise. *J Am Soc Echocardiogr.* 2012;25:709-713.
- Visser LC, Scansen BA, Schober KE, et al. Echocardiographic assessment of right ventricular systolic function in conscious healthy dogs: repeatability and reference intervals. *J Vet Cardiol.* 2015;17:83-96.
- Johnson L, Boon J, Orton EC. Clinical characteristics of 53 dogs with Doppler-derived evidence of pulmonary hypertension: 1992-1996. *J Vet Intern Med.* 1999;13:440-447.
- Galiè N, Humbert M, Vachiery JL, et al. 2015 ESC/ERS Guidelines for the diagnosis and treatment of pulmonary hypertension: The Joint Task Force for the Diagnosis and Treatment of Pulmonary Hypertension of the European Society of Cardiology (ESC) and the European Respiratory Society (ERS); Endorsed by: Association for European Paediatric and Congenital Cardiology (AEPC), International Society for Heart and Lung Transplantation (ISHLT). *Eur Heart J.* 2016;37:67-119.
- Visser LC, Scansen BA, Brown NV, et al. Echocardiographic assessment of right ventricular systolic function in conscious healthy dogs following a single dose of pimobendan versus atenolol. *J Vet Cardiol.* 2015;17:161-172.

30. Sato T, Tsujino I, Sugimoto A, et al. The effects of pulmonary vasodilating agents on right ventricular parameters in severe group 3 pulmonary hypertension: a pilot study. *Pulm Circ*. 2016;6:524-531.
31. Thomas WP, Gaber CE, Jacobs GJ, et al. Recommendations for standards in transthoracic two-dimensional echocardiography in the dog and cat. *J Vet Intern Med*. 1993;7:247-252.
32. Chun R, Garrett LD, Vail DM. Cancer chemotherapy. In: Vail DM, ed. *Withrow and MacEwen's Small Animal Clinical Oncology*. 4th ed. St. Louis: Saunders; 2007:163-192.
33. Lancellotti P, Moura L, Pierard LA, et al. European association of echocardiography recommendations for the assessment of valvular regurgitation. Part 2: mitral and tricuspid regurgitation (native valve disease). *Eur J Echocardiogr*. 2010;11:307-332.
34. D'Oronzio U, Senn O, Biaggi P, et al. Right heart assessment by echocardiography: gender and body size matters. *J Am Soc Echocardiogr*. 2012;25:1251-1258.
35. Willis J, Augustine D, Shah R, et al. Right ventricular normal measurements: time to index? *J Am Soc Echocardiogr*. 2012;25:1259-1267.
36. Raymond RJ, Hinderliter AL, Willis PW, et al. Echocardiographic predictors of adverse outcomes in primary pulmonary hypertension. *J Am Coll Cardiol*. 2002;39:1214-1219.
37. Chin KM, Kim NHS, Rubin LJ. The right ventricle in pulmonary hypertension. *Coron Artery Dis*. 2005;16:13-18.
38. Hsieh CM, Mishkel GJ, Cardoso PF, et al. Production and reversibility of right ventricular hypertrophy and right heart failure in dogs. *Ann Thorac Surg*. 1992;54:104-110.
39. Hinderliter AL, Willis PW 4th, Long WA, et al. Frequency and severity of tricuspid regurgitation determined by Doppler echocardiography in primary pulmonary hypertension. *Am J Cardiol*. 2003;91:1033-1037.
40. Mutlak D, Aronson D, Lessick J, et al. Functional tricuspid regurgitation in patients with pulmonary hypertension: is pulmonary artery pressure the only determinant of regurgitation severity? *Chest*. 2009;135:115-121.
41. Afilalo J, Grapsa J, Nihoyannopoulos P, et al. Leaflet area as a determinant of tricuspid regurgitation severity in patients with pulmonary hypertension. *Circ Cardiovasc Imaging*. 2015;8:e002714.
42. Koelling TM, Aaronson KD, Cody RJ, et al. Prognostic significance of mitral regurgitation and tricuspid regurgitation in patients with left ventricular systolic dysfunction. *Am Heart J*. 2002;144:524-529.
43. Nath J, Foster E, Heidenreich PA. Impact of tricuspid regurgitation on long-term survival. *J Am Coll Cardiol*. 2004;43:405-409.
44. Özpelit E, Akdeniz B, Özpelit EM, et al. Impact of severe tricuspid regurgitation on accuracy of echocardiographic pulmonary artery systolic pressure estimation. *Echocardiography*. 2015;32:1483-1490.
45. Fei B, Fan T, Zhao L, et al. Impact of severe tricuspid regurgitation on accuracy of systolic pulmonary arterial pressure measured by Doppler echocardiography: analysis in an unselected patient population. *Echocardiography*. 2017;34:1082-1088.
46. Hsiao SH, Lin SK, Wang WC, et al. Severe tricuspid regurgitation shows significant impact in the relationship among peak systolic tricuspid annular velocity, tricuspid annular plane systolic excursion, and right ventricular ejection fraction. *J Am Soc Echocardiogr*. 2006;19:902-910.
47. Chapel EH, Scansen BA, Schober KE, et al. Echocardiographic estimates of right ventricular systolic function in dogs with myxomatous mitral valve disease. *J Vet Intern Med*. 2018;32:64-71.

How to cite this article: Vezzosi T, Domenech O, Costa G, et al. Echocardiographic evaluation of the right ventricular dimension and systolic function in dogs with pulmonary hypertension. *J Vet Intern Med*. 2018;32:1541-1548. <https://doi.org/10.1111/jvim.15253>