

# Severe Open Dislocation of the Hip with Exposed Femoral Head

## A Case Report

Stefano Zanarella, MD, Alessandro Cappellari, MD, Alvise Ruaro, MD, and Pietro Ruggieri, MD, PhD

*Investigation performed at Department of Orthopedics and Orthopedic Oncology, University of Padova, Azienda Ospedaliera di Padova, Italy*

### Abstract

**Case:** A 54-year-old woman was brought to our emergency department with an inferomedial open hip dislocation without fracture secondary to a railway trauma. We performed hip reduction, wound debridement, and stabilization with external fixation. After 7 months, hip arthroplasty was performed for severe hip instability and avascular necrosis of the femoral head.

**Conclusion:** Open hip dislocation is an uncommon injury that is caused by high-energy trauma. It may be associated with serious management problems and complications, including infection and avascular necrosis of the femoral head.

Open dislocation of the hip is an exceptional event and rarely described in the absence of proximal femoral fracture or major acetabular fracture<sup>1-7</sup>. Here, we present a case of severe open dislocation of the hip with protrusion of the femoral head through the perineal skin and a literature review. The few reports on open hip dislocation in the literature have usually involved anterior displacement<sup>6,7</sup>. Early complications of severe hip dislocation are infection, muscle lesions, peripheral nerve palsy, and avascular necrosis (AVN)<sup>1,3</sup>. Posttraumatic arthritis is the most common sequela of hip dislocation (20%)<sup>7</sup>. Our patient was treated by soft-tissue debridement, hip reduction, and stabilization with external fixation. After 7 months, hip arthroplasty was performed for severe instability of the hip and AVN of the femoral head.

The patient was informed that data concerning the case would be submitted for publication, and she provided consent.

### Case Report

A 54-year-old woman was brought to the emergency department after a high-speed railway accident. She had been struck by a train as a pedestrian during a suicide attempt. She had an open dislocation of the right hip with protrusion of the femoral head through the perineal skin (Figs. 1-A and 1-B). On examination, the affected limb was in extreme external rotation and abduction. There were no signs of vascular

complications. Whole-body computed tomography scans revealed dislocation of the right hip (Figs. 2-A and 2-B). She also had multiple wounds to her left leg, multiple spinal fractures, bilateral rib fractures, a right pneumothorax, a pelvic fracture involving the sacrum and left ilium, and a complex lesion of the right knee joint with a comminuted tibial fracture.

The patient was taken to our operating room. On examination under anesthesia, the adductor magnus and adductor longus muscles were lacerated, the external rotators were severely damaged, and the articular ligament and hip capsule were disrupted. The femoral head was exposed and pressing on the perineum. There was also damage to the iliopsoas muscle. The lesion was assessed to be 9/15 according to the Orthopaedic Trauma Association open fracture classification (S2, M3, A1, C2, and B1)<sup>8</sup>.

Evaluation by a gynecologist and a general surgeon found no evidence of a lesion in the perineal soft tissues. There were no signs of major acetabular fracture. After soft-tissue debridement, the femoral head was reduced through a wound in the adductors. Accurate reduction was confirmed by an intraoperative image intensifier. Although the right hip joint was clinically unstable, an open approach was not used because of the patient's critical condition. The pelvic fractures and the right hip and knee were stabilized by external fixation. The hip joint was stabilized in mild distraction, 10° of flexion, regular

**Disclosure:** The **Disclosure of Potential Conflicts of Interest** forms are provided with the online version of the article (<http://links.lww.com/JBJS/CC/B590>).

Copyright © 2021 The Authors. Published by The Journal of Bone and Joint Surgery, Incorporated. All rights reserved. This is an open-access article distributed under the terms of the [Creative Commons Attribution-Non Commercial-No Derivatives License 4.0](https://creativecommons.org/licenses/by-nc-nd/4.0/) (CCBY-NC-ND), where it is permissible to download and share the work provided it is properly cited. The work cannot be changed in any way or used commercially without permission from the journal.

**Keywords:** hip dislocation; trauma; open dislocation; avascular necrosis

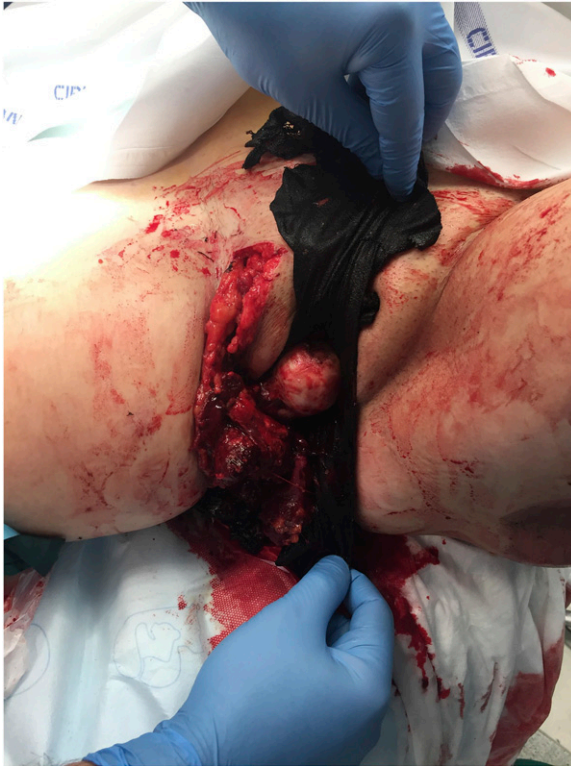

Fig. 1-A

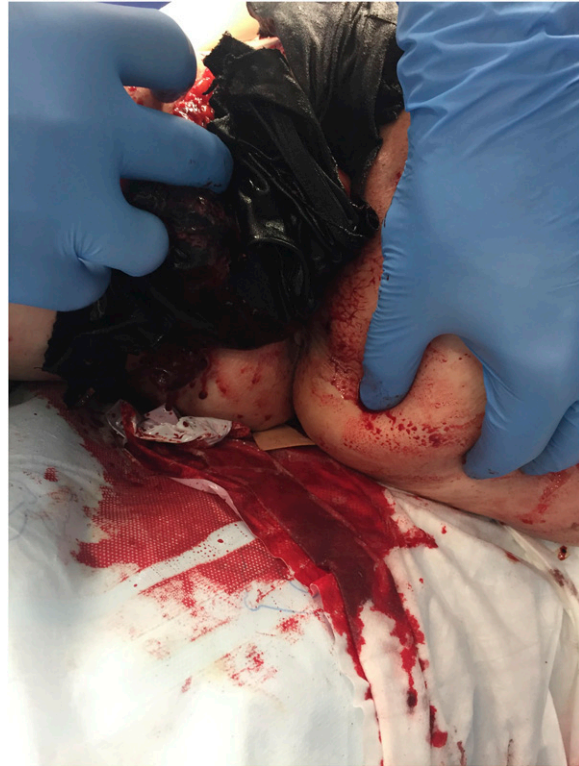

Fig. 1-B

Clinical findings in the operating room with the femoral head dislocated in the perineum (**Figs. 1-A and 1-B**).

rotation, and 15° of abduction (Figs. 3-A and 3-B). All other wounds, including the wound causing exposure of the right tibial plateau fracture and those along the left leg and foot, were washed, debrided, and sutured.

A 7-day course of intravenous cefazolin, amikacin, and metronidazole was prescribed. Radiographs showed reduction of the dislocation with discrete articular congruence. A small bone fragment at the top of the acetabular lip was noticed as a minimal avulsion of the labrum (Fig. 4-A). Paralysis of the sciatic nerve was evident on early postoperative evaluation. The perineal wounds healed satisfactorily in 2 weeks. Other wounds required escharotomy, vacuum-assisted closure, and up to 8 weeks of antibiotic therapy. There were no signs of infection. The patient's underlying psychiatric condition worsened after the trauma as a result of immobilization, pain, and loss of function. The external fixator was removed after 1 month, which was earlier than planned because the patient could no longer tolerate it. There was no immediate clinical evidence of instability of the hip joint after removal of the external fixator (Fig. 4-B).

The pelvic fractures healed in 1 month. The plan was to start active and passive mobilization after 45 days and to allow partial weight bearing after 2 months; however, the patient could not comply with a rehabilitation program because of her major depressive disorder.

At the 3-month follow-up visit, the patient had mild pain in the right hip joint and a limited range of motion (Harris hip score

46/100). Radiographs revealed partial dislocation of the right hip (Fig. 5-A). The sciatic nerve paralysis resolved in 6 months.

Seven months after the trauma, the patient developed signs of AVN at the femoral head (Fig. 5-B) and had significant posttraumatic arthritis of the right knee. Both joints underwent reconstruction with ceramic-on-ceramic total hip and knee arthroplasty. At the 2-year follow-up, the patient was mobilizing with 1 crutch and had a Harris hip score of 85 and a Knee Society Score of 72 (Figs. 6-A and 6-B).

### Discussion

The native hip joint is stable because of its bony geometry and strong ligaments, which can resist significant mechanical stress. High-energy trauma is required to dislocate the native hip and is involved in hip dislocation in up to 95% of patients<sup>1</sup>. The anterior ligaments are strong; therefore, hip trauma commonly causes posterior dislocation. Anterior dislocations occur in fewer than 10% to 15% of cases<sup>2,3</sup>. Our patient had extensive disruption of the soft tissue around the hip joint, including the entire capsule, the anterior ligaments, a small avulsion of the labrum, and all the abductor and external rotators, which resulted in multidirectional instability of the joint.

Many different classification systems for hip fractures and dislocations have been devised since those proposed by Thompson and Epstein in 1951 and by Stewart and Milford in 1954<sup>4</sup>. Patients with acetabular or femoral head fractures have a

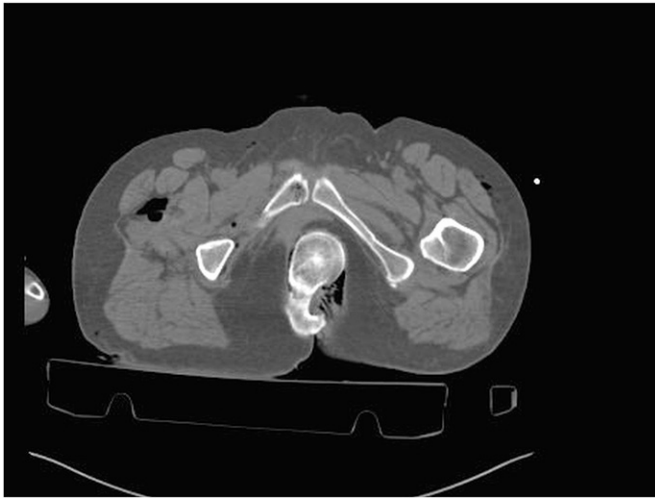


Fig. 2-A

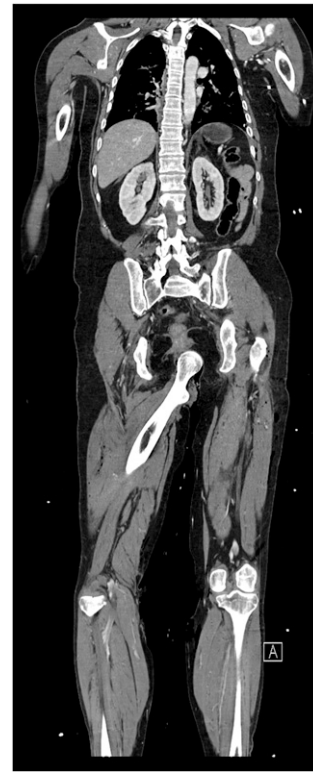

Fig. 2-B

Computed tomography scan images in axial (**Fig. 2-A**) and coronal (**Fig. 2-B**) views.

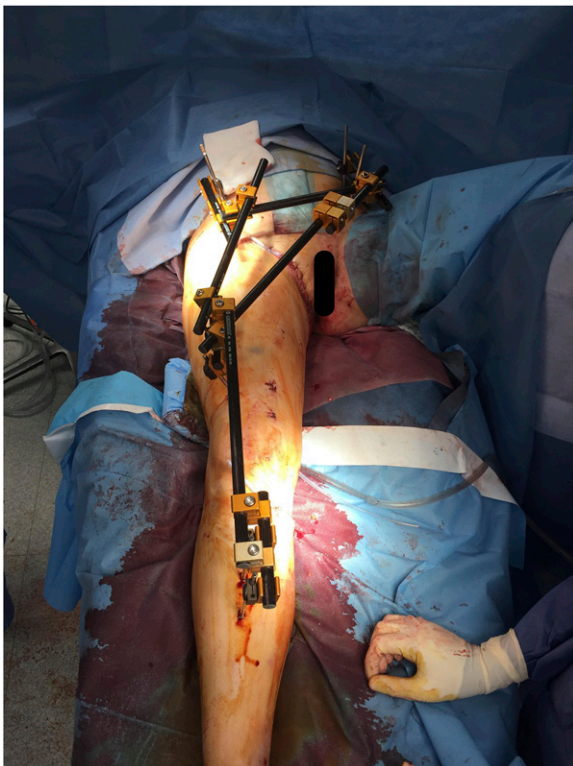

Fig. 3-A

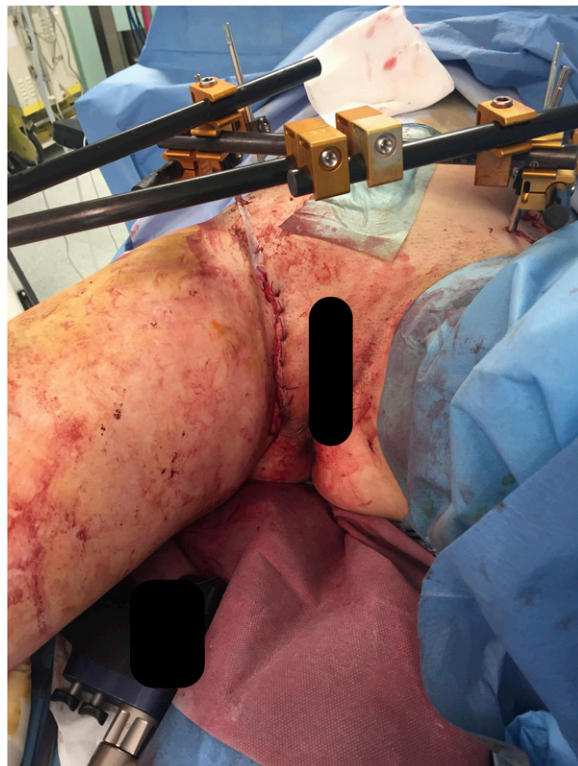


Fig. 3-B

**Fig. 3-A and 3-B** External fixation after debridement and open reduction.



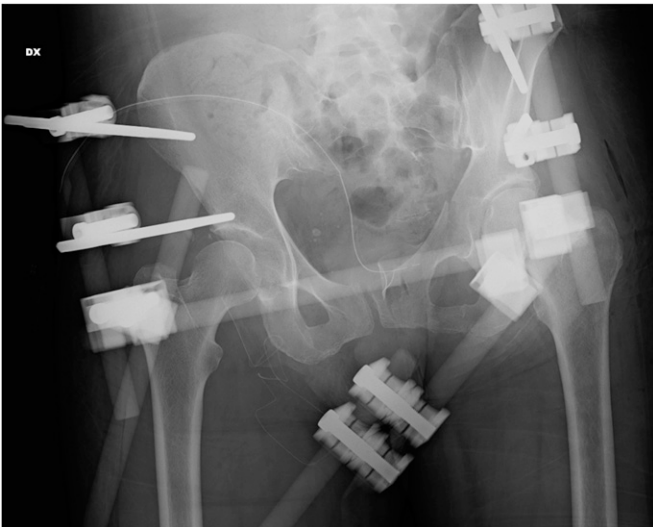

Fig. 4-A

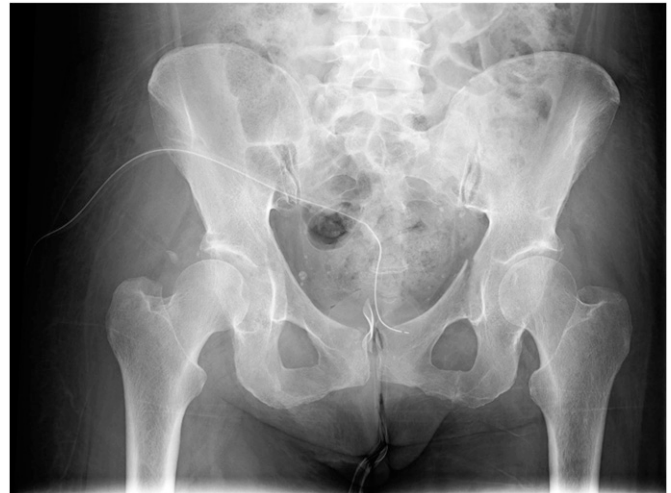

Fig. 4-B

**Fig. 4-A** Postoperative x-ray after reduction. **Fig. 4-B** X-ray after external fixation removal.

worse prognosis<sup>7</sup>. Femoral head fractures are less common than acetabular fractures, with an incidence of 5% to 15%<sup>3-7</sup>. Few cases of open hip dislocation have been described; however, anterior dislocation is most common<sup>6,7</sup>. Our case might represent a unique subset because of the absence of proximal femoral fracture, the extensive disruption of the soft tissue around the joint, and the inferomedial exposure of the femoral head.

We stabilized the hip joint at 10° of flexion and in slight abduction to balance the multidirectional instability. Recurrent hip and knee pain and poor patient compliance resulted in early removal of the external fixation. At that point, the extensive disruption of the muscles and ligaments had not healed, and early mobilization led to progressive loss of reduction.

Adverse sequelae of native hip joint dislocations include femoral and acetabular fractures, knee injuries, posttraumatic arthritis, sciatic nerve injury, AVN, and heterotopic ossification<sup>2,3,5</sup>. Posttraumatic arthritis is the most common long-term sequela of simple native dislocation, with an incidence of approximately 20%<sup>7</sup>.

Ipsilateral knee injuries are often encountered after native dislocations, as in our case. The most common injuries are effusion (37%), bone bruising (33%), and meniscal tears (30%)<sup>7</sup>. Our patient had sustained a comminuted tibial plate fracture with extensive ligament lesions that caused severe arthrosis and knee instability. The right knee joint was replaced by revision total knee arthroplasty 10 months after the trauma.

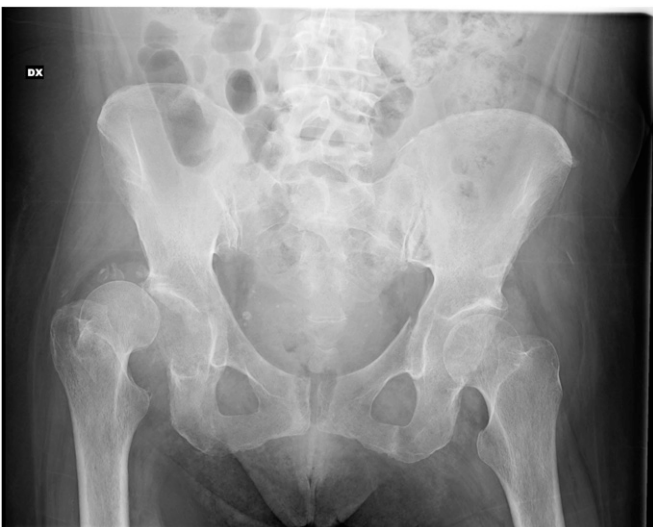

Fig. 5-A

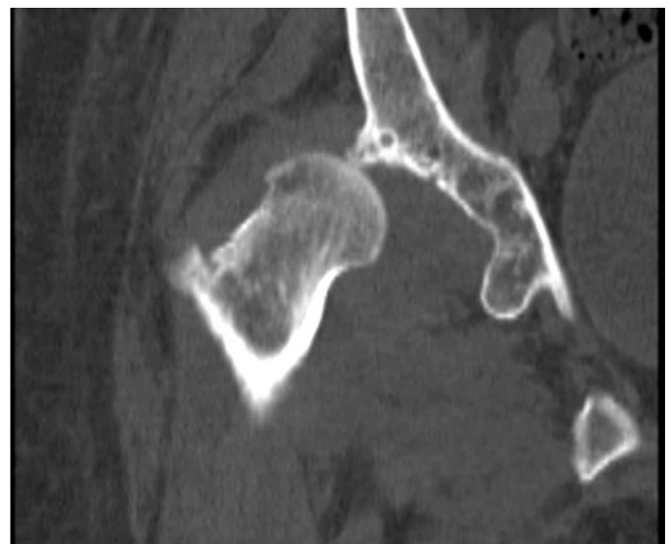

Fig. 5-B

Six-month x-ray (**Fig. 5-A**) and computed tomography scan (**Fig. 5-B**) showing the loosening of the hip joint.

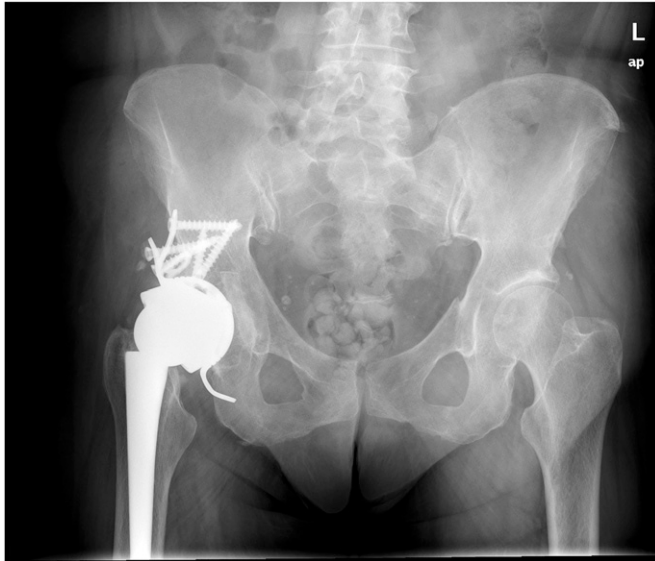

Fig. 6-A

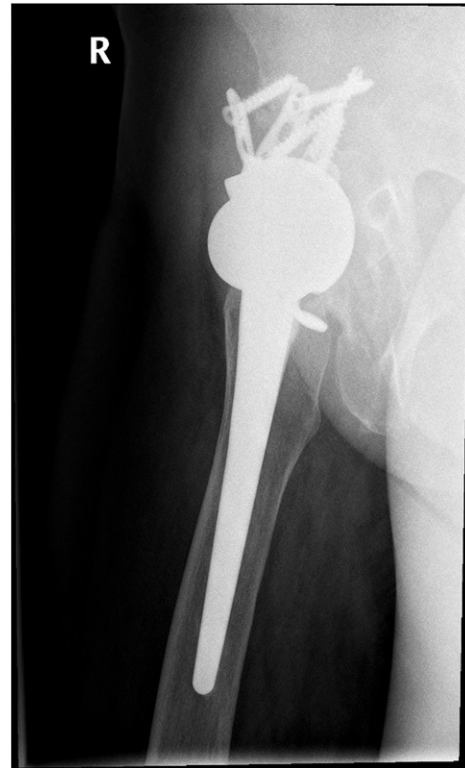

Fig. 6-B

Postoperative x-ray in anteroposterior (**Fig. 6-A**) and lateral (**Fig. 6-B**) views after total hip arthroplasty.

Sciatic nerve injury is the most common neurologic complication of hip dislocation, with an incidence of 10% to 15%<sup>1-3</sup>. This injury may be caused by direct trauma or prolonged compression; delay in reduction may permanently impair nerve function, allowing only partial recovery. In our case, given that the hip dislocation was reduced 5 hours after presentation, it is likely that the sciatic nerve was damaged directly by lacerations to the gluteal muscles, external rotators, and adductors.

The incidence of AVN after hip dislocation is approximately 2% to 10%<sup>1,2</sup>. Various predictive factors have been described, including soft-tissue injuries around the hip joint, delayed treatment, and the direction of dislocation (more late complications occur with posterior dislocations than with anterior dislocations)<sup>1</sup>. Most authors recommend a critical treatment window of 6 to 12 hours, with a worsening outcome after 6 hours. Nevertheless, the rate of secondary complications increases dramatically with time<sup>2</sup>.

The prognosis of open hip dislocation worsens with the complexity and severity of the injury, presence of vascular injuries, patient age, and delayed reduction<sup>1-3,8</sup>. In our case, there was extensive direct muscle injury with involvement of the external rotators and adductors; only the adductor brevis and part of the iliopsoas were spared. Our patient had nerve damage and developed sciatic nerve palsy. The main vascular structures were unaffected. Adequate debridement with antibiotic cover

avoided bone infection. The combination of secondary AVN and extensive muscle disruption led to secondary instability of the hip joint, which required total hip arthroplasty.

In conclusion, dislocation of the native hip is rare, and open dislocation is extremely rare<sup>4,7</sup>. Timing of reduction and careful follow-up for complications affect the outcome<sup>1-3</sup>. Our patient had more severe soft-tissue disruption than is typically seen in cases of open hip dislocation. It is important to assess hip stability for rehabilitation, with careful testing of extension, abduction, and internal rotation in posterior dislocations and of flexion, adduction, and external rotation in anterior dislocations. Associated injuries also have an important role in the outcome<sup>1-3,8</sup>. Late complications often require surgery, such as total hip arthroplasty<sup>1-3,9</sup>. ■

Stefano Zanarella, MD<sup>1</sup>  
Alessandro Cappellari, MD<sup>1</sup>  
Alvise Ruaro, MD<sup>1</sup>  
Pietro Ruggieri, MD, PhD<sup>1</sup>

<sup>1</sup>Orthopaedic Clinic, Department of Surgery, Oncology and Gastroenterology DiSCOG, University of Padua, Padova, Italy

E-mail address for S. Zanarella MD: s.zanarella@gmail.com

---

**References**

---

1. Clegg TE, Roberts CS, Greene JW, Prather BA. Hip dislocations-epidemiology, treatment, and outcomes. *Injury*. 2010;41(4):329-34.
2. Masiewicz S, Johnson DE. Dislocation, hip (femur), posterior. In: StatPearls [Internet]. Treasure Island, FL: StatPearls Publishing; 2018.
3. Beebe MJ, Bauer JM, Mir HR. Treatment of hip dislocations and associated injuries: current state of care. *Orthop Clin North Am*. 2016;47(3):527-49.
4. Thompson VP, Epstein HC. Traumatic dislocation of the hip; a survey of two hundred and four cases covering a period of twenty-one years. *J Bone Joint Surg Am*. 1951;33-A(3):746-78.
5. DeLee JC, Evans JA, Thomas J. Anterior dislocation of the hip and associated femoral-head fractures. *J Bone Joint Surg Am*. 1980;62(6):960-4.
6. Snoap T, Habeck J, Roberts J. Open hip dislocation through the scrotum without osseous injury. *JBJS Case Connect*. 2017;7(1):e2.
7. Sanders S, Tejwani N, Egol KA. Traumatic hip dislocation—a review. *Bull NYU Hosp Jt Dis*. 2010;68(2):91-6.
8. Orthopaedic Trauma Association: Open Fracture Study Group. OTA open fracture classification. *J Orthop Trauma*. 2010;24(8):457-64.
9. Kellam P, Ostrum RF. Systematic review and meta-analysis of avascular necrosis and posttraumatic arthritis after traumatic hip dislocation. *J Orthop Trauma*. 2016;30(1):10-6.