

DOI 10.24425/122597

Original article

Infrared thermography as a rapid and non-invasive diagnostic tool to detect inflammatory foot diseases in dairy cows

M. Giancesella¹, F. Arfuso², E. Fiore¹, S. Giambelluca¹, E. Giudice³,
L. Armato¹, G. Piccione²

¹Department of Animal Medicine, Productions and Health (MAPS),
University of Padua, Viale dell'Università 16-35020, Padua (PD), Italy

²Department of Veterinary Sciences, University of Messina,
Polo Universitario dell'Annunziata, 98168, Messina (ME), Italy

³Department of Chemical, Biological, Pharmaceutical and Environmental Sciences
University of Messina. Viale Ferdinando Stagno d'Alcontres 31, 98166, S. Agata-Messina, Italy

Abstract

In this study the potential usefulness of infrared thermography (IRT) as a non-invasive tool to rapidly screen the most common non-infectious foot lesions in dairy cows was evaluated. Thirty-eight healthy cows and 38 cows affected by foot diseases were enrolled. Diseased cows showed the following disorders at lateral and medial claw in the hind foot: white line lesion, sole ulcer, sole haemorrhage, horizontal fissure, axial fissure. Thermography images of hind foot were collected for each animal using a digital infrared camera. Foot temperature was measured in four regions: central area of the hind foot (A1), interdigital area of the hind foot (A2), lateral (A3) and medial (A4) claw in the hind foot. Higher temperature values in the regions A1 and A2 compared to A3 and A4 were found in both healthy and diseased cows ($p < 0.001$). Cows affected by foot diseases showed higher foot temperature values compared to healthy cows ($p < 0.05$) in all considered regions. This study highlights the potential application of IRT as a reliable, practical tool for detection of hoof lesions in dairy cows. Multiple scanning images and comparisons between affected and healthy anatomical structures could be useful in defining the consistency of abnormality.

Key words: dairy cows, foot lesion, infrared thermography

Introduction

Diseases of the digital region are frequent in dairy cattle resulting as a severe welfare problem in livestock. Lameness causes detrimental effect on longevity (Cramer et al. 2009), productivity (Green et al. 2009), and

reproductive performance (Garbarino et al. 2009) in dairy cattle. Consequently, it is among disorders causing the largest economic losses in the dairy industry (Ettema and Ostergaard 2006). A number of studies have now reported that higher yielding cows are more likely to become lame (Barkema et al. 1994, Green et al. 2009).

These lame cows might produce less milk than unaffected cows (Warnick et al. 2001, Hernandez et al. 2002) or less milk than their potential as demonstrated by Green et al. (2009) and as predicted by Rowlands and Lucey (1986). Approximately 90% of the causes of lameness involve foot lesions (Murray et al. 1996, Shearer and Van Amstel 2013), although foot lesions do not necessarily result in lameness (Manske et al. 2002). Regardless of whether foot lesions cause lameness, they have a high impact on animal welfare (Bruijnijns et al. 2012) and farm economy. Therefore, the inspection of foot lesions as a routine management practice facilitates earlier identification and treatment of lesions, plausibly enhancing herd productivity and welfare (Chapinal et al. 2009). Each type of lesion has its own pathophysiology and specific risk factors. Foot lesions are commonly categorized according to their aetiology into infectious and non-infectious lesions (International Lameness Committee 2008, Potterton et al. 2012). Infectious lesions include digital dermatitis, interdigital dermatitis, heel horn erosion and foot rot, whereas the most common non-infectious lesions are sole ulcer, toe ulcer, sole haemorrhage and white line disease.

Reliable, practical and non-invasive methods to frequently and rapidly screen in real time for the presence of diseases at foot and cow level are needed. Infrared thermography (IRT) is a non-invasive, quantitative diagnostic tool that measures surface temperature of an object and produces it in a thermal colour map. This technique has been used in both human and veterinary medical research, primarily as a diagnostic tool for the detection of local inflammation due to disease and injury (Talukder et al. 2015, Martello et al. 2016, Perazzi et al. 2016, Schrank et al. 2017). Thermographic imaging has been recently applied in veterinary medicine and in animal production as a potential diagnostic and preventive device to avoid undue stress reactions (Godyń et al. 2013, De Almeida et al. 2016, Salles et al. 2016). In the bovine species, IRT has been used as a diagnostic tool for disease detection (Stelletta et al. 2012, Bortolami et al. 2015, Perazzi et al. 2016, Schrank et al. 2017). IRT has the potential to be a rapid, non-invasive, real-time method of detecting since a symptom of disease is the increase in local temperature from inflammatory reactions in dairy cows (Bortolami et al. 2015). It has been reported that IRT could detect elevated coronary band temperatures in cows with sole haemorrhage lesions (Nikkhah et al. 2005), and that this technique is reliable in detecting elevated temperatures associated with foot lesions (Stokes et al. 2012).

The aim of this study was to evaluate the potential usefulness of IRT as a non-invasive tool to rapidly screen the most common non-infectious foot lesions in dairy cows.

Materials and Methods

All treatments, housing and animal care reported below were carried out in accordance with the standards recommended by the EU Directive 2010/63/EU for animal experiments. The study was conducted in an intensive Italian dairy herd located in North Italy (45° 38' N; 10° 87' E) at an altitude of 68 m. The selected farm had 200 Holstein Frisian dairy cows in lactation with a milk production per cow of about 10,000 kg per year. A maintenance claw-trimming scheme was carried out before the study receiving routine hoof trimming twice a year in the farm (-70 ± 15 days before and $+50 \pm 15$ days after calving). Scheduled hoof trimming sessions were performed by a veterinarian professional claw trimmer two months before calving. Cows were placed in an up-right chute equipped with a head lock gate and a manually operated rope foot lift. Each limb was raised with a rope fastened mid-diaphysis of the third metatarsal bone. All feet were cleansed and trimmed to remove stained, overgrown hoof horn tissue following guidelines of the Dutch Technique (Toussaint Raven 1989); during trimming sessions one leg at a time was raised to preserve as much as possible the welfare of the animals and reduce their stress. All lame cows were also checked and recorded.

Thirty-eight healthy cows (2-3 years old; mean body weight 625 ± 115 kg) and 38 cows affected by foot diseases (2-3 years old; mean body weight 612 ± 102 kg) were enrolled in the study.

A complete clinical examination was performed based on the cow's reaction to palpation. The disease status of the foot was confirmed using a thorough clinical examination. In the cases where both feet compromised the one with more clinical importance was selected based on reaction to palpation and pain. In the case of healthy cows the same procedure was performed.

Enrolled animals were cleaned with cold water and dried in order to remove dirt.

Sick cows have shown the following diseases on the lateral and medial claw foot: white line lesion, sole ulcer, sole haemorrhage, horizontal fissure and axial fissure, according to the guidelines of ICAR Claw Health Atlas (Egger-Danner et al. 2015).

Selected cows were separated from the herd and introduced in a cattle chute where affected feet were nursed.

Thermography images of hind foot were collected from each animal using a digital infrared camera (ThermaCam P25 Model, Flir Systems, Boston, MA, USA). In order to minimize confounding factors all feet were cleaned and trimmed to remove the dirt before the acquisition of thermal images. After foot washing and drying, a five minute timeout period was set to allow

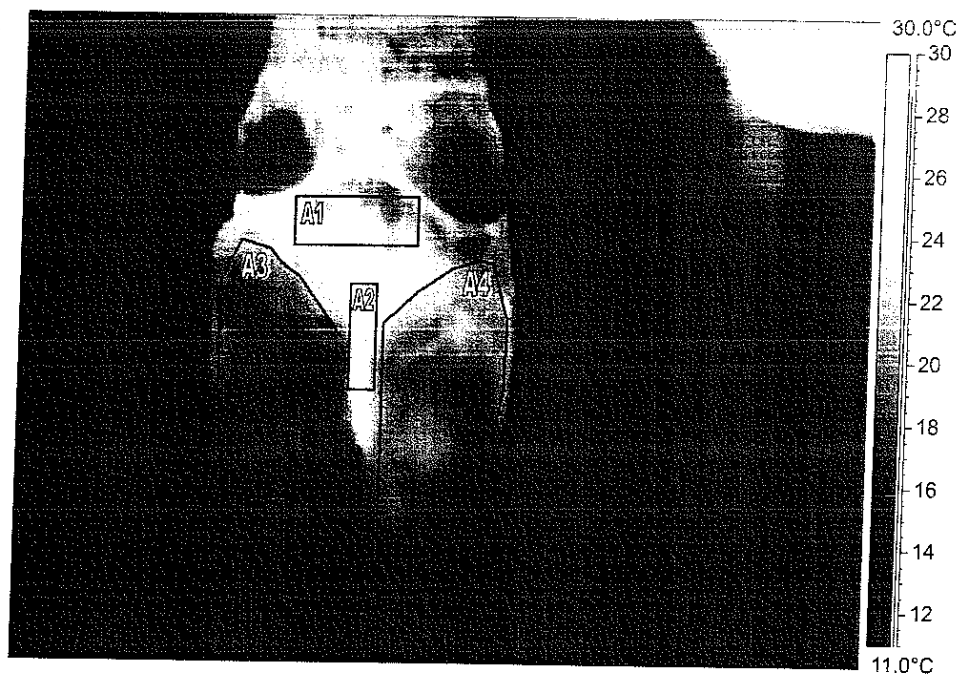


Fig. 1. Representative infrared thermal image of hind foot of dairy cow with the areas of interest: A1, central area; A2, interdigital area; A3, lateral claw; A4, medial claw (settings at gray-scale for subsequent analysis; brighter colors correspond to higher temperatures as indicated on the bar on the right).

blood flow to return to its pre-wash state. Moreover, all thermographic images were collected in a closed, indoor environment, while the animals were restrained in the stall in a standing position.

Mean ambient temperature was recorded at the time of taking the thermal images and it showed a mean value of $16.7 \pm 3.61^\circ\text{C}$.

All images were scanned at the same distance (0.7 m) from the subject in order to reduce the effects of environmental factors on thermographic readings. The settings of the camera were as follows: range of temperature $10\text{--}40^\circ\text{C}$; emissivity of skin: 0.98; reflected air temperature (Trifl): 20°C ; distance between camera and skin surface (Dist): 0.7 m; and field of view (FOV): 23° . The detector consisted of a focal plane array (FPA) uncoiled microbolometer with the following specifications: 320×240 pixels resolution, thermal sensitivity of 0.08°C (at 30°C), spatial resolution (IFOV) of 1.3 mrad, spectral range between 7.5 and $13 \mu\text{m}$ and accuracy $\pm 2^\circ\text{C}$. Automatic corrections based on user input were conducted for reflected ambient temperature, distance, relative humidity, and atmospheric transmission.

Foot temperature was measured in four specific regions of interest including central area of the hind foot (A1), interdigital area the hind foot (A2), lateral (A3) and medial (A4) claw in the hind foot. Absolute mean temperature of each region of interest was calculated using thermography software (Thermacam Researcher Basic 2.8 software, FLIR, Wilsonville, Oregon, USA).

All data were tested for normality of distribution

using Kolmogorov-Smirnov test. All data were normally distributed ($p > 0.05$) and statistical analysis was performed. Two-way analysis of variance (ANOVA) was applied to evaluate the significant change of temperature between the selected foot areas and whether significant differences in foot temperatures occur between healthy cows and cows affected by foot diseases. When significant differences were found, Bonferroni's post hoc comparison was applied. The statistical analysis was performed using the STATISTICA software package (STATISTICA 7 Stat Software Inc., Tulsa, Oklahoma).

Results

All the obtained results are expressed as mean \pm standard deviation ($M \pm SD$).

Figure 1 shows a representative thermographic image of foot with the selected regions of interest.

Statistical analysis showed higher temperature values ($p < 0.001$) in the regions A1 and A2 compared to A3 and A4 in healthy and diseased cows (Fig. 2). Moreover, cows affected by foot diseases showed higher foot temperature values compared to healthy cows ($p < 0.05$) in all considered regions (Fig. 3).

Discussion

The skin temperature and, particularly, foot temperature are of great importance as an indicator of dis-

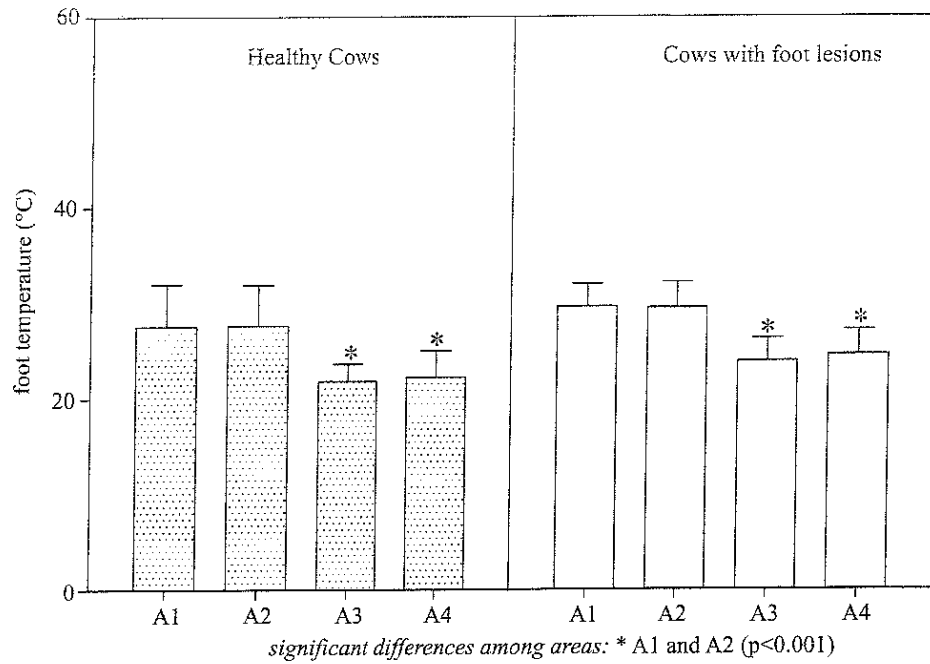
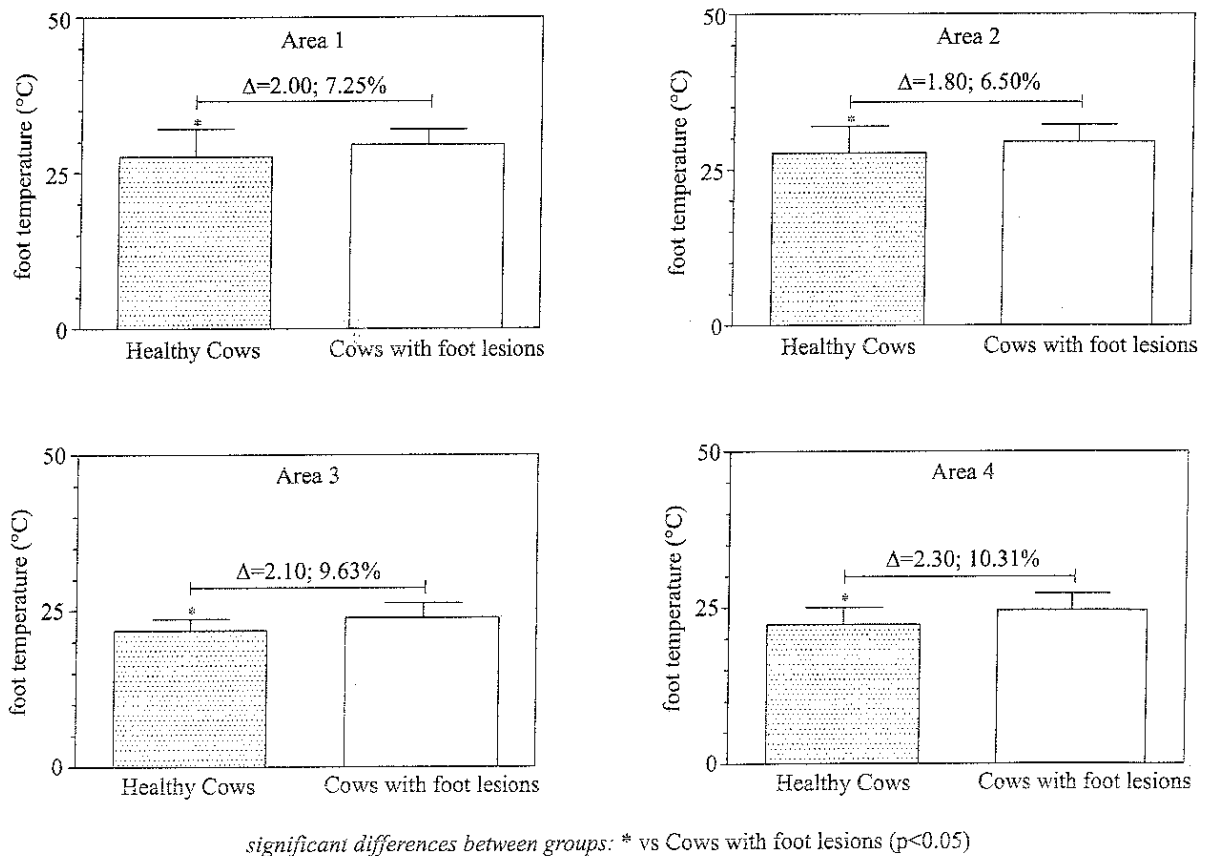


Fig. 2. Mean values \pm standard deviation (\pm SD) of hind foot temperature measured in healthy cows and in cows with foot lesions together with the statistically significant differences found among the different areas of interest (A1, central area; A2, interdigital area; A3, lateral claw; A4, medial claw).



significant differences between groups: * vs Cows with foot lesions (p<0.05)

Fig. 3. Mean values \pm standard deviation (\pm SD) of hind foot temperature in each area of interest (A1, central area; A2, interdigital area; A3, lateral claw; A4, medial claw) together with different percentage change (Δ) expressed in °C, and statistically significant differences found between healthy cows and in cows with foot lesions.

eases such as equine laminitis (Pollitt and Davies 1998) and foot rot in cattle (Rainwater-Lovett et al. 2009). Lameness in dairy cattle is a significant problem in intensive dairy industries around the world, causing production losses (Huxley 2013) and discomfort, undermining animal welfare (Whay et al. 1997). Achieving sustainable reductions in the levels of disease on farm requires a combination of two approaches: the implementation of effective farm-specific prevention strategies to decrease the rate at which new cases develop; early identification and prompt and effective treatment of clinical cases to reduce the duration of time over which animals are lame. For this purpose the use of IRT has a significant meaning because this technology is useful not only for assessing physiological responses to milking and feeding, as observed in dairy cattle (Montanholi et al. 2008) but also to identify lameness (Alsaad et al. 2015).

It has been reported that IRT was reliable in detecting elevated temperatures associated with foot lesions (Stokes et al. 2012). However, external factors such as the ambient temperature may influence the foot temperature affecting the reliability of IRT imaging. In the present study, all thermographic measurements were done within the neutral zone for dairy cattle (Roefeldt 1998) and in closed barns at a controlled ambient temperature, without exposure to any direct sunlight or detectable airflow. Moreover, it has been stated that dirt influences the reliability of thermography by affecting the surface's ability to radiate absorbed energy (emissivity) and to conduct heat (conductivity). Thoroughly cleaning cows' feet with water had a cooling effect (Stokes et al. 2012). In our study, all thermographic images were obtained after foot cleaning and drying and a five-minute timeout period was set to allow blood flow to return to its pre-wash state. The results obtained in the present study indicated that the temperature measured in the four selected regions of foot showed different values both in cows affected by foot diseases than in healthy cows. In particular, higher amount of infrared radiation, indicative of temperature, was emitted from the central and the interdigital areas of hind foot than from the lateral and medial claw in the hind foot. This could be due not only to the different vascularization and tissue metabolic activity of the foot regions, but also, and probably more importantly, to the amount of keratinization, which may be associated to the lower temperatures found in the sole regions (Rodríguez et al. 2016).

Cows affected by foot diseases showed higher temperatures at each considered foot region compared to foot of cows without diseases. In particular, the temperature of central and interdigital areas of hind foot of diseased cows showed an increase of 7.25% and 6.50%, respectively, in respect to the healthy cows, whereas the

foot temperature of lateral and medial claw in the hind foot of diseased cows showed an increase of 9.63% and 10.31% in comparison to the healthy cows. Our findings agree with previous studies carried out on cows affected by hoof diseases reporting higher temperatures in cows with hoof diseases compared to healthy cows (Nikkhah et al. 2005, Alsaad and Büscher 2012). Inflammation or infectious conditions usually lead to an increase in the underlying circulation and tissue metabolic rate (Alsaad et al. 2014) resulting in a localised increase in the surface temperature of the affected areas (Stewart et al. 2007). Therefore, the variation in superficial thermal patterns resulting from changes in blood flow will alter the amount of radiated heat that may be easily identified by thermography and may relate to the inflammation of tissues underlying that point or to changes in metabolic activity (Purohit et al. 1985). Although thermography may not always provide specific pathology detail, it assists in defining the localization area of increased inflammation and/or injury (Alsaad et al. 2015) and it would be useful for podologists to act directly on the lesion detected by thermography and not the entire foot.

Conclusions

Early detection of foot diseases is likely to be valuable in the prevention of further progression and in early effective treatment. Foot diseases including white line lesion, sole ulcer, sole haemorrhage, horizontal fissure and axial fissure caused an increase of foot temperature compared to foot without lesions, as measured by thermography. An explanation for these findings is that the inflammation response in the case of foot lesions is associated with increased blood flow and tissue metabolism rate leading to a localised increase in surface temperature that can be detected by thermography.

This study highlights the potential of infrared thermography as a reliable, practical tool for detection of hoof lesions in dairy cows. In this aspect, multiple scanning images and comparisons between affected and healthy anatomical structures could be useful in defining the consistency of an abnormality. Thermography recording could allow to orchestrate lameness mitigation plans to successfully prevent, control, and manage foot lesions to enhance overall dairy performance and animal well-being within each farm.

Acknowledgements

The research was funded by University of Padua, CPDA134009/13.

References

- Alsaad M, Büscher W (2012) Detection of hoof lesions using digital infrared thermography in dairy cows. *J Dairy Sci* 95: 735-742.
- Alsaad M, Schaefer AL, Büscher W, Steiner A (2015) The role of infrared thermography as a non-invasive tool for the detection of lameness in cattle. *Sensors (Basel)* 15: 14513-14525.
- Alsaad M, Syring C, Dietrich J, Doherr MG, Gujan T, Steiner A (2014) A field trial of infrared thermography as a non-invasive diagnostic tool for early detection of digital dermatitis in dairy cows. *Vet J* 199: 281-285.
- Barkema HW, Westrik JD, van Keulen KAS, Schukken YH, Brand A (1994) The effects of lameness on reproductive performance, milk production and culling in Dutch dairy farms. *Prev Vet Med* 20: 249-259.
- Bortolami A, Fiore E, Giancesella M, Corrà M, Catania M, Morgante M (2015) Evaluation of the udder health status in subclinical mastitis affected dairy cows through bacteriological culture, somatic cell count and thermographic imaging. *Pol J Vet Sci* 18: 799-805.
- Brujnis MR, Beerda B, Hogeveen H, Stassen EN (2012) Assessing the welfare impact of foot disorders in dairy cattle by a modeling approach. *Animal* 6: 962-970.
- Chapinal N, de Passillé AM, Weary DM, von Keyserlingk MA, Rushen J (2009) Using gait score, walking speed, and lying behavior to detect hoof lesions in dairy cows. *J Dairy Sci* 92: 4365-4374.
- Cramer G, Lissemore KD, Guard CL, Leslie KE, Kelton DF (2009) The association between foot lesions and culling risk in Ontario Holstein cows. *J Dairy Sci* 92: 2572-2579.
- de Almeida GLP, Pandorfi H, Baptista F, Guiselini C, Barnabé JMC (2016) Thermal efficiency of individual shelters for girolando calves in Brazilian semi-arid regions. *Eng Agríc* 36: 13-23.
- Egger-Danner C, Nielsen P, Fiedler A, Müller K, Fjeldaa T, Döpfer D, Daniel V, Bergsten C, Cramer G, Christen AM, Stock KF, Thomas G, Holzhauser M, Steiner A, Clarke J, Capión N, Charfeddine N, Pryce JE, Oakes E, Burgstaller J, Heringstad B, Ødegård C, Kofler J (2015) ICAR Claw Health Atlas, 1st ed., ICAR, Rome.
- Ettema JF, Ostergaard S (2006) Economic decision making on prevention and control of clinical lameness in Danish dairy herds. *Livest Sci* 102: 92-106.
- Garbarino EJ, Hernandez JA, Shearer JK, Risco CA, Thatcher WW (2004) Effect of lameness on ovarian activity in postpartum Holstein cows. *J Dairy Sci* 87: 4123-4131.
- Godyń D, Herbut E, Walczak J (2013) Infrared thermography as a method for evaluating the welfare of animals subjected to invasive procedures - a review. *Ann Anim Sci* 13: 423-434.
- Green LE, Hedges VJ, Schukken YH, Blowey RW, Packington AJ (2002) The impact of clinical lameness on the milk yield of dairy cows. *J Dairy Sci* 85: 2250-2256.
- Hernandez J, Shearer JK, Webb DW (2002) Effect of lameness on milk yield in dairy cows. *J Am Vet Med Assoc* 220: 640-644.
- Huxley JN (2013) Impact of lameness and claw lesions in cows on health and production. *Livest Sci* 156: 64-70.
- International Lameness Committee (2008) Dairy claw lesion identification. In: Savonia University of Applied Sciences (ed) The 15th International Symposium & the 7th Conference on Lameness in Ruminants: Kuopio, Finland 9-13 June, 2008: proceedings. Savonia-ammattikorkeakoulun julkaisusarja, Kuopio.
- Manske T, Hultgren J, Bergsten C (2002) Prevalence and interrelationships of hoof lesions and lameness in Swedish dairy cows. *Prev Vet Med* 54: 247-263.
- Martello LS, da Luz E Silva S, da Costa Gomes R, da Silva Corte RR, Leme PR (2016) Infrared thermography as a tool to evaluate body surface temperature and its relationship with feed efficiency in Bos indicus cattle in tropical conditions. *Int J Biometeorol* 60: 173-181.
- Montanholi YR, Odongo NE, Swanson KC, Schenkel FS, McBride BW, Miller SP (2008) Application of infrared thermography as an indicator of heat and methane production and its use in the study of skin temperature in response to physiological events in dairy cattle (*Bos taurus*). *J Therm Biol* 33: 468-475.
- Murray RD, Downham DY, Clarkson MJ, Faull WB, Hughes JW, Manson FJ, Merritt JB, Russell WB, Sutherst JE, Ward WR (1996) Epidemiology of lameness in dairy cattle: description and analysis of foot lesions. *Vet Rec* 138: 586-591.
- Nikkhah A, Plaizier JC, Einarson MS, Berry RJ, Scott SL, Kennedy AD (2005) Short communication: infrared thermography and visual examination of hooves of dairy cows in two stages of lactation. *J Dairy Sci* 88: 2749-2753.
- Perazzi A, Iacopetti I, Stelletta C, Fiore E (2016) Bilateral glaucoma in a Tibetan goat: clinical and thermographic findings. *Large Anim Rev* 22: 281-283.
- Pollitt CC, Davies CT (1998) Equine laminitis: its development coincides with increased sublamellar blood flow. *Equine Vet J Suppl* 26: 125-132.
- Potterton SL, Bell NJ, Whay HR, Berry EA, Atkinson OC, Dean RS, Main DC, Huxley JN (2012) A descriptive review of the peer and non-peer reviewed literature on the treatment and prevention of foot lameness in cattle published between 2000 and 2011. *Vet J* 193: 612-616.
- Purohit RC, Hudson RS, Riddell MG, Carson RL, Wolfe DF, Walker DF (1985) Thermography of the bovine scrotum. *Am J Vet Res* 46: 2388-2392.
- Rainwater-Lovett K, Pacheco JM, Packer C, Rodriguez LL (2009) Detection of foot-and-mouth disease virus infected cattle using infrared thermography. *Vet J* 180: 317-324.
- Rodríguez AR, Olivares FJ, Descouvrieres PT, Werner MP, Tadich NA, Bustamante HA (2016) Thermographic assessment of hoof temperature in dairy cows with different mobility scores. *Livest Sci* 184: 92-96.
- Roefeldt S (1998) You can't afford to ignore heat stress. *Dairy Manage* 35: 6-12.
- Rowlands GJ, Lucey S (1986) Changes in milk yield in dairy cows associated with metabolic and reproductive disease and lameness. *Prev Vet Med* 4: 205-221.
- Salles MS, da Silva SC, Salles FA, Roma LC Jr, El Faro L, Bustos Mac Lean PA, Lins de Oliveira CE, Martello LS (2016) Mapping the body surface temperature of cattle by infrared thermography. *J Therm Biol* 62: 63-69.
- Schrank M, Bonsembiante F, Fiore E, Bellini L, Zamboni C, Zappulli VEG, Stelletta C, Mollo A, (2017) Diagnostic approach to fibrocystic mastopathy in a goat: thermographic, ultrasonographic, and histological findings. *Large Anim Rev* 23: 33-37.

- Shearer J, Van Amstel S (2013) *Manual of Foot Care in Cattle*, 2nd ed., Hoard & Sons Company, Fort Atkinson.
- Stelletta C, Giansella M, Vencato J, Fiore E, Morgante M (2012) Thermographic applications in veterinary medicine. In: Prakash RV (ed) *Infrared Thermography*. In Tech, China, pp. 117-140.
- Stewart M, Webster JR, Verkerk GA, Schaefer AL, Colyn JJ, Stafford KJ (2007) Non-invasive measurement of stress in dairy cows using infrared thermography. *Physiol Behav* 92: 520-525.
- Stokes JE, Leach KA, Main DC, Whay HR (2012) An investigation into the use of infrared thermography (IRT) as a rapid diagnostic tool for foot lesions in dairy cattle. *Vet J* 193: 674-678.
- Talukder S, Gabai G, Celi P (2015) The use of digital infrared thermography and measurement of oxidative stress biomarkers as tools to diagnose foot lesions in sheep. *Small Rumin Res* 127: 80-85.
- Toussaint Raven E (1989) *Cattle footcare and claw trimming*. Farming Press, Ipswich.
- Warnick LD, Janssen D, Guard CL, Gröhn YT (2001) The effects of lameness on milk production in dairy cows. *J Dairy Sci* 84: 1988-1997.
- Whay HR, Waterman AE, Webster AJ (1997) Associations between locomotion, claw lesions and nociceptive threshold in dairy heifers during the peri-partum period. *Vet J* 154: 155-161.

