

# We are IntechOpen, the world's leading publisher of Open Access books Built by scientists, for scientists

4,200

Open access books available

116,000

International authors and editors

125M

Downloads

Our authors are among the

154

Countries delivered to

TOP 1%

most cited scientists

12.2%

Contributors from top 500 universities



WEB OF SCIENCE™

Selection of our books indexed in the Book Citation Index  
in Web of Science™ Core Collection (BKCI)

Interested in publishing with us?  
Contact [book.department@intechopen.com](mailto:book.department@intechopen.com)

Numbers displayed above are based on latest data collected.  
For more information visit [www.intechopen.com](http://www.intechopen.com)



# Rhinoplasty in Context of Head and Neck Malignancy

*Norhafiza Mat Lazim, Giacomo Spinato  
and Paolo Boscolo Rizzo*

## Abstract

Head and neck tumors comprise of multiple epithelial and solid tumors which include nasal cavity and paranasal sinus tumors. Occasionally, the surgical treatment strategy incorporates rhinoplasty procedure in order to achieve better tumor control, preserve function, and attain better cosmetic outcomes. The rhinoplasty is mainly involved with the surgical procedures that intervene with the nasal structure in order to improve the function of the nose along with optimal cosmetic objective acquisition. Multiple surgical procedures and approaches have been introduced in the past decades in refining techniques of rhinoplasty, and it continues to evolve. Most of the times, the procedure is combined with usage of synthetic products, grafts, and biomaterials, in order to ascertain the best outcomes for each of these procedures. In the head and neck oncology arena, rhinoplasty is often performed in combination with other surgical procedures, and it is mainly to improve patient's nasal and sinus functions and cosmesis as well as to enhance quality of life of any given head and neck patients.

**Keywords:** rhinoplasty, head and neck tumors, surgical oncology, nasal cavity and paranasal sinus tumors

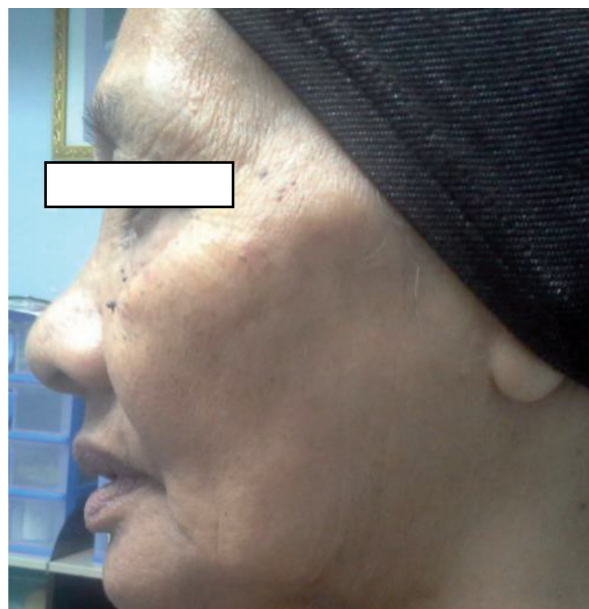## 1. Introduction

Head and neck cancer treatment almost always involves some surgical excision of the vital vascularized tissues. In the head and neck region especially, tissue resection will produce significant scarring and esthetic impairment apart from its impact on patient function such as speech, swallowing, breathing, and mastication. In the head and neck surgery, rhinoplasty continues to be among the most popular esthetic surgical treatments at the majority of ear, nose, and throat (ENT) center around the world. This is in fact a reflection of the significance of nose shapes in sociocultural, ethnic, and psychological contexts in the community. In addition and importantly, the nose as a Goldfarb et part of anterior facial skeleton is exposed to multiple insults mainly the trauma, as well as tumors with consequent bony and soft tissue injuries that can have detrimental effects on its sufferers.

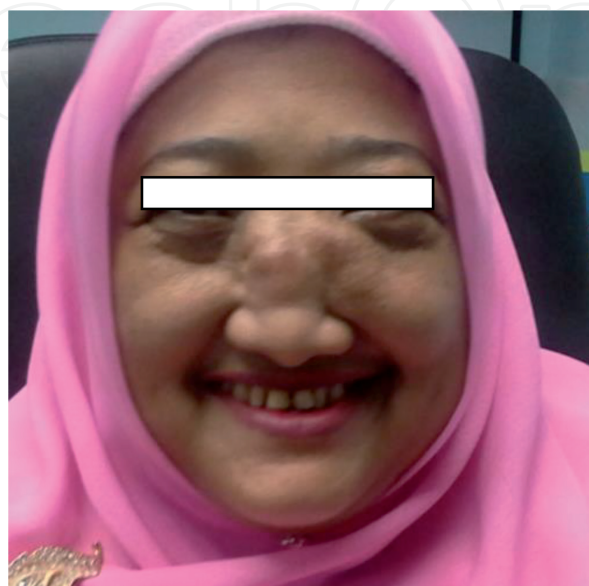
Rhinoplasty is a common plastic surgery addressing the anatomical deformity of the nose and aimed at improving nasal function especially the breathing function. It is almost always combined with septoplasty that addresses the nasal septal deviation. There are several indications for septoplasty which include a humpy nose. In order to

perform a safe rhinoplasty procedure, a sound knowledge about the nasal anatomy, paranasal sinuses, and its surrounding structures is a must. Treating surgeons and involved team need to be able to know the detail structures of the nasal cavity especially the cartilaginous framework, vascular blood, and neural supply and detail anatomy of facial skeleton as well as the adjacent maxillary and ethmoid sinus structures.

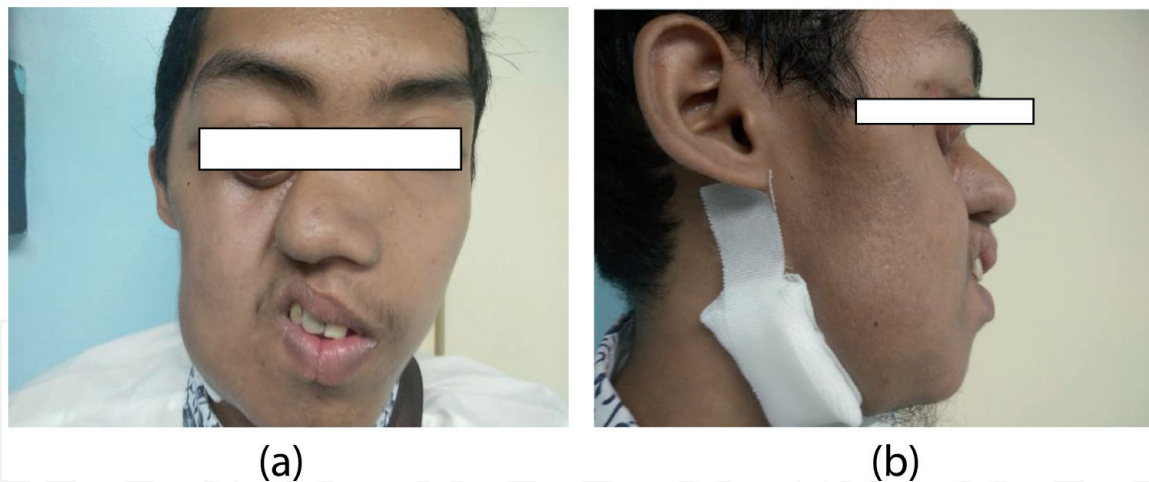Some of the procedures that were used in esthetic rhinoplasty may also be used in combination with reconstructive nasal surgery in order to achieve free surgical margin or safety margin but, at the same time, to achieve an acceptable esthetic and functional outcome. The goal of any nasal reconstruction surgery is to restore normal nasal shape and function. The essence of nasal reconstruction surgery begins with creating a stable framework. In addition, similar with any other surgical procedures, rhinoplasty carries several significant complications ranging from bleeding, infectious, traumatic, functional, and aesthetic complications (**Figures 1–3**).



**Figure 1.**  
*Lateral projection of the nasal framework.*



**Figure 2.**  
*Anterior profile of the nose with tumor on the nasal bridge.*



**Figure 3.**  
(a, b): Complications from tumor and its treatment.

## 2. Anatomical profile of the nose

## 3. Types of rhinoplasty and its procedure

Over the centuries many anatomists, physiologists, physicists, and surgeons have contributed to the development of rhinoplasty knowledge and techniques. Historically, nasal surgery underwent more development over the years as the nose was frequently the target of mutilation in war conflicts. The first documented case is dated around the year 1000 AD, where *Sushruta*, father of Indian surgery, performed a reconstruction of a mutilated nasal pyramid using pedicle flaps from the cheek and forehead. Several of Indian surgical techniques following the Arab expansion were widespread in the West. They were introduced in Italy first in the mid-1400s and subsequently in the whole Europe [1]. In 1579, Gaspare Tagliacozzi of Bologna described in the *De Curtorum Chirurgia per Insitionem* the reconstruction of the nasal pyramid through the pedicle skin flap of the forearm [2]. In 1881, Karl von Grafe of Berlin coined the term “rhinoplastik” by comparing and describing the various surgical techniques in Europe. It was however because of the development of the front mirror in 1845 and to the introduction of the anterior and posterior rhinoscopy that the physics of air flow was applied to the surgery of the septum. In 1847, P. Heylen first described a septal resection after bilateral dissection of the mucosa, and later Gustav Killian in 1899 modified this technique to prevent the sagging and retraction of the nose [1].

In reconstructive rhinoplasty, it is important to associate the best esthetic result with an efficient airway patency in order to improve quality of life and surgical success. To plan an effective rhinoplasty even under the functional aspect, it is necessary to mention some principles of physiology of the nasal cavity. According to the Bernoulli principle, the inspired air velocity increases in speed in the narrower nasal regions such as the nasal valve or the head of the turbinates, where there is considerable air resistance and where the laminar airflow can increase so as to exceed the number of Reynolds creating vortices [3]. Furthermore, an increase of speed at the level of the constrictions can lead to a decrease in the air pressure to be negative and generate an inspiratory collapse at the level of the lateral nasal wall based on the Venturi effect. These principles of physics, applied to the physiology of nasal breathing, are the basis of functional success in reconstructive rhinoplasty [4]. There is no absolute standard for esthetic proportion of the face. This differs depending on sex, age, body type, and facial characteristics. The female nose is



relatively smaller, the dorsum and lobule narrower, than that of the male. In profile, the female dorsum may show a slight concavity, while in the male dorsum, a slight convexity is acceptable. All of these cofactors will influence the final design and approach for the rhinoplasty procedures [5].

The nasolabial angle should be less acute in osteotomy, and formation of the tip after the underlying bony or cartilaginous framework, or both, had been removed. The resulting open-roof deformity had to be corrected by osteotomy of the bony nasal wall and the tip shaped by excision and suturing, including insertion of the tip graft and columellar strut graft. After this, and narrowing of the nose, the defect was smaller and could be closed with local tissue without tension. There were no deformities in the contour, and patency of the airway was maintained. Although the margin of safety was increased, shaping the nasal framework reduced the size of the defect, which allowed tension-free closure with a local flap. The function is guaranteed by trying to recreate the normal anatomy [6, 7]. To obtain a correct morphological and functional rhinoplasty, the procedure may involve different techniques and approaches. The various techniques involve the modification and reconstruction of various nasal subassemblies which are septal, nasal pyramid, nasal vestibule, tip, and turbinate surgery. The sequence of surgical times in reconstructive morpho-functional surgery must bear in mind the pathology and the patient's history and the surgical purposes [8, 9].

Correction of the nasal septum is the basis of functional reconstructive surgery. A septal alteration is the main cause of nasal dysventilation and a cause of deformity of the osteocartilaginous pyramid. The sequence of surgical steps depends primarily whether the endonasal or open surgical approach is used. The endonasal approach involves the mobilization and repositioning of the septum, followed by the correction of the bone pyramid and cartilage with possible osteotomies and additional stabilization surgery of the septum, and finally the modification of the wing of the nose according to the esthetics of the new pyramid. The open approach on the other hand requires the exposure of the wing structures of the nose and the vestibule and of the cartilaginous spine with the mobilization and the repositioning of the septum and the correction of the osteocartilaginous pyramid for the reconstruction of the structure with the modification of the nasal wing [10–12].

The septal reconstructive approach is mostly endonasal. The septum is approached by subperichondrial and subperiosteal dissection, and irreversibly deviating portions are resected. Subsequently, the skin of the osteocartilaginous pyramid is detached by means of a bilateral intercartilaginous incision. Correction of the cartilaginous osteopyramid and possible repositioning depend on the pathology. If appropriate, osteotomies are performed in combination with the monolateral or bilateral wedge resection of the pyramid with its repositioning on the midline. As a last phase of intervention, the nasal wings are harmonized and corrected according to the pathology and the preference of the surgeon. In the external approach, an inverted trans-columellar V incision and a bilateral intra-cartilaginous incision are performed [13, 14]. The skin is detached from medial crura, dome, and lateral crura. The caudal end of the septum is exposed to the cartilaginous spine. Septal subperichondrial dissection and possible chondrocyte and deviated septal removals are performed. Pyramid plastic and a modification of the nasal valve are similar to endonasal surgery. To correct a deformity of the nasal bone or cartilaginous pyramid, it is possible to perform different procedures such as the repositioning of the anterior septum; the narrowing and push-up of the bone pyramid after osteotomy; the enlargement of the pyramid by inserting a dorsal transplant of septal cartilage, auricular or costal; the increase of the lobular projection; and the narrowing of the lobule itself or the lengthening or lowering of the columella [15–18].

In the case of reconstructions of large defects, it is necessary to use an implant. An ideal transplant must be well-tolerated, without causing any pathologies, not showing any signs of absorption or rejection or altering over time. In literature there are many types of implants and materials utilized over the years. In the nineteenth century, there was an extensive use of gold and silver in the reconstruction of the nose, subsequently using ivory cellulose paraffin and in the 1900s stainless steel. Biological tissues included processed allogeneic or autogenous tissues such as the iliac crest, the tibia, and the auricular costal cartilage. The main disadvantage of biologics is the tendency to reabsorb and deform. The use of non-biological implants instead guarantees the advantages of easy availability; however, if they are not integrated into the nasal tissues, they can lead to possible short- or long-term infections or rejection. Immunological reactions, tissue migration, and carcinogenesis are also described [11, 16, 19–21].

#### **4. Reconstruction technique for rhinoplasty**

Proper treatment planning is essential for providing the patient with the best chance of cure and an optimal esthetic outcome. The treatment plan has to be discussed with the patient and immediate relative members in order to ensure their understanding about the whole surgical process and to meet with their expectations. In addition, this is also vital to highlight the expected complications that can arise from the procedures, in order to avoid a cumbersome litigation cases.

The nasal framework is a vital component to be addressed during any rhinoplasty. Regardless of flap used, the supporting structure was the most critical element for the three-dimensional shape of the reconstructed nose. As one of the three elements of nasal reconstruction, frameworks deserve adequate attention during such reconstruction process.

Several approaches have been advocated to decrease postoperative edema and ecchymosis such as performing lateral osteotomies with an angulated saw through an intercartilaginous incision. This technique has been widely described. Other techniques include a modification of Diamond's perforating osteotomy technique, using a 4-mm osteotome, resulting in milder ecchymosis and edema, which was described by Goldfarb et al, as stated in Tahamiler, 2008. Other small techniques but effective are placing drains in the lateral osteotomy incisions allowing blood and serum to escape from the area and reducing the ecchymosis in the periorbital area [22].

Dorsal augmentation is a challenging task for rhinoplasty surgeons in Asia because the required amount of augmentation is frequently substantial. Autologous materials, such as rib cartilages, diced cartilages wrapped in fascia, and dermis or dermofat grafts, are used for dorsal augmentation by many Asian surgeons. Silicone augmentation, however, is still the dominant practice in Asian countries. Alloplastic implants have advantages over autologous materials, such as ease of use, unlimited supply of volume, less invasive nature of the procedure, and incomparably superior esthetic outcomes [23].

There are some technical difficulties and nuances in Asian rhinoplasty; techniques that are highly successful in Caucasian noses are frequently insufficient or unsatisfactory in Asians. Small lower lateral cartilages with short medial crura covered with thick skin make sculpting or suturing tip difficult in Asian population [23].

The use of rib cartilage is related to chest scarring, possible pneumothorax, prolonged operation time, and high emotional or economic burden on the patient. The rigid immobile tip of rib cartilage is often odd and unpleasing. Also, rib cartilage is

not immune to complications. Warping and resorption are frequent, and although infection is uncommon, it is possible. Because of its solid nature, it may get fractured with trauma more easily than elastic alloplastic implants. In this regard, rib cartilages are reserved as a last resort rather than as a primary choice for primary esthetic rhinoplasty by many surgeons. The use of rib cartilage in a primary esthetic rhinoplasty should be evaluated carefully on the benefits and costs, patient's comfort level, and possibility of overtreatment [23].

Ideally, the proposed lateral osteotomy pathway should be injected with 1% lidocaine and 1:100,000 epinephrine at least 15 minutes before creating the bony cuts. This will provide a reduction in ecchymosis and bleeding associated with trauma of fracture. Another important consideration is to preserve as much of the periosteum as possible. In the case of lateral osteotomy, this is especially important. Micro-osteotomy using a 2-mm, V-shaped osteotome is recommended because it provides minimal laceration, bleeding, and scarring of the periosteum and subcutaneous tissue. During the course of a lateral osteotomy, the osteotome might accidentally slide sideways, damaging the angular vessels and causing more edema and ecchymosis. The 2-mm, V-shaped osteotome is inserted through the soft tissue to the bone at the piriform aperture. After proceeding cephalically, the osteotome does not slide sideways but glides through the bone where it meets the medial oblique osteotomy [22].

The L-shaped silicone implant has been widely used in Asian countries. One of the major advantages of this silicone implant is a smooth and uninterrupted nasal dorsal contour from radix to nasal tip. With the L-shaped silicone implant, augmentation of both the nasal dorsum and the tip is accomplished concurrently without complicated tip procedures. The L-shaped silicone may be an attractive choice for Asian patients because of extreme difficulties of tip plasty in the Asian patient with weak septum, small and weak cartilaginous framework with short medial crura, and thick soft tissue envelope [23].

## **5. Complications of rhinoplasty**

The knowledge of complications in rhinoplasty and nasal reconstruction techniques is fundamental to avoid their formation and also to manage the origin of the complications themselves. Postoperative deformities and breathing dysfunction are the most common complications in rhinoplasty. Tahamiler et al. described additional complications including injury to the lacrimal apparatus resulting in epiphora, the "rocker" phenomenon, the "staircase" phenomenon, hematoma, edema, and ecchymosis secondary to the trauma of osteotomy. Several of these complications were also associated to lateral osteotomies [22].

Many complications could be avoided with a thorough preoperative analysis, in-depth preoperative discussion with the patient, good vasoconstriction, and conservative surgery with possible and careful postoperative monitoring. Some authors recommend not only recording the patient's physical examination and medical history but also discussing the case with the patient himself. This collection will have a fundamental value for any subsequent medical-legal problems [24]. Trying to reconstruct a normal anatomy instead of creating a new anatomy for the patient and to consider a second operation in case of important interventions is crucial in any rhinoplasty case. In general, meticulous attention to detail in the operating room and in the postoperative period is paramount in order to attain success in rhinoplasty. Nevertheless, both complications and suboptimal results do occur even in experienced hands [4, 6].



Among these complications, it is well known that postoperative edema and ecchymosis have been a persistent problem since the advent of rhinoplasty surgery. Periorbital swelling and discoloration are the most distressing to the patients who 24 hours postoperatively may have difficulty with vision because of the edema and is quite self-conscious about esthetic appearance. In a standard rhinoplasty operation, lateral osteotomies are responsible for a significant amount of periorbital swelling and ecchymosis because of the injury of the angular vessels that cross the osteotomy sites and the trauma of infracturing [24]. Complications can be mainly distinguished in cutaneous, infections, intranasal complications, incision complications, hematomas, complications of osteotomies, complications of wing surgery, and complication of transplants. We will venture to examine each of these elements [3, 8, 10, 25].

Skin complications may be linked to cutaneous ischemia due to inadequate skin dissection or due to excessive implant placement or incorrect postoperative bandage. The treatment is to keep a surface as clean and dry as possible in order to prevent infections and possible planning of a revision surgery if the alteration remains conspicuous [20]. Adverse reactions to sutures can cause reactive granulomas and impaired scarring. In case of repeated interventions, telangiectasias can form on the skin of the nasal bridge, and the therapy is cosmetic or in some cases laser. Depending on the type of reconstruction and the choice of the donor flap, skin discoloration may occur. The complications associated with incision design can lead to external scars with serious esthetic consequences, while the internal ones can create important respiratory constructions. The alterations of surgical incisions may depend on the type and number of incisions made, on the inadequate suture of the incisions, on the poor postsurgical control, and on scar infections [16, 26–28].

A very frequent complication after nasal surgery is the nasal and orbital hematomas and ecchymoses. Important in the postsurgery is the evaluation of possible septal hematomas, which, if present, must be drained immediately, and the septal mucosa must be promptly repositioned. To prevent dorsal hematomas, it is important to perform a good, moderately compressive bandage.

Among the infectious complications, there is rhinosinusitis, septal abscess, dorsal abscess, and implant or transplant infection. The abscesses must be promptly drained, while the infection of non-biological implant involves the removal of the same. In case of biological transplant, it is possible to try to conserve it with appropriate intravenous antibiotic therapy [29, 30].

The most common intranasal complications are the synechiae, often asymptomatic. Prevention of synechiae is the placement of a split that prevents contact between the septal mucosa and the side wall. The treatment of the synechiae is the resection of the same after local anesthesia. Septum perforations can cause a variety of complications such as epistaxis crusts, inspiratory whistling, nasal obstruction, and nasal pain. Septal perforations are described with an incidence of between 0.5 and 1% in the hands of skilled surgeons. The most frequent cause of septal perforation is iatrogenic damage, endonasal digital traumatism, bilateral acid burn due to epistaxis, a trauma, cocaine abuse, abscess of the septum, and granulomatous diseases. The anterior and central perforations generally produce more symptoms, while the posterior and basal defects are more elaborate to resolve. The best therapy for septal perforation and prevention ensuring good illumination, a bloodless surgical field, and sufficient surgical exposure is to execute a detachment of the septal mucosa at the subperichondrial level along the correct plane using delicate instruments [31–33].

In the event of a septal laceration, it is important to immediately treat it with stitches if possible.



Therapeutic options for postsurgical septal perforation may be a conservative treatment in the case of an asymptomatic patient, possibly with application of ointments to reduce crusting. Surgical closure of perforation is the best therapeutic option. The success rate of the various techniques can vary depending on the diameter of the perforation. The variables for surgical success are the position and the shape of the perforation, the quality of the Moon margins, and, thus, the presence or absence of cartilage around the defect. In cases of small perforation, a direct closure can be performed by mobilizing and freshening the margins. For wider perforations, rotational flaps or other parts of the septum or nasal floor must be used. Some authors describe the gingival hole flap for large anterior perforations. The septal obturator can be used in case of recurrence of perforation after surgical failure or after extensive demolition in neoplastic patients. Among other complications of septal surgery, there may be sagging of the cartilaginous back which occurs when a high percentage of cartilaginous septum is removed. It can often be associated with retraction of the columella [3, 8, 29].

Among the complications of osteotomies may be an excessive fracture of the sidewall of the bone pyramid which causes esthetic and functional disorders. In order to prevent this complication, an external bandage is important, and the use of glasses in the postoperative period is avoided; in the case of nasal obstruction, the only therapy is surgery. In addition, there may be recurrences of deviations and asymmetries in the event of complete mobilization of the nasal bones or of the septum or in and of the observed detachment of the cutaneous surface or in adequate postoperative protection. In case of resections of osteocartilaginous gibbositities, the open-roof complication can occur [30, 31].

Among the alterations of the nasal wings, there may be the excessive restriction of the lateral crus margin caused by a maneuver to thin the tip or a depressed and flaccid area that can collapse during inspiration with obstruction of the vestibule. With regard to the complications of grafts and implants, these may be mostly occurring late. The most common of the immediate ones are infection, dislocation, and rejection of the graft. To prevent infection, it is important to minimize the risk of ischemia of the skin overlying the transplant and prevent the blood accumulation in the pocket for transplantation with bandages and provide adequate antibiotic coverage. In the event of severe nasal pain and fever, the action patch and any pus secretion from the wound must be removed. The dislocation of the implant can be caused by incorrect positioning or dimensions and insufficient fixation. The use of cartilage as an implant has the highest complication in resorption. In case of infection not treated for a long time, the implant can be extruded. A minimal trauma or infection can be the cause of the expansion of the non-biological implant [33, 34].

## **6. Application in head and neck malignancy**

In head and neck oncology, the free surgical margin is vital in order to prevent any local recurrence and distant metastasis. In the facial region, the bigger the resection, the greater is the defect which consequently causes significant cosmesis embarrassment. Thus, preoperative discussion should be conducted with all team involved in order to come to a consensus for an optimal tumor resection with good margin and thus cause less defect and reconstruction requirement.

An exemplary case includes a 66-year-old lady with history of cystic adenoid mucosal carcinoma of the right nasal septum who had local recurrence staged as T2N0M0 and requires a large nasal excision with amputation of the septum and bony parts of the nose from anterior part to triangular cartilages. In this case the reconstruction was performed in three planes: a musculocutaneous frontal flap

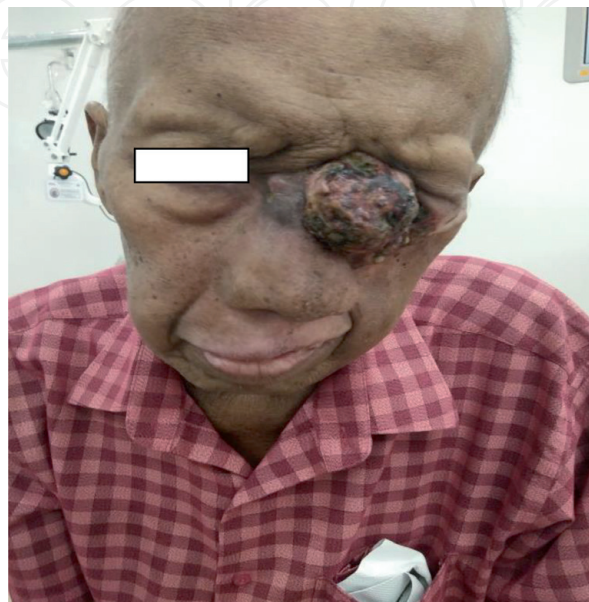for the mucosal plane, a titanium plate for the bone plane, and the nasal skin for the cutaneous plane. Surgical revision with a glabellar flap coverage associated with lipotyping time in unexposed areas improved soft tissue trophicity. Two sessions of complementary lipo-modelings made it possible to obtain a very good and stable coverage. The author concluded that from the oncology point of view, the result is good and no recurrence has been demonstrated with a decline of 10 years and from an esthetic and functional point of view, the results were considered very satisfactory [35].

Skin cancer is an aggressive tumor with high rate of local recurrence. Inadequate treatment will lead to subtotal or total nasal amputation and high morbidity. Basal cell carcinoma (BCC) is the commonest skin type, and the majority is located within the head and neck region where the sun exposure is at the highest. Nearly 90% of cases of BCC is found on the facial region with 30% of cases affecting the nose. Exemplary case is shown in **Photo 1**.

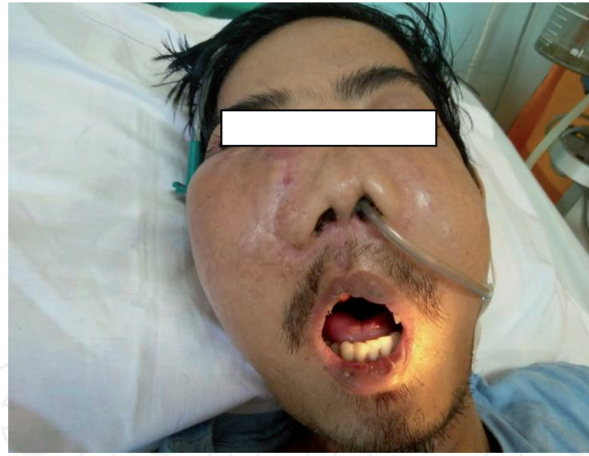Squamous cell carcinoma on the other hand shows predilection for node metastases. At presentation regional neck nodes are found in 10% of cases. The presence of neck node metastases has major influence on the final outcomes of the diseases. The treatment of this type of tumor involves wide local resection of the tumor in combination with therapeutic neck dissection and/or parotidectomy. **Photo 2** showed a patient with squamous cell carcinoma of the right maxillary sinus with nasal cavity involvement.

The anatomical subsites of the nose that are commonly involved are the ala, nasal tip, lateral nose wall, and nasal dorsum. Primary reconstruction of skin cancer defects is safe in most cases with proper patient selection and reliable histopathological examination techniques. In a large, recurrent, or aggressive skin tumor, the reconstruction should be delayed until more certainty has been obtained than no tumor.

The skin resection defect can be reconstructed and repaired by a variety of techniques which include local skin flaps, septal graft and auricle cartilage, free grafts, and composite graft like skin plus cartilage of conchal. The choice of treatment like in any other type of cancer depends mainly on tumor localization and its extension. For BCC of the nose and nasal cavity, the best treatment option was a radical surgery with safety margin of tumor followed by reconstructive rhinoplasty. Reconstructive rhinoplasty can be done in a staged manner, where a specific procedure is planned at multiple dates, so as to lessen the surgical risk and be able to quantify the desired tissue repair.



**Photo 1.**  
*Basal cell carcinoma of nasal bridge with extension to the medial canthus of left eye.*



**Photo 2.**  
*Squamous cell carcinoma of right maxillary sinus with nasal cavity involvement.*

## 6.1 Revision rhinoplasty

Most of the nasal anatomy alterations found in patient undergoing revision rhinoplasty are challenging to treat, not only from the surgical perspectives but also from psychological point of view. The patients have high expectations and anxieties due to dissatisfaction with previous surgery and difficulty in understanding the limitation of the resurgery cases. In most cases, the need for revision rhinoplasty is the result of a poorly performed prior evaluation, inappropriate patient selection, failure to adequately explain about the limitations related to surgery to the patient, and limitations in performing the surgical maneuvers during the procedure [36].

To optimize patient satisfaction after a revision surgery, the surgeon must be aware of the esthetic and functional complaints reported by the patient, as well as perform a very detailed and objective nasal evaluation, to ensure that no alteration in nasal anatomy goes unnoticed and is amenable to be addressed by surgery. The surgeon must validate the patient's esthetic and functional complaints through a detailed external and internal evaluation of the nose [36].

Complications from revision rhinoplasty is numerous and is based on patient presentation and nasal endoscopy examination; specific complications can be elicited. According to Vian et al., a correlation between subjective obstructive symptoms and the intranasal assessment performed by surgeons was present in 87.5% of cases with one or more nasal obstructive symptoms. Among the patients with respiratory symptoms, the main deformity found was residual septal deviation (56.25%), followed by turbinate hypertrophy and synechiae, both observed in 28.5% of the patients, and the collapse of the internal nasal valve in 19.75% of patients with obstructive nasal complaints [36].

## 7. Advantages and disadvantages of rhinoplasty and its associated procedures

The advantage of reconstructive technique is to ensure at the oncological radicality good esthetic results with the creation of a new nasal lining, skeletal framework, and skin cover [14, 37]. Ensuring the best esthetic results considers the quality of life of the patients as a whole, initial tumor stage, and functional outcomes [38]. From the literature emerges that surgically reconstructed patients showed a high degree of self-confidence and that prosthetically fitted patients show a high degree of esthetic satisfaction [39]. However, there are no significant differences between



patients who received surgical reconstruction and those who received prosthetic rehabilitation after oncological resection.

Although nonsurgical treatment options such as radiotherapy or cryotherapy may be effectively used, surgery is the main treatment option for cancer of the nasal skin. Nasal reconstruction after skin cancer can be very demanding, especially if the patient's expectations are high. Careful assessment of the defect and thorough preoperative planning are as important to the final result as is the technical execution of the procedure [32, 40].

The objective of the reconstruction is not only closing the defect, but closing it appropriately with the optimal flap and in proper with the esthetic subunits. This is the most important point in reconstruction of the nose. During the planning of a nasal reconstruction of adjacent tissue characteristics, the presence of fixed structures and the donor skin area (color, thickness, and laxity) must be assessed. The location and three-dimensional extent of the tumor dictate the choices of repair or reconstruction as well as the timing thereof. Very small lesions can be excised with primary closure or secondary epithelization; other well circumscribed tumors can be excised and the defect closed with an appropriate full-thickness skin grafts and local flaps using one or two stages [33, 37].

Nasal subunits have distinct characteristics; thus, optimal reconstruction should be preferred for each subunit. Nasolabial, cheek, and midline forehead flaps are useful in a variety of instances but usually when less than one-half of the nose has been excised [16]. Advanced nasal skin tumors are not uncommon, and patients who have undergone extended total nasectomies according to many authors are best managed with a prosthesis, as prognosis is often guarded and flap reconstruction may be quite unsatisfactory [41].

For intermediate-sized defects, the choice of reconstruction is usually between skin flap and full-thickness skin graft. For defects on the nose where flap and graft repair may both be technically possible, a flap may be more likely to result in superior cosmetic outcome. Island flap used for ala and back nose reconstruction provides better functional and cosmetic results than the bilobed flap, from both functional and esthetic points of view, but some authors for resurfacing defects following excision of basal cell carcinomas prefer the technique of composite-skin grafting which involves the harvesting of composite-skin graft including the epidermis, dermis, and superficial layers of subcutaneous tissue to obtain the required thickness in the recipient site. The color, texture, and thickness of the composite-skin graft harvested from the preauricular site and the neck compare favorably with the skin of the nose region. Satisfactory results are obtained both clinically and in patient appreciation [15, 33, 42].

Extended resections of nose area require more complex reconstruction methods, including the use of cartilaginous grafts, bony grafts, local flaps, and free flaps [16]. The reconstruction of nasal bone, septum, and esthetically defined units of the nose always represents with certain difficulties. Titanium mesh has been employed as a bone replacement in diverse conditions. As cartilage grafts need a second surgical site, with consequent morbidity, the use of titanium mesh proves useful and safe in the reconstruction of nasal full-thickness defects [19, 37, 43]. In cases of extensive full-thickness resections, free flaps probably represent the most adequate option.

Microsurgical flaps have been proven to be reliable and effective in restoring the missing inner lining elements and adjacent substance losses in total or subtotal nasal reconstruction [16]. Combined with the frontal flap, this esthetic approach allows reconstruction of centropacial loss of substance layer by layer and facial unit per facial unit. Meticulous attention should be addressed in the artistic rendering of normal nasal dimensions in both size and proportion and form through the use of cartilage grafts and the use of final skin revisions. In addition these techniques help to restore the normal aerial sector [18, 44].



## **8. Future prospect**

Preservation of nasal function and the facial esthetics is a challenging task for every head and neck surgical oncologists as well as plastic reconstructive surgeons around the globe. As many as thousands of head and neck cancer patients, especially the nasal cavity and paranasal sinus cavity tumor, are diagnosed annually, which translates for a need of a better treatment approach and strategy for treating these subsets of head and neck oncology patient in order to maintain the best patients outcomes and improve patient's quality of life. At this juncture, the advancement in the technology and instrumentations has led new discovery and practices that can be implemented at a large scale in fine-tuning the better management protocol for all head and neck oncology patients.

## **9. Conclusion**

Reconstructive nasal surgery must take into consideration multiple factors which include surgeon and patient factors. In order to ensure an excellent quality of life of any treated patient, the surgery and procedure must also re-establish a good nose functionality, reconstructing the normal or near normal breathing, preserving the olfactory perception, and maintaining the ability of heating the breathed-in air. Lesions of the nose are the most challenging for the surgeon, because of the esthetic feature. It mainly aims at achieving good oncological outcomes with good esthetic results. The objective of the reconstruction is not only to fix the defect but to do it appropriately with an optimal flap with crucial consideration of the esthetic subunits. The most important stage of treatment is proper case selection for surgical treatment, selection of optimal reconstruction method that establishes radicalness of resection, and good esthetic and functional results. Many options exist to reconstruct nasal defects that lead to acceptable esthetic results, and at the same time, the surgical reconstruction and prosthetic rehabilitation are available in order to achieve better quality of life.

IntechOpen

## Author details

Norhafiza Mat Lazim<sup>1\*</sup>, Giacomo Spinato<sup>2,3</sup> and Paolo Boscolo Rizzo<sup>4</sup>

1 Otorhinolaryngology-Head and Neck Surgery Department, School of Medical Sciences, Universiti Sains Malaysia, Kelantan, Malaysia

2 Department of Neurosciences, Section of Otolaryngology and Regional Centre for Head and Neck Cancer, University of Padova, Treviso, Italy

3 Department of Surgery, Oncology and Gastroenterology, Section of Oncology and Immunology, Universiti of Padova, Padova, Italy

4 Department of Neurosciences, Ear, Nose and Throat, Clinic and Regional Center for Head and Neck Cancer, University of Padua, Treviso Provincial Hospital, Padua, Italy

\*Address all correspondence to: [norhafiza@usm.my](mailto:norhafiza@usm.my)

## IntechOpen

© 2019 The Author(s). Licensee IntechOpen. This chapter is distributed under the terms of the Creative Commons Attribution License (<http://creativecommons.org/licenses/by/3.0>), which permits unrestricted use, distribution, and reproduction in any medium, provided the original work is properly cited. 

## References

- [1] Apostolides PD. Ear Nose and Throat Diseases in Hippocrates. UCL Ear Institute Library historical collection. UCB Pharma; 1997
- [2] Spinato G, Boscolo Rizzo P, Tirelli G. History of otorhinolaryngology: From the times of Serenissima till today. In: 11th International SVO Conference on Head & Neck Cancer, Together with Memorial Sloan Kettering Cancer Center (New York) and Mayo Clinic (Scottsdale-Arizona) and GSTTC Gruppo Studi Tumori Testa Collo (Venezia)". Proceedings by Spinato G, Tirelli G, Spinato R. 2014. ISBN: 978-88-85164-39-0
- [3] Flanagan P, Eccles R. Spontaneous changes of unilateral nasal airflow in man. A re-examination of the 'nasal cycle'. *Acta Oto-Laryngologica*. 1997;**117**:590-595
- [4] Brunintjes TJD, van Olphen AF, Hillen B. Review of the functional anatomy of the nasal cartilages and muscles. *Rhinology*. 1996;**34**:66-74
- [5] Huzing EH. Incorrect terminology in nasal anatomy and surgery, suggestion for improvement. *Rhinology*. 2003;**41**:129-133
- [6] Stammberger H, Functional Endoscopic Sinus Surgery, the Messerkinger Technique, Mosby Inc; 2000. ISBN 0-941158-969
- [7] Rettinger G, O'Connell M. The nasal base in cleft lip rhinoplasty. *Facial Plastic Surgery*. 2002;**16**:165-178
- [8] Daniel RK. *Rhinoplasty: An Atlas of Surgical Techniques*. New York: Springer; 2002
- [9] Cenzi R. *Cranio-Maxillo-Facial Rigid Fixation. Clinical Experiences with a New Method*. EdiSES srl; 2005. ISBN: 88-7959-183-5
- [10] Mang WL. *Manual of Aesthetic Surgery*. Vol. I. New York-Berlin: Springer; 2002
- [11] Papel ID et al. *Facial Plastic and Reconstructive Surgery*. 2nd ed. Stuttgart-New York: Thieme; 2002
- [12] Serra A, Caltabiano R, Spinato G, Gallina S, Caruso S, Rapisarda V, et al. Expression pattern of estroprogestinic receptors in sinonasal inverted papilloma. *Oncotarget*. 2017;**8**(24):38962-38968. DOI: 10.18632/oncotarget.17161
- [13] Meyer R. *Secondary Rhinoplasty: Including Reconstruction of the Nose*. Springer; 2002
- [14] Chiummariello S, Del Torto G, Iera M, Alfano C. The use of local flaps in the one-step nose reconstruction after cancer resection. *Annali Italiani di Chirurgia*. 2013;84. pii: S2239253X13021233
- [15] Monarca C, Rizzo MI, Palmieri A, Fino P, Parisi P, Scuderi N. Island pedicle and bilobed flaps in ala and back nose reconstruction: A prospective comparative analysis. *Aesthetic Plastic Surgery*. 2012 Oct;**36**(5):1168-1174. DOI: 10.1007/s00266-012-9935-9
- [16] Bennett JE, Thurston JB. Cancer of the nose: Ablation and repair. *Clinics in Plastic Surgery*. 1976;**3**(3):461-469
- [17] Huizing EH, de Groot JAM. *Functional Reconstructive Nasal Surgery*. Verducci Ed. Thieme, second edition. 2006. ISBN 88-7620-736-8
- [18] Ayhan M, Gorgu M, Aytug Z, Karantinaci B, Yilmaz E. Comparison of aesthetic outcomes and morbidity of nasal reconstruction with forehead flaps and free flaps. *Microsurgery*. 2007;**27**(5):411-414

- [19] Grajek M, Maciejewski A, Szumniak R, Krakowczyk L. The use of three free flaps in the simultaneous reconstruction of the nose after extensive resection due to malignant cancer. *Polski Przegląd Chirurgiczny*. 2012;**84**(2):99-101. DOI: 10.2478/v10035-012-0016-1
- [20] Tyndorf M, Strzałka A, Kozakiewicz M. Skin cancer of the nose—Methods and results of surgical treatment. *Wiadomości Lekarskie*. 2016;**69**(2 Pt 2):228-232
- [21] Boscolo-Rizzo P, Tirelli G, Mantovani M, Baggio V, Lupato V, Spinato G, et al. Non-endemic locoregionally advanced nasopharyngeal carcinoma: Long-term outcome after induction plus concurrent chemoradiotherapy in everyday clinical practice. *European Archives of Oto-Rhino-Laryngology*. 2015;**272**(11):3491-3498. DOI: 10.1007/s00405-014-3369-8
- [22] Tahamiler R, Erisir F. Lateral osteotomies in rhinoplasty: A safer and less traumatic method. *Aesthetic Surgery Journal*. 2008;**28**(5):518-520
- [23] Kim IS. Augmentation rhinoplasty using silicon implants (review). *Facial Plastic Surgery Clinics of North America*. 2018;**26**(3):285-293
- [24] Spinato G, Cazzato G, Ferlito S, Tirelli G, Boscolo-Rizzo P, Da Mosto MC, et al. Therapeutical innovations and medical responsibility: What's new in otolaryngology. *Acta Medica Mediterranea*. 2018;**34**:307. DOI: 10.19193/0393-6384\_2018\_2\_49
- [25] Tirelli G, Gatto A, Spinato G, Tofanelli M. Surgical treatment of nasal polyposis: A comparison between cutting forceps and microdebrider. *American Journal of Rhinology & Allergy*. 2013;**27**(6):e202-e206. DOI: 10.2500/ajra.2013.27.3966
- [26] Grymer LF. The nasal septum and the development of the midface. *Rhinology*. 1997;**35**:6-10
- [27] Accles R. The nasal cycle in health and disease. *Clinical Otolaryngology*. 2000;**25**:461-467
- [28] Arredondo de Arreola G, Lopez Serna N, Hoyos Parra de R, Salin MA. Morphogenesis of lateral nasal wall from 6 to 36 weeks. *Otolaryngology and Head and Neck Surgery*. 1996;**114**:54-60
- [29] Jayarajan R. A combination flap for nasal defect reconstruction. *Annals of Plastic Surgery*. 2018;**81**(4):427-432. DOI: 10.1097/SAP.0000000000001483
- [30] Salmon PJ, El-Khayat RH. Bridge flap repair for central nasal dorsum defect. *The Australasian Journal of Dermatology*. 2018;**59**(4):328-329. DOI: 10.1111/ajd.12768. Epub 2018 January 23
- [31] Grieco MP, Bertozzi N, Grignaffini E, Raposio E. Nose defects reconstruction with the Zitelli bilobed flap. *Giornale Italiano di Dermatologia e Venereologia*. 2018;**153**(2):278-282. DOI: 10.23736/S0392-0488.17.05035-0
- [32] Zaoui K, Thielen HM, Plath M, Baumann I, Plinkert PK, Federspil PA. Quality of life after nasal cancer resection - surgical versus prosthetic rehabilitation. *Rhinology*. 2018. DOI: 10.4193/Rhin18.030
- [33] Herford AS, Zide MF. Reconstruction of superficial skin cancer defects of the nose. *Journal of Oral and Maxillofacial Surgery*. 2001;**59**(7):760-767
- [34] Carucci JA, Kolenik SA 3rd, Leffell DJ. Human cadaveric allograft for repair of nasal defects after extirpation of basal cell carcinoma by Mohs micrographic surgery. *Dermatologic Surgery* 2002. **28** (4):340-343.
- [35] Aimard R, Lalloue C, Ho Quoc C, Girodet D, Zrounba P, Delay E. Reconstruction of proximal nasal defect after deep carcinological resection, combining titate mesh



with fat grafting. *Annales de Chirurgie Plastique et Esthétique*. 2017;**62**(2):181-186. DOI: 10.1016/j.anplas.2016.10.002

[36] Vian HNK, Berger CAS, Barra DC, Perin AP. Revision rhinoplasty: Physician-patient aesthetic and functional evaluation. *Brazilian Journal of Otorhinolaryngology*. 2018;**84**(6):736-743

[37] Broin ES, Naidu ER, Neary P, Edwards G, McHugh M. Reconstruction of major nasal defects. *Irish Journal of Medical Science*. 1996;**165**(2):125-128

[38] Kline RM. Aesthetic reconstruction of the nose following skin cancer. *Clinics in Plastic Surgery*. 2004;**31**(1):93-111

[39] Jacobs MA, Christenson LJ, Weaver AL, Appert DL, Phillips PK, Roenigk RK, et al. Clinical outcome of cutaneous flaps versus full-thickness skin grafts after Mohs surgery on the nose. *Dermatologic Surgery*. 2010;**36**(1):23-30. DOI: 10.1111/j.1524-4725.2009.01360.x

[40] Kaya İ, Uslu M, Apaydın F. Defect reconstruction of the nose after surgery for nonmelanoma skin cancer: Our clinical experience. *Turkish Archives of Otorhinolaryngology*. 2017;**55**(3):111-118

[41] Gurunluoglu R, Shafiqhi M, Gardetto A, Piza-Katzer H. Composite skin grafts for basal cell carcinoma defects of the nose. *Aesthetic Plastic Surgery*. 2003;**27**(4):286-292. Review

[42] Cherubino M, Battaglia P, Turri-Zanoni M, et al. Medial femoral condyle free flap for nasal reconstruction: New technique for full-thickness nasal defects. *Plastic and Reconstructive Surgery. Global Open*. 2016;**4**(9):e855. DOI: 10.1097/GOX.0000000000000858

[43] Otero-Rivas MM, González-Sixto B, Alonso-Alonso T, Pérez-Bustillo A, Valladares-Narganes LM, Rodríguez-Prieto MÁ. Titanium mesh in reconstructive surgery of the nasal pyramid. Follow-up of our 11 initial cases. *International Journal of Dermatology*. 2015;**54**(8):961-965. DOI: 10.1111/ijd.12971

[44] Burget GC, Walton RL, B Mole (translation française). Complete aesthetic reconstruction of nose and adjacent facial units with optimized use of free flaps, cartilaginous grafts and forehead flap combinations. *Annales de Chirurgie Plastique et Esthétique*. 2009;**54**(6):497-522. DOI: 10.1016/j.anplas.2009.01.036