

# We are IntechOpen, the world's leading publisher of Open Access books Built by scientists, for scientists

4,200

Open access books available

116,000

International authors and editors

125M

Downloads

Our authors are among the

154

Countries delivered to

TOP 1%

most cited scientists

12.2%

Contributors from top 500 universities



WEB OF SCIENCE™

Selection of our books indexed in the Book Citation Index  
in Web of Science™ Core Collection (BKCI)

Interested in publishing with us?  
Contact [book.department@intechopen.com](mailto:book.department@intechopen.com)

Numbers displayed above are based on latest data collected.  
For more information visit [www.intechopen.com](http://www.intechopen.com)



---

# Therapeutic Mechanisms of Action for Hyperbaric Oxygen on Femoral Head Necrosis

---

Gerardo Bosco, Alex Rizzato, Giuliano Vezzani,  
Vincenzo Zanon and Enrico Camporesi

Additional information is available at the end of the chapter

<http://dx.doi.org/10.5772/intechopen.75026>

---

## Abstract

Femoral head necrosis (FHN) is a disease process resulting from inadequate blood perfusion of subchondral bone. While the etiology of this disease is still not fully understood, there are multiple traumatic and atraumatic factors that are associated with the disease. Pathophysiology of the disease is characterized by the death of bone marrow and osteocytes. If left untreated, the disease may progress to joint collapse. While initial stages of the disease are asymptomatic, painful limitation of active and passive motion of the hip is eventually present. The current body of literature cannot identify an optimal treatment protocol for FHN. Postcollapse cases require surgical intervention, core decompression, or total hip arthroplasty. However, current strides in conservative management are being made. One of the possible conservative modalities that may effectively delay hip arthroplasty or even prevent the need for a surgical approach is hyperbaric oxygen (HBO<sub>2</sub>) therapy. HBO<sub>2</sub> increases extracellular oxygen concentration and reduces cellular ischemia and edema by inducing vasoconstriction. Studies have reported radiographic improvement, reduction in pain, and increases in range of motion for early stages of the disease. Hyperbaric oxygen therapy has also been shown to stimulate angiogenesis and enhance osteoclast and osteoblast function for remodeling and repair.

**Keywords:** hyperbaric oxygen, femoral head necrosis, mechanisms of action, inflammation, cytokines

---

## 1. Introduction

Femoral head necrosis (FHN), also named avascular necrosis or osteonecrosis of the femoral head, is a common multifactorial disorder that affects patients of any age and can result in

substantial clinical morbidity [1]. Osteonecrosis is characterized by the lack of or inadequate blood flow to the bony tissue that leads to death of the osteocytes and the bone marrow [2].

As reported by Parsons and colleagues, it is most common in the second to fifth decades of life, and the typical patient is a male, in his mid-30s [3]. Epidemiology reveals between 10,000 and 20,000 new cases of FHN diagnosed each year in the United States [4]. In the western countries, the prevalence of the disease is at a mean age of 39 years, and the 10% of hip replacements performed is due to FHN [5]. Femoral head collapse, hip joint degenerative lesions, and subsequent long-term disability represent possible adverse consequences of the untreated or nondiagnosed FHN [6]. In particular, it is estimated that more than 70% of femoral heads with osteonecrosis will proceed to collapse, requiring prosthetic joint replacement within 3–4 years of diagnosis [7]. About that, it is responsible for 5–18% of all hip replacements performed [4]. Moreover, similar pathophysiology can occur in other articular districts (i.e., the femoral condyle, the wrist, the head of the humerus, and the distal talus) caused by comparable avascular syndromes. Multifocal osteonecrosis is defined as a disease involving three or more separate anatomic sites concurrently or consecutively [8].

Radiographic diagnosis is now possible at a former stage; thus, orthopedic physicians can identify the disorder earlier [9].

Hyperbaric oxygen (HBO) therapy is one of the proposed treatments. Indeed, tissue oxygenation promotes angiogenesis inducing edema reduction [1]. Moreover, by reducing intraosseous pressure, venous drainage is restored and the microcirculation is improved [10]. With restriction to the stage considered, Camporesi et al. showed that HBO should be considered the primary treatment modality in any patients and especially in young patients where the goal is to delay total hip arthroplasty as long as possible [5]. Therefore, the European Community accepted femoral head necrosis as an indication for hyperbaric oxygen therapy (HBOT) during the Consensus Conference in Lille, France [11].

Originally, the relation between femoral head necrosis and HBOT was deeply analyzed on a specific chapter published on *Hyperbaric Medicine Practice* [12]. It reported precise charts of patient results and a detailed review of the literature until 1997, as well as the different pathological outcomes and rationale for treatment [13]. Recently, an extended report on this topic has been proposed by Bosco and colleagues [1, 14]. They precisely updated the scientific literature until 2016 and summarized, for the paper's eligibility for the study, the number of patients, aim, inclusion/exclusion criteria, and obtained outcomes. Even though management, care, and therapeutic options are clearly stated for the pathology, available results differ from each other according to the stratification criteria and the particular stage of the disorder [15]. The present chapter aims to review more recent evidence from the scientific literature, outlining the physiology and the present status of pathology and therapy for femoral head necrosis. In particular, we focused on therapeutic mechanisms of action for hyperbaric oxygen (HBO<sub>2</sub>) on femoral head necrosis.

## 2. Etiology

In studying FHN, the absence of a bipedal mammalian model limits our knowledge among risk factors and pathogenesis of the disease. Additionally, completing longitudinal studies is

difficult for researchers and clinicians. However, scientific community agrees that ischemia plays a main role in the pathogenesis. As aforementioned, FHN is a multifactorial disease in which both genetic and daily-living factors lead to the pathology. When evaluating patients with osteonecrosis, physicians should first differentiate between primary (“idiopathic”) osteonecrosis and secondary osteonecrosis [16]. Although the etiology of secondary osteonecrosis has not been clearly delineated, risk factors include both traumatic and nontraumatic conditions (i.e., corticosteroid use, alcohol consumption, smoking, coagulation abnormalities, etc.) [17].

Traumatic events may lead to bone fracture or at worst to femoral head displacement; since the trauma occurs, it directly results in disruption of the femoral head blood supply [18]. Malizos et al. distinguished different pathogeneses in patients with subcapital fracture and patients with hip dislocation. In the first case, the 10–20% of the vascularization of femoral head is preserved from ligamentum teres. Conversely, as the hip dislocation occurs, blood supply is interrupted, and perfusion depends on the integrity of retinacular vessels [2].

Otherwise, nontraumatic osteonecrosis is frequently associated with pathologies where corticosteroid treatment is required (i.e., systemic lupus erythematosus, organ transplant, lymphoma, etc.). A report described the case of a female patient who was just under 18 years old when she underwent surgery due to bilateral osteonecrosis of the femoral condyles that developed in the course of treatment of a hematological malignancy [19]. Even though, scientific literature does not know the exact dose of steroids necessary to induce osteonecrosis, the higher the dose the greater the risk. Indeed, daily mean or peak dose taken seems to be more implicated than cumulative or duration of therapy [3]. Furthermore, an addiction to alcohol and long drinking period were reported as risk factors for FHN. In comparing gender difference, studies indicated for males a greater frequency of alcohol-induced FHN with respect to females [20, 21]. Indeed, Shimizu et al. showed a bigger susceptibility of males in developing FHN in response to alcohol consumption. Specifically, females did not develop osteonecrosis for alcohol consumption for both short-time and long-time periods. However, further investigations are needed among sex-related factors responsible for this evidence [20].

Further risk factors of FHN can be identified in bone marrow transplantation, as well as metastatic malignancies, and pregnancy. Additionally, it may be associated with pathologies as hyperuricemia, pancreatitis, and leukemia or lymphoma [9, 14].

### 3. Pathophysiology

FHN physiopathology is characterized from a complex series of events that couple a usual pathway of cellular death and osteogenic processes [14]. Pathogenic course begins with two associated mechanisms: edema of interstitial marrow and necrosis of hematopoietic cells and adipocytes. Histological signs appear nearly 24–72 h following anoxia, even though osteocyte necrosis is evident after approximately 2–3 h of oxygen deprivation [22, 23]. These stimuli induce bone remodeling processes. Originally, inflammatory signs (i.e., reactive hyperemia and capillary revascularization) surround the necrotic area. Thus, this mechanism initiates bone repairing in which new bone hardly tries to remove and substitute dead tissues [9].

However, bone remodeling proceeds inefficiently because of dead trabeculae, where new living bone is placed. Moreover, osteolysis exceeds osteogenesis, and this results in loss of structural integrity of trabeculae, with subsequent subchondral fracture and joint incongruity [24].

Altered subchondral vascularity is the basic pathophysiological hallmark for FHN [9]. Kiaer and colleagues indicated that a blood supply drop of 60% will result in an intraosseous  $pO_2$  decrease, from 75 mmHg to 50 mmHg [25]. Consequently, it will cause evident ischemia.

Different pathogenic mechanisms can result in FHN. Cytotoxicity due to exposure to radiation, chemotherapy, or thermal injury causes direct death of marrow cells and osteocytes, though this was not shown in vivo yet [18]. Additionally, three main pathogenic mechanisms can lead to ischemic conditions and subsequent femoral head necrosis:

1. Vascular interruption by fractures or dislocation (i.e., traumatic osteonecrosis). Femoral neck fractures or hip displacement usually result in extra-osseous arterial involvement. Specifically, when fracture occurs inside the joint capsule, vessels that oxygenate the subchondral bone suffer a direct trauma. A relatively high incidence of FHN in patients with these fractures has been reported.
2. Intravascular coagulation and microcirculatory thrombosis. Different pathways can lead to the same vascular obstructions that mean sickle cell aggregations, clots, or lipid thrombi [6]. Thrombotic emboli can occur both in arteriosus and venous areas in samples of osteonecrotic tissue; in some animal models, they have been associated with osteocyte necrosis [3]. The prevalence of sickle cell anemia-induced osteonecrosis stands between 37 and 50%. The weak arterial network in the hip joint eases vascular occlusion by sickled cells [16]. In these patients, low oxygen tension environments are hypothesized to trigger hemoglobin precipitation which leads to erythrocyte sickling [6]. Moreover, the complication rate for patients with sickle cell disease undergoing orthopedic procedures is significantly higher than that for patients without sickle disease. Consequently, early and alternative interventions are critical to successfully delay total hip arthroplasty.

Also, coagulation disorders are implicated in FHN. For example, genetic defects resulting in hypofibrinolysis or thrombophilia may lead to increased thrombi formation and blood flow obstruction in the bony tissues. Nevertheless, using a case-control methodology, elevated coagulation factor levels have been reported in patients with osteonecrosis showing the absence of known genetic defects [14]. Jarman et al. showed that coagulation abnormality-derived osteonecrosis is worsened by testosterone therapy, and its development may be slowed or stopped by discontinuation of therapy and, thereafter, anticoagulation [26]. Indeed, Guo and colleagues suggested the use of anticoagulant therapy for primary FHN. However, anticoagulants cannot play a protective role on secondary FHN [27]. Coagulation pathologies recognized before femoral head necrosis simplify therapeutic approach, preserving joints.

3. Intraosseous extravascular compression from lipocyte hypertrophy or Gaucher cells. It can also result from hemorrhage, infection, high bone marrow pressure, marrow infiltration, and bone marrow edema [18]. Physiologically, since the pressure increases within

the intraosseous extravascular region, microcirculation in vessels crossing the tissue decreases. Nevertheless, it is not a regular event. Many times, steroid consumption influences lipid metabolism leading to fat production in bone stem cells and drug-induced osteoporosis and osteonecrosis [3, 28]. This process will soon result in fat cell hypertrophy. Subsequently, intraosseous pressure will rise and ischemic condition will occur [29]. Though osteonecrosis is mostly associated with hypercholesterolemia and/or hypertriglyceridemia, the osteonecrosis-related lipid abnormalities have been well documented with the Gaucher disease (GD) [16]. Gaucher disease (GD) is a lysosomal storage disorder, caused by an impaired function of  $\beta$ -glucocerebrosidase, which results in accumulation of glucocerebroside in cells, and altered membrane ordering [30]. However, microcirculatory blood flow blockage is not necessarily the starting pathological event. Lysosomal contents released from Gaucher cells may damage vessel membrane, with localized osteonecrosis that may extend to bordering areas [31]. Skeletal involvement is typical in mature patients suffering from type 1 Gaucher disease, with a radiological evidence described in 93% of cases. Among these, the 30% presents osteonecrosis [31].

4. The fourth physiopathological mechanism is under investigation: extra-osseous venous obstruction. Although impairment of the extra-osseous veins happens, there is still an uncertainty whether it is a cause or effect. Additionally, it possibly has limited clinical meaning [6]. Recently, Shah et al. reviewed literature on this topic, and they investigated increased intraosseous pressure as a pathogenic process in FHN. In particular, bloodstream interruption or stasis in the venous side has been associated with increased pressure in osteonecrotic samples [6].

Since the seventies, scholars studied dysbaric osteonecrosis and explained radiographic features of this pathology [32]. It is an avascular bone necrosis induced by exposure to hyperbaric environments, typical for diverse and compressed air workers [33]. A literature review on dysbaric osteonecrosis evidenced that incomplete decompression procedures lead to blood supply decrease and subsequent osteonecrosis; this is due to the entry of nitrogen bubbles in the fatty marrow-containing shafts of long bones [34]. Studies clearly stated the approach to be used, outlining diving decompression schedules [33].

#### **4. Rationale for using hyperbaric oxygen**

HBO<sub>2</sub> therapeutic mechanisms of action are based on elevation both of the partial pressure of inspired O<sub>2</sub> and of the hydrostatic pressure. The latter mechanism contributes to determine the compression of all gas-filled spaces in the body (Boyle's law), and it is fundamental to allow an effective treatment of those conditions where gas bubbles are present in the body and cause the disease (e.g., intravascular embolism or decompression illness with intravascular or intra-tissue bubbles) [35, 36]. However, most patients treated with HBO<sub>2</sub> do not suffer from bubble-induced lesions, deriving their clinical improvements from the other mechanism of HBO<sub>2</sub> therapy: the elevated O<sub>2</sub> partial pressures achieved. High O<sub>2</sub> partial pressures so obtainable in various tissues lead to the increase in the production of reactive O<sub>2</sub> species (ROS)

as well as of reactive nitrogen species (RNS), these last ones due to hyperoxia [37]. Controlled studies have already shown as the clinical efficacy from HBO<sub>2</sub> depends on modulation of intracellular transduction cascades, driving to synthesis of growth factors, promoting the wound healing, and ameliorating postischemic and post-inflammatory injuries [36].

The actual inability to establish which will be the correct dose of HBO<sub>2</sub> to administer in each case is still depending on the lack in Level 1 evidence [1, 11]; as a matter of fact, the current scientific literature does not yet allow a clear identification of the optimal treatment protocol.

Nevertheless, HBO<sub>2</sub> is positioned among the possible and feasible therapies which allow to provide a delay in undergoing hip arthroplasty surgery; it is a reasonable postulate that such therapy can show a beneficial effect without having the invasiveness of a surgical approach.

HBO<sub>2</sub> increases extracellular oxygen concentration and reduces cellular ischemia and edema by inducing vasoconstriction [38]. Studies have already reported radiographic improvement in FHN at stage I according to the Steinberg classification, as well as a better pain control, compliance, and range of motion (ROM) in FHN at Ficat stages I–II [36]. Amid the possible effects of HBO<sub>2</sub>, there is a reduced bone marrow pressure, leading to a significant pain relief, and an increased oxygen delivery to ischemic cells, thus relieving compartment syndrome so to prevent a progression in a further necrosis, stimulating angiogenesis and oxygen-dependent cells, and enhancing osteoclast and osteoblast function for remodeling and repair. Moreover, HBO<sub>2</sub> is also able to stimulate the multipotent fibroblasts in the bone marrow with an additional aid in the osteogenesis process [37].

In FHN treatment HBO facilitates oxygenation of hypoxic tissue and reduces edema by creating a high concentration of dissolved oxygen and inducing vasoconstriction. This may explain the early pain relief noticed in patients treated with this modality; by saturating the extracellular fluid with diffused oxygen, HBO treatment will lead to a better oxygenation of the ischemic bone cells, independently of circulating hemoglobin and without the extra-energy requirement to provide for the dissociation of oxygen from hemoglobin. Late effects of HBO are bone resorption, revascularization, and osteogenesis [5, 36].

Yang et al. quantitatively evaluated the hemodynamic flow in animal models with steroid-induced FHN by using multi-slice CT perfusion imaging. Especially in the early stage, they assessed how HBO therapy resulted in regional blood flow improvement in the ischemic tissues. Additionally, they found high-grade new bone formation and a well-regenerated hematopoietic tissue [39]. Moreover, recent studies focusing among osteoblasts differentiation and suppression osteoclasts showed positive results due to hyperbaric oxygen treatment. In particular, HBO shifted the balance between bone formation and bone resorption promoting regeneration [40, 41].

## 5. Clinical presentation

An early detection of FHN is of paramount importance as clinical success of the therapy is closely related to the stage which the treatment started in [42]. There are several procedures capable to intercept a suspected FHN at the onset or eventual early stages of the disease:

at the present time, histological studies, scintigraphy, functional bone evaluation, radiography, magnetic resonance imaging (MRI), and computer-assisted tomography (CAT) are the most current diagnostic methods available. At an early stage, FHN is usually asymptomatic or characterized by slight pain radiating to the knee and/or ipsilateral buttock.

It may present with a limited range of hip movement as well as stabbing pain, especially during a forced intra-rotation. FHN should be considered if the patient feels pain in the hips and has no risk factors in his clinical history. In particular, plain radiographs can often appear as normal in the early stages of necrosis. Patients with a history of previous necrosis should be observed for bilateral FHN; this condition has been reported up to 70% of the observations [43].

Classification systems currently in use for FHN include the Ficat and Steinberg systems [15].

The Ficat classification substantially relies on standard radiographic presentations, where phase I shows normal images; phase II indicates a normal contour, with evidence of a bone remodeling; stage III is characterized by subchondral collapse or flattening of the femoral head; and phase IV indicates a narrowing of the joint space, with secondary degenerative changes in the acetabulum. The Ficat classification system is however based on radiographic imaging; therefore, the real size of the lesion cannot be quantified up to a more proper and accurate measure of the radiological appearance of the disease.

Steinberg expands the Ficat system into six stages, including quantification of involvement of the femoral head within stages I–VI, with three further subsets each: mild (less than 15% radiographic involvement of the head's articular surface), moderate (with a 15–30% involvement of the head's articular surface), and severe (greater than 30% involvement of the head's articular surface) stages.

Recently, the Association Research Circulation Osseous (ARCO) has recommended a third standardized classification system relying on an interpolated comparison of different procedure findings: radiographic, MRI, bone scan, and histologic findings [15]. Anyhow, not even this can eliminate completely the intrinsic operator-dependent variability, making Ficat and ARCO classification systems still not sufficiently reliable to assess FHN occurrence [44].

FHN is currently diagnosed by plain anterior-posterior and frog leg lateral radiographs of the hip, followed by MRI; this is considered the most accurate benchmark. Other existing tools for assessing the FHN presentation, such as venography, bone marrow pressure measurements, and core biopsy, are rarely used.

## **6. Clinical management of femoral head necrosis**

Many therapeutic modalities have been proposed, and their effects were recently reviewed by Sen [45] and Zalavras and Lieberman [17].

Where untreated, FHN is a progressive disease process in affected hip showing an intact articular survival rates of less than 60% in 5 years; furthermore, the survival rate in stage III is less than 10% [10, 13].

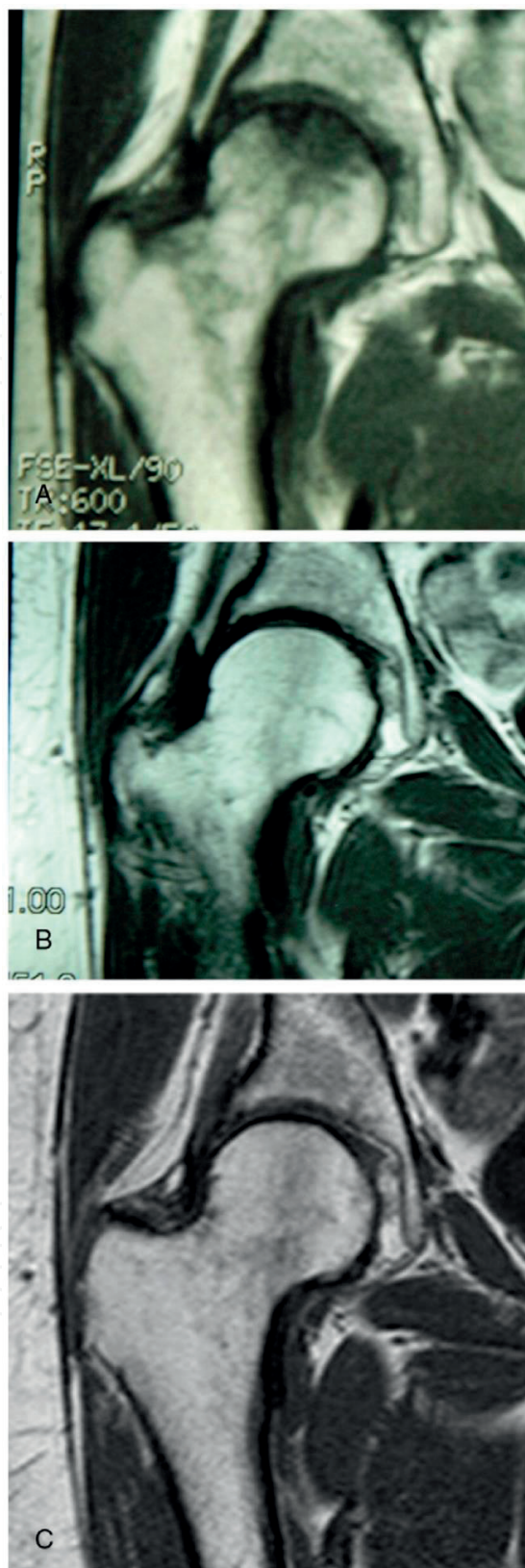


Actual clinical evidence clearly demonstrates that HBO is able to lead to an extended duration of the survival rate of the affected hips:

- Reis et al. treated 12 patients with stage I ANFH, one daily HBO session, for a total of 100 HBO treatments. They reported that 81% of HBO-exposed patients returned to normal MRI vs. only 17% in the untreated group [46].
- A double-blind, randomized, controlled, prospective study evaluated hyperbaric oxygen therapy on a cohort of 20 patients with unilateral FHN (Ficat stage II) [5]. All patients were treated with either compressed oxygen or compressed air (HBA); each patient received 30 treatments of HBO or HBA for 6 weeks. After the initial 6-week treatment, the blind was broken: all HBA patients were then offered to undergo HBO treatment. From this point on, the study veers toward an observational design study. Range of motion (ROM), stabilometry, and pain were assessed at the beginning of the study and after 10, 20, and 30 treatments by a blinded physician. Resonance images were obtained at a pretreatment stage, at 12-month post-HBO, and at a final 7-year follow-up (**Figure 1**). There was a significant pain improvement after HBO, with significance after 20 treatments on average. ROM improved likewise during HBO, for all parameters, after 20–30 treatments. At 7-year follow-up, all patients remained substantially pain-free and none required hip arthroplasty; an almost complete radiographic healing of the osteonecrosis was observed in seven of nine hips. Hyperbaric oxygen therapy does appear to be a viable treatment modality in patients with Ficat II FHN [5].
- Koren et al. used HBO to treat 68 patients (78 joints) with stage I and II disease; these authors' HBO protocol involved breathing 100% oxygen at 2.0–2.4 ATA for 90 min, for a total of 20 treatments. They reported that 88% of the HBO treatment group had improvement on MRI and a 93% survival rate of the joints at  $11.1 \pm 5.1$  year of follow-up of 54 patients (58 joints) [10].
- Recently, the long-term effect of HBO in 217 patients with stage I, II, and III ANFH has been investigated [47]. These results validated previous findings: HBO shows itself to be able to significantly improve hip condition, alleviate pain, and, more importantly, avoid hip surgery in most of patients presenting a stage II disease. Moreover, this study further shows the beneficial effects of HBO in stage III patients, where hip pain is significantly reduced in most patients, hip surgery is avoided in approximately half of the patients, and the obtained results are maintained for up to 4 years [47].

One of the first studies, proposed by Baixe and colleagues, affirmed that 20 HBO treatments were sufficient for pain reduction [48]. As previously reported, Camporesi and colleagues showed that after 20–30 treatments patients were substantially pain-free [5]. However, 20 HBO treatments are not sufficient for the complete hip healing.

Even though there are many evidences among beneficial effects of HBO, there is still no agreement on the number of HBO treatments required. The recent work by Bosco and colleagues generated a mean number of  $83.3 \pm 24.8$  [47], while in the study by Koren et al., the average number of treatments was  $78.3 \pm 24.2$ : this in itself is remarkably close [10]. In other papers the number of treatments widely ranges from 20 to 120 [49].



**Figure 1.** MRI pictures of a patient treated with HBO. (A) A pretreatment MRI exhibiting bone defect. (B) A twelve-month MRI showing near complete resolution of bone defect. (C) A seven-year follow-up MRI showing no change in bone defect [5].

A large number of sessions showed to be effective on pain relief and mobility improvement and avoided arthroplasty, in about 80% of cases. In particular, about 90% of Ficat I and II patients and half of Ficat III patients after HBOTs had no more need of surgery and all related complications for at least 4 years [47].

## 7. New perspectives

Despite the several clinical studies that support the benefits of HBOT in patients afflicted with osteonecrosis [1, 5], therapy is still not worldwide approved. This could be due to several factors including the apparent high number of HBO treatments necessary plus limited amount of clinical evidence for FHN, the majority of the evidence relies on ex vivo and in vitro studies, and the molecular mechanisms responsible for the regenerative responses of HBOT are still debatable. Thus, the underlying mechanism of action is still unclear.

A recent study investigated HBO upregulation on serum osteoprotegerin (OPG) and/or inhibition of osteoclast activation [50]. Twenty-three patients suffering from unilateral FHN at stage I, II, and III consented to the study: patients received standard HBOT; nineteen patients completed the study. Serum OPG levels were obtained at the beginning of HBOT ( $T_0$ ), after 15 sessions ( $T_1$ ), after 30 sessions ( $T_2$ ), after a 30-day break ( $T_3$ ), and at the end of our treatment protocol, after 60 sessions ( $T_4$ ). Magnetic resonance imaging (MRI) was obtained at  $T_0$  and about 1 year from the end of HBO treatments to compare pre-HBOT with post-HBOT lesion size.

The findings were:

- HBOT reduced pain symptoms in all patients.
- HBOT significantly reduced lesion size in all stage I and II patients and in 2 of 11 stage III patients.
- HBOT increased serum OPG levels, but receptor activator of nuclear factor kappa-B ligand (RANKL) levels did not change.

These evidences proposed an influence of HBO on the immune system and inflammatory processes. Indeed, one of the initial studies by Lukich et al. suggested an immunosuppressive effect of HBO therapy in patients suffering from rheumatoid arthritis [51]. Later, other studies reinforced these findings. Specifically, authors showed TNF-alpha and interleukin-1 $\beta$  (IL-1 $\beta$ ) inhibition after HBO therapy in indomethacin-induced enteropathy and in chronic constriction injury-induced neuropathy [52, 53]. The following are some examples of tissue cytokine changes proposed after HBO.

IL-1 $\beta$  is a pro-inflammatory cytokine that responds to injury or infection by binding to the type-1 IL-1 receptor (IL-1R) and IL-1R accessory protein [54]. Although belonging to a structurally different cytokine class, IL-1 resembles many of the biological activities of TNF- $\alpha$ ; IL-1 activation results in downstream activation of NF-kB and JNK [55, 56]. Fukushima et al. found that IL-1 $\beta$  has a stimulatory effect on osteoclast formation via increasing expression of RANKL [57]. IL-1 $\beta$ , like TNF- $\alpha$  and IL-6, is produced by stromal cells and monocytes. These

cytokines can synergistically stimulate osteoclast differentiation leading to a net increase in RANKL activity and control their own expression [56].

IL-6 has been demonstrated to exhibit a dual effect on osteoclastic differentiation. During the inflammatory process, monocytes/macrophages produce IL-6, which can directly stimulate pre-osteoclast cells to be differentiated and activated [56]. In addition, IL-6 can stimulate stromal/osteoblastic cells to produce certain effectors, namely, IL-6, which will then promote osteoclastic differentiation [56]. Thus, there is a dual contribution, direct and indirect interaction, in which IL-6 can upregulate bone turnover. In vivo studies of IL-6 found that in transgenic mice with overexpressed IL-6 there is a greater bone turnover, reduced osteoblasts, and increased osteoclasts leading to osteopenia [58]. Correspondingly, IL-6-deficient mice displayed reduced osteoclasts and lower levels of bone erosion [59]. Kurokouchi and colleagues found TNF- $\alpha$  to increase the expression of IL-6 and ICAM-1 genes [60]. Hence, lower levels of TNF- $\alpha$  resulting from HBOT exposure could explain the reduction in IL-6. This effect, in summation with the synergistic effects of TNF- $\alpha$ , IL-6, and RANKL, could ultimately lead to decreased levels of osteoclastogenesis and, hence, greater resolution for the patient [56]. In the case of FHN, HBOT results in a decreased amount of circulating TNF- $\alpha$ . We propose the following mechanism: HBOT leads to reduced levels of TNF- $\alpha$  leading to decreased binding of TNF- $\alpha$  to the p55r type 1 receptor and thus decreased levels of NF- $\kappa$ B activation [56]. This reduction in RANKL would tip the balance of OPG/RANKL in the direction of osteoblast activation [50].

Understanding the HBOT's molecular mechanism of action remains the best approach in order to gain greater recognition for this treatment and to achieve earlier resolution for patients.

## Author details

Gerardo Bosco<sup>1\*</sup>, Alex Rizzato<sup>1</sup>, Giuliano Vezzani<sup>1</sup>, Vincenzo Zanon<sup>1</sup> and Enrico Camporesi<sup>2</sup>

\*Address all correspondence to: gerardo.bosco@unipd.it

1 Master Level II in Diving and Hyperbaric Medicine and Physiological Lab, Department of Biomedical Sciences, University of Padova, Padova, Italy

2 Anesthesia, Tampa General Hospital, TEAM Health, Tampa, Florida, USA

## References

- [1] Camporesi E, Vezzani G, Zanon V, Manelli D, Enten G, Quartesan S, et al. Review on hyperbaric oxygen treatment in femoral head necrosis. *Undersea & Hyperbaric Medicine*. 2017;**44**(6):497-508
- [2] Malizos KN, Karantanas AH, Varitimidis SE, Dailiana ZH, Bargiotas K, Maris T. Osteonecrosis of the femoral head: Etiology, imaging and treatment. *European Journal of Radiology*. 2007;**63**(1):16-28

- [3] Parsons SJ, Steele N. Osteonecrosis of the femoral head: Part 1—Aetiology, pathogenesis, investigation, classification. *Current Orthopaedics*. 2007;**21**(6):457-463
- [4] Babis GC, Sakellariou V, Parvizi J, Soucacos P. Osteonecrosis of the femoral head. *Orthopedics*. 2011;**34**(1):39
- [5] Camporesi EM, Vezzani G, Bosco G, Mangar D, Bernasek TL. Hyperbaric oxygen therapy in femoral head necrosis. *The Journal of Arthroplasty*. 2010;**25**(6):118-123
- [6] Shah KN, Racine J, Jones LC, Aaron RK. Pathophysiology and risk factors for osteonecrosis. *Current Reviews in Musculoskeletal Medicine*. 2015;**8**(3):201-209
- [7] Steinberg M. Recent advances in the management of osteonecrosis of the hip. *Seminars in Arthroplasty*. 1998;**(9)**:181-183
- [8] Sun W, Shi Z, Gao F, Wang B, Li Z. The pathogenesis of multifocal osteonecrosis. *Scientific Reports*. 2016;**6**(1):29576
- [9] Aaron R, Gray R. Osteonecrosis: Etiology, natural history, pathophysiology, and diagnosis. In: Callaghan JJ, Rosenberg AG, Rubash H, editors. *The Adult Hip*. Philadelphia: Lippincott Williams & Wilkins; 2007. pp. 465-476
- [10] Koren L, Ginesin E, Melamed Y, Norman D, Levin D, Peled E. Hyperbaric oxygen for stage I and II femoral head osteonecrosis. *Orthopedics*. 2015;**38**(3):e200-e205
- [11] Mathieu D, Marroni A, Kot J. Tenth European consensus conference on hyperbaric medicine: Preliminary report. *Diving and Hyperbaric Medicine*. 2016;**46**(2):122-123
- [12] Clark J, Whelan HT. Oxygen toxicity. In: Kindwall EP, Wheland HT, editors. *Hyperbaric medicine practice*. Best Publishing Company; 1999. pp. 69-83
- [13] Strauss M, Dvorak T, Melamed Y, Reis D. Femoral head necrosis and hyperbaric oxygen therapy. In: Flagsta AZ, editor. *Hyperbaric Medicine Practice*. North Palm Beach: Best Publishing Company; 2008. pp. 943-944
- [14] Vezzani G, Bosco G, Camporesi EM. Hyperbaric oxygen treatment of avascular bone necrosis of the femoral head. In: Whelan HT, Kindwall EP, editors. *Hyperbaric Medicine Practice*. 4th ed. North Palm Beach: Best Publishing Company; 2017. pp. 955-974
- [15] Amanatullah DF, Strauss EJ, Di Cesare PE. Current management options for osteonecrosis of the femoral head: Part 1, diagnosis and nonoperative management. *The American Journal of Orthopedics*. 2011 Sep;**40**(9):E186-E192
- [16] Glueck CJ, Wang P, Freiberg RA. Osteonecrosis and thrombophilia: Pathophysiology, diagnosis, and treatment. In: *Osteonecrosis of the Femoral Head*. Cham: Springer International Publishing; 2017. pp. 3-17
- [17] Zalavras CG, Lieberman JR. Osteonecrosis of the femoral head: Evaluation and treatment. *The Journal of the American Academy of Orthopaedic Surgeons*. 2014;**22**(7):455-464
- [18] Israelite CL, Garino JP. Osteonecrosis of the hip. *Seminars in Arthroplasty*. 2005;**16**(1):27-32

- [19] Graboń K, Paczesny Ł, Kruczyński J. Avascular necrosis of femoral condyles in a patient treated due to lymphoma. A case study. *Ortopedia, Traumatologia, Rehabilitacja*. 2017; **19**(5):469-480
- [20] Shimizu J, Okazaki S, Nagoya S, Takahashi N, Kanaya K, Mizuo K, et al. Susceptibility of males, but not females to developing femoral head osteonecrosis in response to alcohol consumption. *PLoS One*. 2016;**11**(10):e0165490
- [21] Fukushima W, Fujioka M, Kubo T, Tamakoshi A, Nagai M, Hirota Y. Nationwide epidemiologic survey of idiopathic osteonecrosis of the femoral head. *Clinical Orthopaedics and Related Research*. 2010;**468**(10):2715-2724
- [22] Bauer TW, Stulberg BN. The histology of osteonecrosis and its distinction from histologic artifacts. In: *Bone Circulation and Vascularization in Normal and Pathological Conditions*. Boston, MA: Springer US; 1993. pp. 283-292
- [23] Stulberg BN, Levine M, Bauer TW, Belhobek GH, Pflanze W, Feiglin DH, et al. Multimodality approach to osteonecrosis of the femoral head. *Clinical Orthopaedics and Related Research*. 1989;(240):181-193
- [24] Brown TD, Baker KJ, Brand RA. Structural consequences of subchondral bone involvement in segmental osteonecrosis of the femoral head. *Journal of Orthopaedic Research*. 1992;**10**(1):79-87
- [25] Kiaer T, Pedersen NW, Kristensen KD, Starklint H. Intra-osseous pressure and oxygen tension in avascular necrosis and osteoarthritis of the hip. *Journal of Bone and Joint Surgery. British Volume (London)*. 1990;**72**(6):1023-1030
- [26] Jarman MI, Lee K, Kanevsky A, Min S, Schlam I, Mahida C, et al. Case report: Primary osteonecrosis associated with thrombophilia-hypofibrinolysis and worsened by testosterone therapy. *BMC Hematology*. 2017;**17**(1):5
- [27] Guo P, Gao F, Wang Y, Zhang Z, Sun W, Jiang B, et al. The use of anticoagulants for prevention and treatment of osteonecrosis of the femoral head: A systematic review. *Medicine (Baltimore)*. 2017;**96**(16):e6646
- [28] Cui Q, Wang GJ, Balian G. Steroid-induced adipogenesis in a pluripotential cell line from bone marrow. *The Journal of Bone and Joint Surgery. American Volume*. 1997 Jul; **79**(7):1054-1063
- [29] Wang GJ, Cui Q, Balian G. The Nicolas Andry award. The pathogenesis and prevention of steroid-induced osteonecrosis. *Clinical Orthopaedics and Related Research*. 2000; **370**:295-310
- [30] Pavićević A, Lakočević M, Popović M, Popović-Bijelić A, Daković M, Mojović M. Changes of the peripheral blood mononuclear cells membrane fluidity from type 1 Gaucher disease patients: An electron paramagnetic resonance study. *Biological Chemistry*. Jan 24, 2018 [Epub ahead of print]
- [31] Linari S, Castaman G. Clinical manifestations and management of Gaucher disease. *Clinical Cases in Mineral and Bone Metabolism*. 2015;**12**(2):157-164

- [32] Davidson J. Radiology of Dysbaric osteonecrosis. *Journal of Clinical Pathology*. 1972; **25**(11):1005-1006
- [33] Uguen M, Pougnet R, Uguen A, Lodde B, Dewitte JD. Dysbaric osteonecrosis among professional divers: A literature review. *Undersea & Hyperbaric Medicine*. 2014;**41**(6): 579-587
- [34] Sharareh B, Schwarzkopf R. Dysbaric osteonecrosis: A literature review of pathophysiology, clinical presentation, and management. *Clinical Journal of Sport Medicine*. 2015 Mar;**25**(2):153-161
- [35] Vann RD, Butler FK, Mitchell SJ, Moon RE. Decompression illness. *The Lancet*. 2011; **377**(9760):153-164
- [36] Camporesi EM, Bosco G. Mechanisms of action of hyperbaric oxygen therapy. *Undersea & Hyperbaric Medicine*. 2014;**41**(3):247-252
- [37] Thom SR. Hyperbaric oxygen: Its mechanisms and efficacy. *Plastic and Reconstructive Surgery*. 2011;**127**(Suppl 1):131S-141S
- [38] Bosco G, Yang Z, Nandi J, Wang J, Chen C, Camporesi EM. Effects of hyperbaric oxygen on glucose, lactate, glycerol and anti-oxidant enzymes in the skeletal muscle of rats during ischaemia and reperfusion. *Clinical and Experimental Pharmacology & Physiology*. 2007;**34**(1-2):70-76
- [39] Yang J, Pan Z, Gu H, Li N, Qian X, Zhai R, et al. Quantitative study of therapeutic efficacy on early intervention of hyperbaric oxygen to model of steroid-induced avascular osteonecrosis of femoral head by multi-slice perfusion imaging. *Zhonghua Yi Xue Za Zhi*. 2008;**88**(45):3210-3216
- [40] Al Hadi H, Smerdon GR, Fox SW. Hyperbaric oxygen therapy suppresses osteoclast formation and bone resorption. *Journal of Orthopaedic Research*. 2013;**31**(11):1839-1844
- [41] Al Hadi H, Smerdon GR, Fox SW. Hyperbaric oxygen therapy accelerates osteoblast differentiation and promotes bone formation. *Journal of Dentistry*. 2015;**43**(3):382-388
- [42] Hungerford D. Bone marrow pressure, venography and core decompression in ischemic necrosis of the femoral head. In: Riley L, editor. *The Hip: Proceedings of the Seventh Open Scientific Meeting of the Hip Society*. Saint Louis: CV Mosby; 1979. pp. 218-237
- [43] Boettcher WG, Bonfiglio M, Hamilton HH, Sheets RF, Smith K. Non-traumatic necrosis of the femoral head. I. Relation of altered hemostasis to etiology. *Journal of Bone & Joint Surgery*. 1970;**52**(2):312-321
- [44] Schmitt-Sody M, Kirchhoff C, Mayer W, Goebel M, Jansson V. Avascular necrosis of the femoral head: Inter- and intraobserver variations of Ficat and ARCO classifications. *International Orthopaedics*. 2008;**32**(3):283-287
- [45] Sen RK. Management of avascular necrosis of femoral head at pre-collapse stage. *Indian Journal of Orthopaedics*. 2009;**43**(1):6-16

- [46] Reis ND, Schwartz O, Militianu D, Ramon Y, Levin D, Norman D, et al. Hyperbaric oxygen therapy as a treatment for stage-I avascular necrosis of the femoral head. *Journal of Bone and Joint Surgery. British Volume (London)*. 2003;**85**(3):371-375
- [47] Vezzani G, Camporesi EM, Mangar D, Bernasek T, Yang Z, Quartesan S, et al. Beneficial effect of hyperbaric oxygenation in avascular necrosis of the femoral head. *Gazzetta Medica Italiana Archivio per le Scienze Mediche*. 2018;**3**(1):18-26
- [48] Baixe J, Bidart J, Nicolini J. Treatment of osteonecrosis of the femoral head by hyperbaric oxygen. *Bulletins: Medecine Subaquatique et Hyperbare*. 1969;1:2
- [49] Uzun G, Mutluoglu M, Ersen O, Yildiz S. Hyperbaric oxygen therapy in the treatment of osteonecrosis of the femoral head: A review of the current literature. *Undersea and Hyperbaric Medicine*. 2016;**43**(3):189-199
- [50] Vezzani G, Quartesan S, Cancellara P, Camporesi E, Mangar D, Bernasek T, et al. Hyperbaric oxygen therapy modulates serum OPG/RANKL in femoral head necrosis patients. *Journal of Enzyme Inhibition and Medicinal Chemistry*. 2017;**32**(1):707-711
- [51] Lukich VL, Poliakova LV, Sotnikova TI, Belokrinitskiĭ DV. Hyperbaric oxygenation in the comprehensive therapy of patients with rheumatoid arthritis (clinico-immunologic study). *Fiziologichnyi Zhurnal*; **37**(5):55-60
- [52] Yang Z, Nandi J, Wang J, Bosco G, Gregory M, Chung C, et al. Hyperbaric oxygenation ameliorates indomethacin-induced Enteropathy in rats by modulating TNF- $\alpha$  and IL-1 $\beta$  production. *Digestive Diseases and Sciences*. 2006;**51**(8):1426-1433
- [53] Li F, Fang L, Huang S, Yang Z, Nandi J, Thomas S, et al. Hyperbaric oxygenation therapy alleviates chronic constrictive injury-induced neuropathic pain and reduces tumor necrosis factor-alpha production. *Anesthesia and Analgesia*. 2011;**113**(3):626-633
- [54] Greenfeder SA, Nunes P, Kwee L, Labow M, Chizzonite RA, Ju G. Molecular cloning and characterization of a second subunit of the interleukin 1 receptor complex. *The Journal of Biological Chemistry*. 1995;**270**(23):13757-13765
- [55] Baud V, Liu ZG, Bennett B, Suzuki N, Xia Y, Karin M. Signaling by proinflammatory cytokines: Oligomerization of TRAF2 and TRAF6 is sufficient for JNK and IKK activation and target gene induction via an amino-terminal effector domain. *Genes & Development*. 1999;**13**(10):1297-1308
- [56] Steeve KT, Marc P, Sandrine T, Dominique H, Yannick F. IL-6, RANKL, TNF-alpha/IL-1: Interrelations in bone resorption pathophysiology. *Cytokine & Growth Factor Reviews*. 2004;**15**(1):49-60
- [57] Fukushima H, Jimi E, Okamoto F, Motokawa W, Okabe K. IL-1-induced receptor activator of NF- $\kappa$ B ligand in human periodontal ligament cells involves ERK-dependent PGE2 production. *Bone*. 2005;**36**(2):267-275
- [58] De Benedetti F, Rucci N, Del Fattore A, Peruzzi B, Paro R, Longo M, et al. Impaired skeletal development in interleukin-6-transgenic mice: A model for the impact of



chronic inflammation on the growing skeletal system. *Arthritis and Rheumatism*. 2006;**54**(11):3551-3563

- [59] Ohshima S, Saeki Y, Mima T, Sasai M, Nishioka K, Nomura S, et al. Interleukin 6 plays a key role in the development of antigen-induced arthritis. *Proceedings of the National Academy of Sciences*. 1998;**95**(14):8222-8226
- [60] Kurokouchi K, Kambe F, Yasukawa K, Izumi R, Ishiguro N, Iwata H, et al. TNF- $\alpha$  increases expression of IL-6 and ICAM-1 genes through activation of NF- $\kappa$ B in osteoblast-like ROS17/2.8 cells. *Journal of Bone and Mineral Research*. 1998;**13**(8):1290-1299

IntechOpen