

ESC working group position paper on myocardial infarction with non-obstructive coronary arteries

Stefan Agewall^{1*}, John F. Beltrame², Harmony R. Reynolds³, Alexander Niessner⁴, Giuseppe Rosano^{5,6}, Alida L. P. Caforio⁷, Raffaele De Caterina⁸, Marco Zimarino⁸, Marco Roffi⁹, Keld Kjeldsen¹⁰, Dan Atar¹, Juan C. Kaski⁶, Udo Sechtem¹¹, and Per Tornvall¹², on behalf of the WG on Cardiovascular Pharmacotherapy

¹Oslo University Hospital Ullevål and Institute of Clinical Sciences, University of Oslo, Oslo, Norway; ²The Queen Elizabeth Hospital Discipline of Medicine, University of Adelaide, Central Adelaide Local Health Network, Adelaide, Australia; ³Cardiovascular Clinical Research Center, Leon H. Charney Division of Cardiology, Department of Medicine, NYU School of Medicine, New York, NY, USA; ⁴Department of Internal Medicine II, Division of Cardiology, Medical University of Vienna, Wien, Austria; ⁵Centre for Clinical and Basic Research, Department of Medical Sciences, IRCCS San Raffaele Pisana, Rome, Italy; ⁶Cardiovascular and Cell Sciences Research Institute, St George's University of London, London, UK; ⁷Division of Cardiology, Department of Cardiological Thoracic and Vascular Sciences Padua University Medical School, Policlinico Universitario, Via N Giustiniani, 2, 35128 Padova, Italy; ⁸Institute of Cardiology, G. d'Annunzio University, Chieti, Italy; ⁹Division of Cardiology, University Hospital, 1211 Geneva 14, Switzerland; ¹⁰Copenhagen University Hospitals (Rigshospitalet and Holbæk Hospital), Copenhagen and Holbæk, and The Faculty of Medicine, Aalborg University, Aalborg, Denmark; ¹¹Abteilung für Kardiologie, Robert-Bosch Krankenhaus Stuttgart, Auerbachstr. 110, 70376 Stuttgart, Germany; and ¹²Department of Clinical Science and Education Södersjukhuset, Karolinska Institutet, Stockholm, Sweden

Received 29 August 2015; revised 14 January 2016; accepted 18 March 2016; online publish-ahead-of-print 28 April 2016

Introduction

The management of acute myocardial infarction (AMI)¹ has evolved over the past century and particularly in the past 50 years. Important milestones include the development of the electrocardiogram, coronary care units, coronary angiography, reperfusion therapies, and troponin assays. These innovations are the foundation of contemporary AMI management strategies that include a diagnosis centred on elevated troponin values associated with corroborative clinical evidence,¹ early use of coronary angiography, and reperfusion therapies.^{2–4}

Pivotal in the evolution of these contemporary strategies were the early AMI coronary angiography studies undertaken by DeWood *et al.* These pioneering studies demonstrated that, in patients presenting with ST elevation myocardial infarction (STEMI), almost 90% had an occluded coronary artery provided that angiography was undertaken within 4 h of chest pain onset.⁵ In contrast, in AMI patients who did not present with ST elevation (non-ST elevation myocardial infarction or NSTEMI), only 26% had an occluded coronary artery when angiography was performed within 24 h of symptom onset.⁶ In both of these landmark studies,^{5,6} >90% of the acute MI patients had angiographic evidence of obstructive coronary artery disease (CAD), underscoring the importance of the atherosclerotic process in the pathogenesis of AMI.

Although DeWood's studies underscore the importance of obstructive CAD in AMI, it is fascinating that ~10% had no significant CAD on coronary angiography. This is confirmed in several large AMI registries^{7–9} where 1–13% of AMI's occurred in the absence

of obstructive CAD thereby eliciting an important set of questions—what is the mechanism of the myocardial damage in these patients? Do these patients differ from those with obstructive CAD? Should they be managed with the same clinical strategies? Do patients with non-obstructive atherosclerosis differ in pathophysiology and outcomes from those with angiographically normal coronary arteries? These and other issues have prompted clinical researchers to coin the term myocardial infarction with non-obstructive coronary arteries (MINOCA). This position paper is the first authoritative international expert opinion regarding this intriguing condition. We seek to define MINOCA, describe its associated clinical features and mechanisms, detail an assessment pathway for its evaluation, as well as stimulate research into its mechanisms and treatment.¹⁰

Definitions

Rationale for diagnosis

As the name implies, the formulation of the MINOCA diagnosis requires both clinical documentation of an AMI and demonstration of non-obstructive coronary arteries (*Table 1*). Accordingly, the diagnosis is made following coronary angiography in the evaluation of a clinical presentation consistent with AMI. It should be noted that the Universal Definition of Myocardial Infarction specifies that the combination of symptoms and a positive cardiac biomarker in the appropriate clinical scenario is diagnostic of AMI. Therefore, if there is no clinically apparent alternative diagnosis, such as

Table 1 Diagnostic criteria for myocardial infarction with non-obstructive coronary arteries

The diagnosis of MINOCA is made immediately upon coronary angiography in a patient presenting with features consistent with an acute myocardial infarct, as detailed by the following criteria:

- (1) AMI criteria.¹
 - (a) Positive cardiac biomarker (preferably cardiac troponin) defined as a rise and/or fall in serial levels, with at least one value above the 99th percentile upper reference limit.
 - and
 - (b) Corroborative clinical evidence of infarction evidenced by at least one of the following:
 - (i) Symptoms of ischaemia
 - (ii) New or presumed new significant ST-T changes or new LBBB
 - (iii) Development of pathological Q waves
 - (iv) Imaging evidence of new loss of viable myocardium or new RWMA
 - (v) Intracoronary thrombus evident on angiography or at autopsy
- (2) Non-obstructive coronary arteries on angiography:
 - Defined as the absence of obstructive CAD on angiography, (i.e. no coronary artery stenosis $\geq 50\%$), in any potential infarct-related artery.
 - This includes both patients with:
 - normal coronary arteries (no stenosis $> 30\%$)
 - mild coronary atheromatosis (stenosis $> 30\%$ but $< 50\%$).
- (3) No clinically overt specific cause for the acute presentation:
 - At the time of angiography, the cause and thus a specific diagnosis for the clinical presentation is not apparent.
 - Accordingly, there is a necessity to further evaluate the patient for the underlying cause of the MINOCA presentation.

LBBB, left bundle branch block. RWMA, regional wall motion abnormality.

myocarditis or pulmonary embolism, the diagnosis of MINOCA is applicable. The rationale for establishing MINOCA as a clinical diagnosis includes: (i) providing a common nomenclature for this group of patients who are often overlooked in contemporary clinical practice, (ii) encouraging routine evaluation for underlying causes in these patients, and (iii) stimulating further studies into its responsible mechanisms, outcomes, and most appropriate management strategies. Myocardial infarction with non-obstructive coronary arteries should be considered as a 'working diagnosis', analogous to heart failure, and thus prompts further evaluation regarding its underlying mechanism(s).

Acute myocardial infarction clinical criteria

As summarized in Table 1, the AMI criteria for MINOCA constitute those defined by the well-established 'Third Universal Definition of Myocardial Infarction'.¹ This contemporary definition is focused upon a positive cardiac biomarker and corroborative clinical evidence of an AMI. Compared with previous AMI definitions (predating the troponin assay), the criteria are more sensitive, and may be further enhanced with the introduction of ultra-high-sensitivity troponin assays, although the specificity may be compromised. Hence, the emphasis of corroborating the bioassay findings with the clinical presentation is of paramount importance in the definition. Moreover, this definition introduces the concept of types of infarcts,¹ reflecting the underlying cause of the AMI. Type-1 (spontaneous) and type 2 (supply-demand mismatch, including coronary artery spasm) are most relevant to this document.

A potential problem with current AMI criteria is their central focus upon troponins, since clinicians encounter elevated troponins in clinical scenarios other than AMI. A detailed discussion of troponins in the diagnosis of AMI is beyond the scope of the present paper, but has been detailed in other reviews.¹¹

There are three central concepts in interpreting troponins in the context of a coronary angiogram showing non-obstructive coronary arteries. First, it should be appreciated that cardiac troponins are 'organ specific' and not 'disease specific'. An elevated cardiac troponin is not necessarily indicative of an AMI but reflects myocardial injury or necrosis. One example of a disease process causing myocardial injury and troponin elevation without an AMI is pulmonary embolism. Thus, there must be corroborative clinical evidence in addition to elevated cardiac troponins to establish the diagnosis of AMI, including MINOCA. However, there is no imaging technology, including cardiac magnetic resonance (CMR) imaging, which can definitively exclude an ischaemic cause of troponin elevation (see 'MINOCA with normal cardiac MR imaging'). Only a pathologic examination is definitive. Second, rarely the troponin assays may provide spurious results due to analytical issues such as heterophilic antibodies.¹¹ Finally, there are several differential diagnoses for MINOCA, which may arise from both coronary and non-coronary mechanisms as listed in Table 2 and summarized later in this paper. Certainly, the presence of coronary atherosclerotic obstructions, does not exclude other non-cardiac causes of troponin rise.

Angiographic criteria

The angiographic criteria for 'non-obstructive coronary arteries' detailed in the MINOCA definition utilizes the conventional cut-off of $< 50\%$ stenosis, which is consistent with contemporary angiographic guidelines.¹² This conventional threshold is somewhat arbitrary and there is substantial inter- and intra-observer variability in visual estimation of angiographic stenosis. Furthermore, the dynamic pathophysiological nature of an acute coronary syndrome may result in significant angiographic changes arising from fluctuating coronary vasomotor tone and the unstable coronary plaque (including a shifting thrombotic mass, plaque haemorrhage, and washout of plaque contents).¹³

Table 2 Potential causes of an elevated troponin adapted from Agewall et al.¹¹

- | |
|---|
| <p>(1) Coronary causes</p> <ul style="list-style-type: none"> • Plaque rupture or erosion • Coronary artery spasm • Spontaneous coronary dissection • Acute aortic dissection with coronary extension • Coronary microvascular disorders • Spontaneous coronary thrombosis—thrombophilia disorders • Coronary emboli • Sympathomimetic agents—cocaine, methamphetamines <p>(2) Non-coronary causes</p> <p>(a) Associated with cardiac disorders</p> <ul style="list-style-type: none"> • Myocarditis • Takotsubo cardiomyopathy • Cardiomyopathies • Cardiac trauma • Strenuous exercise • Tachyarrhythmias • Cardiotoxins—chemotherapeutic agents <p>(b) Associated with extra-cardiac disorders</p> <ul style="list-style-type: none"> • Stroke • Pulmonary embolism • Sepsis • Adult respiratory distress syndrome • End-stage renal failure |
|---|

Some authors have restricted consideration to patients with angiographically normal coronary arteries with the intention of delineating those patients in whom atherosclerosis does not play a role in the AMI. Unfortunately, this approach is not feasible since intravascular ultrasound studies have frequently demonstrated significant atherosclerotic burden in patients with 'normal coronary angiography'.¹⁴ Furthermore, this 'non-atherosclerotic AMI' approach is limited by (i) the infrequent use of intravascular ultrasound and other intracoronary atherosclerotic imaging methods in routine clinical practice, (ii) coronary spasm and thrombosis may occur in the presence/absence of atherosclerosis, and (iii) coronary atherosclerosis may be an 'innocent bystander' in non-coronary causes of an elevated troponin (myocarditis and takotsubo cardiomyopathy). Coronary CT angiography is used more commonly and may be considered for detection of atherosclerosis when intracoronary imaging is not performed during the initial diagnostic angiogram. The finding of angiographically smooth coronary arteries does not preclude an aetiological role of thrombotic disease in MINOCA. Further, non-obstructive atherosclerosis may pre-date development of conditions not believed to be atherosclerotic in aetiology, such as myocarditis and takotsubo cardiomyopathy. Coronary artery spasm may be the underlying cause of MI in patients with or without atherosclerosis. Therefore, we believe the best approach is to define MINOCA on the basis of absence of a potentially obstructive stenosis on coronary angiography rather than on the presence or absence of any coronary atherosclerosis. Despite these limitations, from a future research perspective it is prudent to delineate patients with mild coronary atheromatosis on angiography from those with 'normal vessels' since it may have diagnostic and/or prognostic implications.

Given the importance of the clinical context in making a diagnosis of MINOCA and the consideration that it is a 'working diagnosis', it is not appropriate to use this label when a specific clinical diagnosis is apparent. For example, a young person with a recent viral illness presenting with positional chest pain, diffuse ST elevation, troponin elevation, and found to have normal angiography should be diagnosed as clinically suspected myocarditis with or without associated pericarditis according to ESC 2013 Task Force criteria (Table 3) rather than MINOCA.

Clinical characteristics

Patients with MINOCA are usually younger than those with obstructive CAD and have a different sex distribution. While in patients with obstructive CAD, the incidence of AMI is greater in young and middle-aged males than females, in MINOCA there is only a slight male preponderance.^{15,16} This suggests that the factors underlying MINOCA are different and that sex and/or hormonal influences may play a role. Myocardial infarction with non-obstructive coronary arteries may present with or without ST segment elevation on the ECG regardless of the underlying aetiology. The likelihood of finding non-obstructive CAD is similar between these two presentations for women, and lower in NSTEMI than STEMI among men.¹⁵

Clinical assessment

As stated above, MINOCA is a working diagnosis and should lead the treating physician to investigate underlying causes, analogous to heart failure. This section outlines suggestions for diagnostic testing in order to identify or exclude potential aetiologies discussed in 'Differential diagnosis'. Left ventriculography or echocardiography should be performed in the acute setting to assess wall motion. This will aid the clinician in determining whether takotsubo cardiomyopathy is a diagnostic consideration.

Cardiac magnetic resonance imaging is the key diagnostic tool to be employed in MINOCA patients. Late gadolinium enhancement (LGE), when present, permits localization of the area of myocardial damage and provides insight into mechanisms. For example, an area of LGE in the subendocardium suggests an ischaemic cause of injury, although it does not identify the particular cause of ischaemia (plaque disruption, vasospasm, thromboembolism, or dissection), while a sub-epicardial localization speaks in favour of cardiomyopathy. In other patients, a non-ischaemic appearance of LGE may suggest a diagnosis of myocarditis or an infiltrative disorder. Imaging for myocardial oedema and contractile function may also help localize the area of injury, though with less mechanistic insight.

Intracoronary imaging at the time of cardiac catheterization with intravascular ultrasound (IVUS) or optical coherence tomography (OCT) may be useful to identify atherosclerotic plaque disruption and plaque erosion as well as coronary dissection or thrombosis, which may not have been appreciated during angiography. Further research is needed to understand the potential benefit of routine application of intracoronary imaging at the time of coronary catheterization in patients with MINOCA. Coronary CT angiography is another possibility to obtain further information regarding

Table 3 Definition of clinically suspected myocarditis according to the ESC 2013 Myocarditis Task Force³⁶

Presence of ≥ 1 clinical presentation and ≥ 1 diagnostic criteria from different categories, in the absence of:

- (1) Angiographically detectable CAD (coronary stenosis $\geq 50\%$)
 - (2) Known pre-existing cardiovascular disease or extra-cardiac causes that could explain the syndrome (e.g. valve disease, congenital heart disease, etc.).
 - (3) If the patient is asymptomatic ≥ 2 diagnostic criteria should be met.
- Diagnosis of certainty and aetiological diagnosis of myocarditis requires EMB (histology, immunohistology, infectious agents by PCR)

Clinical presentations

Acute coronary syndrome-like, with or without normal global or regional left ventricular (LV) and/or right ventricular (RV) dysfunction on echocardiography or CMR, with or without increased troponin (Tn)T/Tnl (that may have a time course similar to AMI or a prolonged and sustained release over several weeks or months).

New onset or worsening unexplained heart failure.

Chronic unexplained heart failure of > 3 months duration.

Life-threatening unexplained condition (including life-threatening arrhythmias and aborted sudden death, cardiogenic shock, severely impaired left ventricular function).

Diagnostic criteria

(1) ECG/Holter/stress test features

newly abnormal 12 lead ECG and/or Holter and/or stress testing, any of the following: I to III degree atrioventricular block, or bundle branch block, ST/T wave change, sinus arrest, ventricular tachycardia or fibrillation and asystole, atrial fibrillation, reduced R wave height, intraventricular conduction delay (widened QRS complex), abnormal Q waves, low voltage, frequent premature beats, and supraventricular tachycardia

(2) Myocardiocytolysis markers

elevated cardiac troponins

(3) Functional and structural abnormalities on cardiac imaging (echo/angio/CMR)

new, otherwise unexplained LV and/or RV structure and function abnormality.

(4) Tissue characterization by CMR

oedema and/or LGE of classical myocarditic pattern (according to Lake-Louise criteria).³⁷

underlying atherosclerosis after the acute angiogram but does not identify plaque rupture or erosion.

We recommend that clinicians consider pulmonary embolism as a possible cause of myocardial damage and exclude this diagnosis with D-dimer testing (usually however also elevated in the setting of AMI) and/or computed tomography (CT) pulmonary angiography as appropriate.¹⁷

However, no pulmonary embolism was found among 100 consecutive patients with MINOCA who underwent CT pulmonary angiography in one series.¹⁸ Furthermore, it is important to consider type-2 AMI¹ causes, in which a condition other than coronary plaque instability contributes to an imbalance between myocardial oxygen supply and demand and cause myocardial necrosis, such as tachyarrhythmia, haemorrhage, sepsis, and hypertensive crisis, as potential causes of MINOCA.

After considering clinically apparent diagnoses, the most common causes of MINOCA that the treating clinician must consider are plaque rupture or erosion, coronary artery spasm, thromboembolism, coronary dissection, takotsubo cardiomyopathy, unrecognized myocarditis, and other forms of type-2 myocardial infarction.

Aetiologic differential diagnosis

Plaque disruption

Atherosclerotic plaque disruption is a frequent cause of MINOCA. Plaque disruption is comprised within type-1 AMI in the Universal Definition of Myocardial Infarction, even when no thrombus can be found.¹ Within the Universal definition document, MINOCA comprises 5–20% of all type-1 AMI cases. The term disruption encompasses imaging and pathologic findings of plaque rupture,

ulceration, or erosion. Intraplaque haemorrhage may also play a role. Two independent studies using intravascular ultrasound identified plaque rupture or ulceration in $\sim 40\%$ of patients with MINOCA.^{19,20} Higher resolution intracoronary imaging (e.g. optical coherence tomography) would likely show an even higher prevalence of disrupted plaque but this technique has not been routinely applied in controlled studies within the MINOCA population. Plaque erosion has also been reported in MINOCA and is characterized by thrombus superimposed on plaque with an intact fibrous cap or without a fibrous cap. Calcified nodule with thrombus has also been suggested as a cause of AMI on intracoronary imaging.²¹ Based on CT angiography, the plaque burden in MINOCA patients and healthy controls is similar; however, this technique does not assess for disruption of the plaque. Plaque disruption may occur in areas of the vessel which appear normal on conventional angiography.²² However, some degree of atherosclerosis, even if minimal, is typically seen on coronary angiography in patients with disrupted plaques.

Myonecrosis in MINOCA with plaque disruption is mediated by thrombosis, thromboembolism, superimposed vasospasm, or a combination of these processes. One theory that has been proposed as an explanation for MINOCA in the presence of verified myocardial infarction is spontaneous thrombolysis or autolysis of a coronary thrombosis. Spontaneous thrombolysis is thought to be an endogenous protective mechanism against thrombus formation even in the presence of a ruptured coronary plaque.²³ Indeed, CMR imaging may show large areas of myocardial oedema with or without small areas of necrosis among patients with MINOCA and plaque disruption, suggesting that flow was compromised transiently in a larger vessel.¹⁹ The theory that spontaneous coronary thrombolysis rather than vasospasm leads to this appearance can

Table 4 Diagnostic work-up cardiac thromboembolism

Patient history	Atrial fibrillation, cardiomyopathy, prosthetic valve, prothrombotic risk factors, (cardiac) tumour, valvular heart disease, recent endocarditis, recent TVT or pulmonary embolism, concomitant stroke, or systemic embolism
Signs	Fever, signs of systemic thromboembolism
Laboratory analysis	Inflammatory markers, factor V Leiden, protein C, protein S, lupus anticoagulant, anti-cardiolipin antibodies, INR (in patients on vitamin K antagonists), and blood cultures
Echocardiography	Left ventricular function and ventricular thrombus, myxoma and papillary fibroelastoma and other cardiac tumours, assessment of atrial shunt, valvular heart disease with particular focus on signs of endocarditis, calcified valves, mobile plaques in ascending aorta, right-to-left shunt (microbubbles) to look for patent foramen ovale; consider transoesophageal echocardiography to look for patent foramen ovale
Coronary angiography	Non-occluded coronary arteries or distal stops, intervention-related air emboli. Intravascular ultrasound or OCT may be useful to identify atherosclerotic plaque disruption and plaque erosion as well as coronary dissection or thrombosis, which may not have been appreciated during angiography, in particular in patients with signs of atherosclerosis

neither be dismissed nor proved, and both may play a role. In other cases of MINOCA with plaque disruption, CMR imaging shows a smaller, well-defined area of LGE, subtended by a smaller vessel, suggesting that embolization of atherothrombotic debris from the disruption site is the most likely mechanism of myonecrosis.¹⁹

Thrombosis and/or thromboembolism almost certainly play a major role in pathogenesis of MINOCA with plaque disruption. Therefore, dual antiplatelet therapy is recommended for 1 year followed by lifetime single antiplatelet therapy for patients with suspected or confirmed plaque disruption and MINOCA.³ Because disruption occurs on a background of non-obstructive CAD, statin therapy is also recommended even if only a minor degree of atherosclerosis is found.

The prognosis of patients with plaque disruption as the cause of MINOCA has not been investigated in comparison with other subtypes of MINOCA. However, the finding of plaque rupture on OCT was associated with major adverse cardiac events in a cohort of patients undergoing OCT for acute coronary syndrome.¹⁰ Overall, the risk of recurrent myocardial infarction or death in MINOCA patients is ~2% up to 12 months.^{24–29}

Coronary artery spasm

Coronary artery spasm may potentially contribute to the pathogenesis of AMI in patients with obstructive CAD and particularly warrants close consideration in those with MINOCA. It reflects a vascular smooth muscle hyper-reactivity to endogenous vasospastic substances (as in vasospastic angina) but may also occur in the context of exogenous vasospastic agents (e.g. cocaine or metamphetamines).³⁰ Provocative spasm testing has demonstrated inducible spasm in 27% of patients with MINOCA suggesting that it is a common and an important pathogenetic mechanism in MINOCA.³¹ Considering that nitrates and especially calcium channel blockers are effective therapies for coronary artery spasm, with the latter shown to prevent cardiac events in vasospastic angina, this diagnosis and treatment needs to be carefully contemplated.^{32,33}

Myocardial infarction with non-obstructive coronary arteries may be the *de novo* presentation for patients with vasospastic angina, or an interim event in those with the chronic established form of the disorder. Clinical features of vasospastic angina that may allude to the diagnosis in patients with MINOCA include recurrent episodes of rest angina that promptly respond to short-acting nitrates,

especially if associated with transient ischaemic ECG changes and demonstrating a circadian pattern (typically as nocturnal angina). Thus, a diagnosis of vasospastic angina can be made if spontaneous episodes of rest angina are associated with ST-segment changes that respond promptly to short-acting nitrates. However, spontaneous episodes are infrequently documented therefore requiring provocative spasm testing to be undertaken if the diagnosis is to be pursued. This has been safely performed by experienced clinical researchers in selected patients with a recent AMI;³⁴ however, the procedure should generally be avoided in the acute phase of AMI. Microvascular spasm is also a potential cause of MINOCA since elevated troponins have been detected via ultrasensitive assays following provocative spasm testing, despite the absence of inducible large vessel spasm.³⁵ More research is required into the general safety and prognostic value of provocative spasm testing in MINOCA.

Coronary thromboembolism

Thrombosis may be a contributory mechanism to AMI in the setting of plaque disruption or coronary artery spasm, or may be the cause of MI in the absence of these factors. Coronary thrombosis may arise from hereditary or acquired thrombotic disorders and coronary emboli may occur from coronary or systemic arterial thrombi. Hereditary thrombophilia disorders include Factor V Leiden thrombophilia, Protein S and C deficiencies. Thrombophilia screening studies in patients with MINOCA have reported a 14% prevalence of these inherited disorders.³¹ Acquired thrombophilia disorders should also be considered such as the antiphospholipid syndrome and myeloproliferative disorders, although these have not been systematically investigated in MINOCA.

Coronary emboli may occur in the context of the above thrombophilia disorders or other predisposing hypercoagulable states such as atrial fibrillation and valvular heart disease. Emboli may arise from non-thrombotic sources also including valvular vegetations, cardiac tumours (e.g. myxoma and papillary fibroelastoma), calcified valves, and iatrogenic air emboli.

The clinical assessment of coronary thromboembolic disorders, including paradoxical embolism, as a potential cause of MINOCA is summarized in Table 4. Although the prevalence of coronary thromboembolism in MINOCA is thought to be low, this in part may be due to inadequate screening. For example, pruned small coronary vessels obstructed with thrombi or emboli may be missed on

angiography. Aortic valve disease (ectatic calcification, vegetation, or papillary fibroelastoma) may not be noted and thrombophilia disorders may not even be assessed. The importance of identifying these potential causes is the availability of targeted therapies, although their use in the context of MINOCA is limited.

Coronary dissection

Spontaneous coronary dissection typically causes an AMI via luminal obstruction, although this may not always be apparent on coronary angiography, prompting a diagnosis of MINOCA.³⁸ Intramural haematoma of the coronary arteries without intimal tear presents similarly.³⁹ Intracoronary imaging is pivotal in making this diagnosis.⁴⁰ The condition is more common among women. The reasons for the occurrence of coronary dissection are still unclear but fibromuscular dysplasia is present in other vascular beds in the majority of cases when screening is performed.⁴¹ Changes in the intima-media composition due to hormones, pregnancy, and delivery have also been implicated. Most dissections occur in the absence of atherosclerotic disease and in these cases, statin therapy is not recommended.⁴² A conservative management approach is advocated because coronary intervention and stenting tend to cause propagation of the dissection and outcomes are acceptable with medical management.⁴³

Takotsubo cardiomyopathy

Takotsubo cardiomyopathy⁴⁴ often presents as an acute coronary syndrome with ST segment changes.^{45,46} The transient nature of left ventricular dysfunction has puzzled physicians worldwide.⁴⁷ Clinical presentation is characterized by acute, reversible heart failure associated with myocardial stunning, in the absence of occlusive CAD.⁴⁸ The prognosis is generally good although several studies have demonstrated significant complications in the acute phase^{49–52} and more studies with long-term follow-up are required. The revised Mayo clinic diagnostic criteria include: (1) Transient hypokinesia, akinesia, or dyskinesia of the left ventricular mid segments with or without apical involvement; the regional wall motion abnormalities extend beyond a single epicardial vascular distribution; a stressful trigger is often, but not always present. (2) The absence of obstructive CAD or angiographic evidence of acute plaque rupture (though it is recognized that obstructive CAD may pre-date the Takotsubo event in some cases). (3) New electrocardiographic abnormalities (either ST-segment elevation and/or T-wave inversion) or modest elevation in cardiac troponin. (4) The absence of pheochromocytoma and myocarditis.^{48,49} Distinguishing takotsubo cardiomyopathy from acute myocarditis and AMI due to occlusive CAD may be challenging. Troponin elevations are relatively lower in takotsubo cardiomyopathy, compared with AMI. Takotsubo cardiomyopathy usually, but not exclusively, affects postmenopausal women. Some patients present late and may no longer have the typical left ventricular function pattern. Milder forms also likely exist. Cardiac magnetic resonance imaging performed early after admission to hospital will in many cases help to establish the diagnosis based on a typical pattern of oedema, emphasizing the importance of performing CMR in MINOCA.

The pathophysiological mechanisms responsible for takotsubo cardiomyopathy are complex and may vary between patients. These mechanisms have been discussed in recent reviews,^{47,48,53,54} so that a detailed analysis of these is beyond the scope of this position paper.

Furthermore, despite the rapid growth of the medical literature in this area over the past two decades, no randomized trials exist to define the optimal management of these patients. Empiric therapeutic strategies may include the avoidance of sympathomimetic agents, the use of cardio-selective β -blockers in those with left ventricular outflow tract obstruction, ACE inhibitors in those with persistent left ventricular dysfunction, mechanical support in those with cardiogenic shock, and consideration of short-term anti-thrombotic medications given potential prothrombotic mechanisms. However, it must be recognized that the distinction between takotsubo cardiomyopathy and other forms of MINOCA may be challenging in some cases.

Myocarditis

Since clinical presentation is polymorphic, the 2013 ESC Task Force has introduced rigorous criteria for clinically suspected myocarditis³⁶ that are outlined in *Table 3*. Certain diagnosis of myocarditis and of its specific aetiopathogenetic forms can only be achieved by endomyocardial biopsy (EMB).³⁶

This condition has a variable presentation including an acute coronary syndrome-like presentation in the presence/absence of ventricular dysfunction and without obstructive CAD (*Table 3*). In patients with a classical myocarditis presentation, the specific diagnosis of myocarditis should be made before or at coronary angiography, but in many cases the diagnosis will not be clinically apparent and the working diagnosis of MINOCA should be made until specific testing is performed.

The prevalence of myocarditis among patients with a clinical diagnosis of MINOCA varies based on the populations studied, with a prevalence of 33% in a recent meta-analysis.⁵⁵ The most common cause of biopsy-proven myocarditis is viral infection, confirmed with polymerase chain reaction (PCR) assay of the pathogen DNA/RNA on EMB. Other causes of myocarditis are immune-mediated diseases, endocrine diseases, drugs, and toxins.^{36,56–58} Autoimmune myocarditis may occur with exclusive cardiac involvement or in the context of systemic autoimmune disorders, e.g. systemic lupus erythematosus and is infection-negative by PCR on EMB.^{36,59,60}

The initial investigation of suspected myocarditis should include CMR imaging. Although this non-invasive investigation compares favourably with the gold-standard technique of EMB,^{36,56,61,62} only EMB provides the opportunity of identifying the underlying cause for the myocarditis. Lurz *et al.*⁶³ reported that CMR imaging detected 79% of EMB-confirmed myocarditis. Also, in the new ESC guidelines on Pericardial disease CMR is recommended for the confirmation of myocardial involvement (myocarditis) as a Class I recommendation.⁶⁴

The importance of diagnosing myocarditis in patients with MINOCA relates to its prognosis and treatment. Although myocarditis resolves over a 2–4 weeks period in 50% of patients, 12–25% may acutely deteriorate and either succumb to fulminant heart failure or progress onto end-stage dilated cardiomyopathy requiring heart transplantation.³⁶ Giant cell myocarditis is particularly associated with a poor prognosis.^{36,57} Thus patients with myocarditis may require intravenous inotropic agents and/or mechanical circulatory support as a bridge to recovery or transplantation,³⁶ and do not require anti-ischaemic therapies utilized in other causes of MINOCA. The diagnosis of biopsy-proven infection-negative myocarditis is the basis for safe immunosuppression, that is indicated in specific

autoimmune forms, such as in giant cell myocarditis, which is associated with a poor prognosis,^{36,57} cardiac sarcoidosis, eosinophilic myocarditis, as well as in lymphocytic forms refractory to standard therapy.³⁶ EMB also provides differential diagnosis with other causes of MINOCA, including takotsubo cardiomyopathy.

Other forms of type-2 acute myocardial infarction

Type 2 AMI is defined as myocardial cell necrosis due to supply–demand mismatch, characterized by significant increase and/or decrease in troponins with at least one value above the 99th percentile of a normal reference population in the absence of evidence for coronary plaque rupture in addition to at least one of the other criteria for AMI.¹ Major determinants of myocardial oxygen demand include systolic wall tension, contractility, and heart rate, while myocardial oxygen supply is conveyed by coronary blood flow and oxygen content. Conditions underlying type-2 AMI include anaemia, tachy- brady-arrhythmia, respiratory failure, hypotension, shock, severe hypertension with or without left ventricular hypertrophy, severe aortic valve disease, heart failure, cardiomyopathy, and injurious effects of toxins (e.g. sepsis) and pharmacological agents (e.g. catecholamines).⁶⁵ Importantly, all these conditions may also unmask underlying obstructive CAD. Among patients with non-obstructive CAD, a profound supply–demand mismatch should be present to consider type-2 AMI. Therapeutically, the condition underlying the oxygen supply–demand mismatch is to be reversed if possible. Furthermore, aspirin and β -blockers may be useful.⁶⁶ There are at present no clinical trials addressing the treatment of type-2 AMI available and the patient population is very heterogeneous. Electrocardiogram findings in type-2 AMI have been found to be compatible with NSTEMI in 97% of the cases.⁶⁷ Application of specific secondary prevention measures must be considered in the context of the specific insult. For example, potent anti-thrombotic treatment of type-2 AMI would not be recommended when the precipitating cause of supply–demand mismatch is haemorrhage and a bleeding source has not yet been addressed.

Myocardial infarction with non-obstructive coronary arteries of uncertain aetiology

Cardiac magnetic resonance imaging criteria

Cardiac magnetic resonance imaging is a useful tool in MINOCA patients because it not only provides insights into potential causes but may also provide confirmation of the diagnosis of AMI. In particular, the presence and pattern of any LGE may point towards a vascular or non-vascular cause. However, 8–67% of patients with MINOCA have no evidence of LGE, myocardial oedema, or wall motion abnormalities on CMR.^{18,19,68–74} The MINOCA subgroup with normal CMR raises the question whether the raised troponin was a marker of myocardial injury or perhaps related to an alternate diagnosis. Late gadolinium enhancement on CMR imaging is able to detect as little as 1 g of infarcted myocardium with current techniques.⁷⁵ Thus some patients with normal CMR may have too little myonecrosis to be detected. Alternatively, the normal CMR appearance may be the result of a broader spatial distribution of myonecrosis. That is, necrotic myocytes may be distributed over a

larger area with no contiguous island of cell death of sufficient size to be detected by LGE imaging. Patients with normal CMR imaging do tend to have lower peak troponin values, though peak troponin >100 times the upper limit of normal may be observed in the absence of LGE.^{72,76} Myocardial oedema imaging also provides evidence of myocardial injury but is absent in patients with MINOCA and normal CMR. In the initial CMR studies, this may have occurred because the T2 imaging was undertaken late in the clinical course or the CMR sequences utilized were insensitive.⁵⁵ With the evolution of CMR techniques for imaging of myocardial oedema³⁷ and its routine performance in patients with MINOCA, further insights may be obtained in the future.

When CMR is normal and diagnostic evaluation as recommended herein does not reveal the mechanism of AMI, there is a diagnostic and therapeutic dilemma for clinicians. Unfortunately, there are no systematic investigations addressing this issue. From first principles, vasospastic angina, coronary plaque disruption, or thromboembolism may all potentially cause MINOCA with normal CMR imaging. In a series of patients with MINOCA who underwent both CMR and IVUS imaging, a subset of those with plaque disruption had a normal CMR (~25%).¹⁹ If intracoronary imaging had not been performed during cardiac catheterization, this diagnosis would have been missed. Furthermore, MINOCA studies undertaking provocative spasm testing or assessing microvascular dysfunction have not routinely performed before CMR. However, epicardial coronary artery spasm may produce transient transmural myocardial ischaemia that is associated with a small troponin rise.³⁴ An alternative consideration is that the troponin rise is not indicative of AMI and is instead due to other causes such as pulmonary embolism or myocarditis. These alternate causes should be reconsidered when CMR is normal.

In the absence of systematic evaluation of underlying mechanisms and clinical characteristics, any treatment recommendations remain empiric. We propose aspirin, statins and, in cases of vasospasm, calcium channel blockers as routine treatments since these would be of benefit for the potential underlying mechanisms of coronary plaque disruption, coronary spasm, and thromboembolism.

Knowledge gaps

We have highlighted that MINOCA is a heterogeneous entity with many potential aetiologies that need to be elucidated by an accurate and stringent commonly agreed diagnostic algorithm (*Figure 1*). Once such a diagnostic algorithm is widely accepted, a meticulous data collection into a large-scale register will be useful to provide a reliable estimate of the true prevalence and prognostic relevance of MINOCA. Furthermore, clinicians need to know whether and how treatment strategies translate into an improvement of cardiovascular end-points. The relatively low event rate in MINOCA means that the sample size in designing a clinical trial with hard end-points will necessarily be large and only accruable through a large cooperative effort. On the other hand, the identification of the study population needs to be extremely rigorous, as any drug or treatment that would be proved effective in the treatment of patients with a selective dysfunction (e.g. vasospasm) will not necessarily be effective in other subgroups (e.g. thromboembolism). In addition

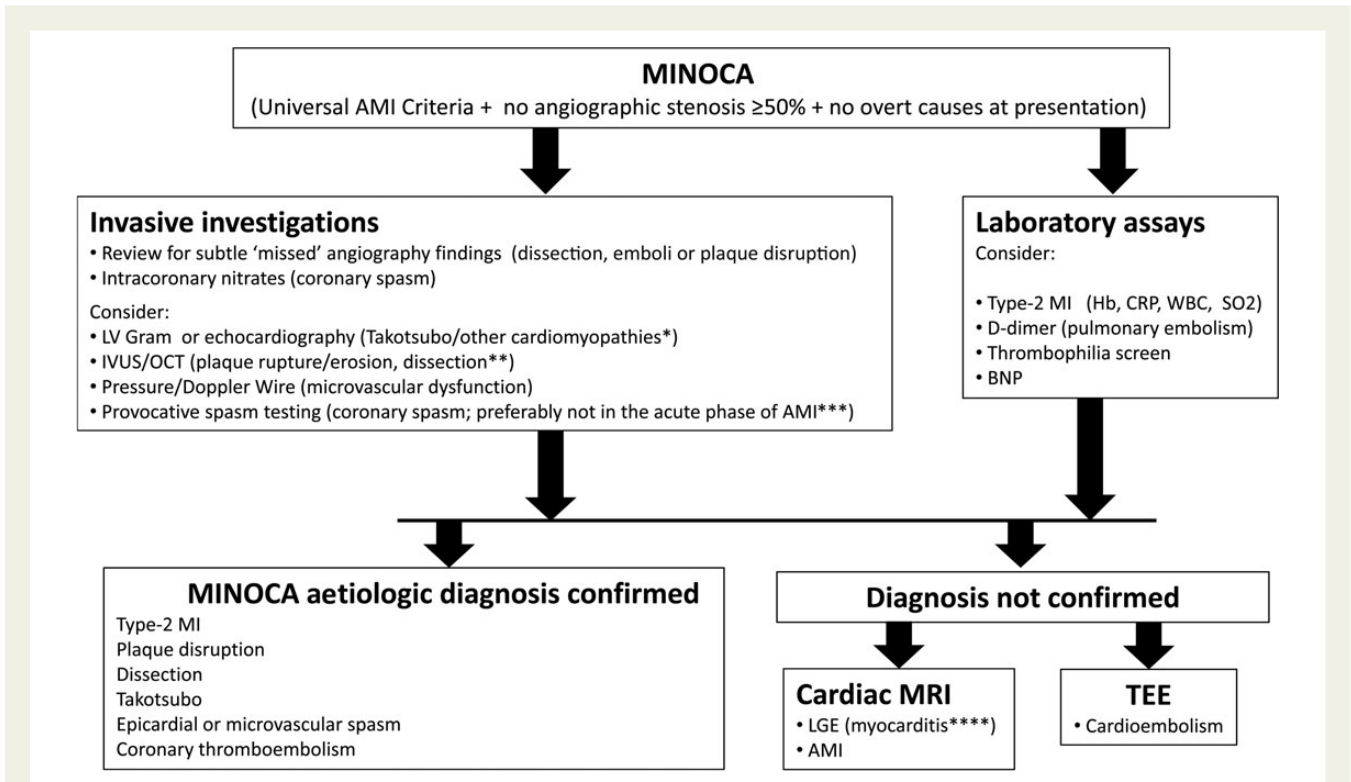


Figure 1 Recommended diagnostic and therapeutic algorithm for myocardial infarction with non-obstructive coronary arteries. * Takotsubo cardiomyopathy cannot be diagnosed with certainty in the acute phase as the definition requires follow-up imaging to document recovery of left ventricular function. In the authors' experience, some patients with apparent takotsubo have unrecognized ischaemic injury or myocarditis. We therefore recommend CMR when takotsubo cardiomyopathy is suspected. ** Plaque disruption (rupture, or erosion) should be suspected and intracoronary imaging considered whenever an alternate aetiology of the clinical presentation such as myocarditis or vasospasm has not been clearly identified, particularly among those patients with evidence of atherosclerosis on the coronary angiogram. Intravascular ultrasound and intracoronary optical coherence tomography frequently show more atherosclerotic plaque than may be appreciated on angiography. They also increase sensitivity for dissection. If intracoronary imaging is to be performed, it is appropriate to carry out this imaging at the time of the acute cardiac catheterization, after diagnostic angiography. Patients should be made aware of the additional information the test can provide and the small increase in risk associated with intracoronary imaging. *** Provocative testing for coronary artery spasm has been safely performed by experienced clinical researchers in selected patients with a recent acute myocardial infarction.³⁴ However, death cases have been reported (Per Tornvall Tornberg, personal communication) and this should not be a standard procedure among the patients, particularly in the acute phase. **** Clinically suspected myocarditis (no angiographic stenosis $\geq 50\%$ plus non-ischaemic pattern on cardiac magnetic resonance imaging) by ESC Task Force criteria.³⁶ Diagnosis of certainty and aetiological diagnosis of myocarditis requires EMB (histology, immunohistology, infectious agents by PCR). AMI, acute myocardial infarction; BNP, B-type natriuretic peptide; CRP, C-reactive protein; Hb, hemoglobin; IVUS, intravascular ultrasound; LGE, late gadolinium enhancement; LV, left ventricle; MRI, magnetic resonance imaging; OCT, optical coherence tomography; SO₂, Oxygen saturation; WBC, white blood cell count.

to the cardiovascular end-points, the impact of MINOCA on health status needs to be evaluated, such as persistent angina symptoms, impairment in quality of life, and depression. Intermediate end-points might be considered in the design of clinical trials, but the selection of such an intermediate endpoint is difficult. These multiple knowledge gaps in this evolving area of clinical research will no doubt provide important challenges for the years to come.

Summary

Myocardial infarction with non-obstructive coronary arteries is a heterogeneous entity with a prevalence of 1–13% of all patients

with a clinical diagnosis of AMI. There are several potential aetiologies that should be elucidated by a commonly agreed diagnostic algorithm, proposed herein. Rational treatment follows from an aetiological diagnosis, since therapy that may be appropriate for one cause (e.g. anticoagulation for thromboembolism or calcium channel blockers for vasospasm) will not be appropriate for all MINOCA patients. In MINOCA patients without an obvious aetiology after initial evaluation including echocardiography, we recommend a routine examination with CMR imaging. Multi-centre clinical trials of diagnostic and therapeutic strategies are needed. These results will have great impact on both treatment and prognosis of these patients.

Authors' contributions

All authors handled funding and supervision, acquired the data, conceived and designed the research, drafted the manuscript, and made critical revision of the manuscript for key intellectual content.

Conflict of interest: none declared.

References

- Thygesen K, Alpert JS, Jaffe AS, Simoons ML, Chaitman BR, White HD, Writing Group on the Joint ESC/ACCF/AHA/WHF Task Force for the Universal Definition of Myocardial Infarction, Thygesen K, Alpert JS, White HD, Jaffe AS, Katus HA, Apple FS, Lindahl B, Morrow DA, Chaitman BA, Clemmensen PM, Johanson P, Hod H, Underwood R, Bax JJ, Bonow RO, Pinto F, Gibbons RJ, Fox KA, Atar D, Newby LK, Galvani M, Hamm CW, Uretsky BF, Steg PG, Wijns W, Bassand JP, Menasché P, Ravkilde J, Ohman EM, Antman EM, Wallentin LC, Armstrong PW, Simoons ML, Januzzi JL, Nieminen MS, Gheorghiadu M, Filippatos G, Luepker RV, Fortmann SP, Rosamond WD, Levy D, Wood D, Smith SC, Hu D, Lopez-Sendon JL, Robertson RM, Weaver D, Tendera M, Bove AA, Parkhomenko AN, Vasilieva EJ, Mendis S, ESC Committee for Practice Guidelines (CPG). Third universal definition of myocardial infarction. *Eur Heart J* 2012;**33**: 2551–2567.
- Task Force on the management of ST-segment elevation acute myocardial infarction of the European Society of Cardiology (ESC), Steg PG, James SK, Atar D, Badano LP, Blömostrom-Lundqvist C, Borger MA, Di Mario C, Dickstein K, Ducrocq G, Fernandez-Aviles F, Gershlick AH, Giannuzzi P, Halvorsen S, Huber K, Juni P, Kastrati A, Knuuti J, Lenzen MJ, Mahaffey KW, Valgimigli M, van't Hof A, Widimsky P, Zahger D. ESC Guidelines for the management of acute myocardial infarction in patients presenting with ST-segment elevation. *Eur Heart J* 2012;**33**:2569–2619.
- Authors/Task Force Members, Roffi M, Patrono C, Collet JP, Mueller C, Valgimigli M, Andreotti F, Bax JJ, Borger MA, Brotons C, Chew DP, Gencer B, Hasenfuss G, Kjeldsen S, Lancellotti P, Landmesser U, Mehilli J, Mukherjee D, Storey RF, Windecker S. 2015 ESC Guidelines for the management of acute coronary syndromes in patients presenting without persistent ST-segment elevation: Task Force for the Management of Acute Coronary Syndromes in Patients Presenting without Persistent ST-Segment Elevation of the European Society of Cardiology (ESC). *Eur Heart J* 2016;**37**:267–315.
- Eugene Braunwald. Cardiovascular pharmacology: a look back and a glimpse into the future. *Eur Heart J Cardiovasc Pharmacother* 2015;**1**:7–9.
- DeWood MA, Spores J, Notske R, Mouser LT, Burroughs R, Golden MS, Lang HT. Prevalence of total coronary occlusion during the early hours of transmural myocardial infarction. *N Engl J Med* 1980;**303**:897–902.
- DeWood MA, Stifter WF, Simpson CS, Spores J, Eugster GS, Judge TP, Hinnen ML. Coronary arteriographic findings soon after non-Q-wave myocardial infarction. *N Engl J Med* 1986;**315**:417–423.
- Gehrie ER, Reynolds HR, Chen AY, Neelon BH, Roe MT, Gibler WB, Ohman EM, Newby LK, Peterson ED, Hochman JS. Characterization and outcomes of women and men with non-ST-segment elevation myocardial infarction and nonobstructive coronary artery disease: results from the Can Rapid Risk Stratification of Unstable Angina Patients Suppress Adverse Outcomes with Early Implementation of the ACC/AHA Guidelines (CRUSADE) quality improvement initiative. *Am Heart J* 2009;**158**:688–694.
- Kang WY, Jeong MH, Ahn YK, Kim JH, Chae SC, Kim YJ, Hur SH, Seong IW, Hong TJ, Choi DH, Cho MC, Kim CJ, Seung KB, Chung WS, Jang YS, Rha SW, Bae JH, Cho JG, Park SJ, Korea Acute Myocardial Infarction Registry Investigators. Are patients with angiographically near-normal coronary arteries who present as acute myocardial infarction actually safe? *Int J Cardiol* 2011;**146**:207–212.
- Larsen AI, Galbraith PD, Ghali WA, Norris CM, Graham MM, Knudtson ML. Characteristics and outcomes of patients with acute myocardial infarction and angiographically normal coronary arteries. *Am J Cardiol* 2005;**95**:261–263.
- Niccoli G, Scalone G, Crea F. Acute myocardial infarction with no obstructive coronary atherosclerosis: mechanisms and management. *Eur Heart J* 2015;**36**: 475–481.
- Agewall S, Giannitsis E, Jernberg T, Katus H. Troponin elevation in coronary vs. non-coronary disease. *Eur Heart J* 2011;**32**:404–411.
- Scanlon PJ, Faxon DP, Audet AM, Carabello B, Dehmer GJ, Eagle KA, Legako RD, Leon DF, Murray JA, Nissen SE, Pepine CJ, Watson RM, Ritchie JL, Gibbons RJ, Cheitlin MD, Gardner TJ, Garson A Jr, Russell RO Jr, Ryan TJ, Smith SC Jr. ACC/AHA guidelines for coronary angiography. A report of the American College of Cardiology/American Heart Association Task Force on practice guidelines (Committee on Coronary Angiography). Developed in collaboration with the Society for Cardiac Angiography and Interventions. *J Am Coll Cardiol* 1999;**33**:1756–1824.
- Toth GG, Toth B, Johnson NP, De Vroey F, Di Serafino L, Pyxaras S, Rusinaru D, Di Gioia G, Pellicano M, Barbato E, Van Mieghem C, Heyndrickx GR, De Bruyne B, Wijns W. Revascularization decisions in patients with stable angina and intermediate lesions: results of the international survey on interventional strategy. *Circ Cardiovasc Interv* 2014;**7**:751–759.
- Nissen SE, Gurley JC, Grines CL, Booth DC, McClure R, Berk M, Fischer C, DeMaria AN. Intravascular ultrasound assessment of lumen size and wall morphology in normal subjects and patients with coronary artery disease. *Circulation* 1991;**84**:1087–1099.
- Berger JS, Elliott L, Gallup D, Roe M, Granger CB, Armstrong PW, Simes RJ, White HD, Van de Werf F, Topol EJ, Hochman JS, Newby LK, Harrington RA, Califf RM, Becker RC, Douglas PS. Sex differences in mortality following acute coronary syndromes. *J Am Med Assoc* 2009;**302**:874–882.
- Shaw LJ, Shaw RE, Merz CN, Roe M, Granger CB, Armstrong PW, Simes RJ, White HD, Van de Werf F, Topol EJ, Hochman JS, Newby LK, Harrington RA, Califf RM, Becker RC, Douglas PS. Impact of ethnicity and gender differences on angiographic coronary artery disease prevalence and in-hospital mortality in the American College of Cardiology-National Cardiovascular Data Registry. *Circulation* 2008;**117**:1787–1801.
- Authors/Task Force Members, Konstantinides S, Torbicki A, Agnelli G, Danchin N, Fitzmaurice D, Galiè N, Gibbs JS, Huisman MV, Humbert M, Kucher N, Lang I, Lankei M, Lekakis J, Maack C, Mayer E, Menekou N, Perrier A, Pruszczyk P, Rasmussen LH, Schindler TH, Svitol P, Vonk Noordegraaf A, Zamorano JL, Zompatori M. 2014 ESC Guidelines on the diagnosis and management of acute pulmonary embolism: The Task Force for the Diagnosis and Management of Acute Pulmonary Embolism of the European Society of Cardiology (ESC) Endorsed by the European Respiratory Society (ERS). *Eur Heart J* 2014;**35**:3033–3069.
- Collste O, Sorensson P, Frick M, Agewall S, Daniel M, Henareh L, Ekenbäck C, Eurenius L, Guiron C, Jernberg T, Hofman-Bang C, Malmqvist K, Nagy E, Arheden H, Tornvall P. Myocardial infarction with normal coronary arteries is common and associated with normal findings on cardiovascular magnetic resonance imaging: results from the Stockholm Myocardial Infarction with Normal Coronaries study. *J Int Med* 2013;**273**:189–196.
- Reynolds HR, Srichai MB, Iqbal SN, Slater JN, Mancini GB, Feit F, Pena-Sing I, Axel L, Attubato M, Yatskar L, Kalhorn RT, Wood DA, Lobach IV, Hochman JS. Mechanisms of myocardial infarction in women without angiographically obstructive coronary artery disease. *Circulation* 2011;**124**:1414–1425.
- Ouldzein H, Elbaz M, Roncalli J, Cagnac R, Carrié D, Puel J, Alibelli-Chemarin MJ. Plaque rupture and morphological characteristics of the culprit lesion in acute coronary syndromes without significant angiographic lesion: analysis by intravascular ultrasound. *Ann Cardiol Angeiol (Paris)* 2012;**61**:20–26.
- Jia H, Abtahian F, Aguirre AD, Lee S, Chia S, Lowe H, Kato K, Yonetsu T, Vergallo R, Hu S, Tian J, Lee H, Park SJ, Jang YS, Raffel OC, Mizuno K, Uemura S, Itoh T, Kakuta T, Choi SY, Dauerman HL, Prasad A, Toma C, McNulty I, Zhang S, Yu B, Fuster V, Narula J, Virmani R, Jang IK. In vivo diagnosis of plaque erosion and calcified nodule in patients with acute coronary syndrome by intravascular optical coherence tomography. *J Am Coll Cardiol* 2013;**62**:1748–1758.
- Iqbal SN, Feit F, Mancini GB, Wood D, Patel R, Pena-Sing I, Attubato M, Yatskar L, Slater JN, Hochman JS, Reynolds HR. Characteristics of plaque disruption by intravascular ultrasound in women presenting with myocardial infarction without obstructive coronary artery disease. *Am Heart J* 2014;**167**:715–722.
- Kovacs IB1, Gorog DA, Yamamoto J. Enhanced spontaneous thrombolysis: a new therapeutic challenge. *J Thromb Thrombolysis* 2006;**21**:221–227.
- Bugiardini R, Manfrini O, De Ferrari GM. Unanswered questions for management of acute coronary syndrome: risk stratification of patients with minimal disease or normal findings on coronary angiography. *Arch Intern Med* 2006;**166**:1391–1395.
- Dey S, Flather MD, Devlin G, Brieger D, Gurfinkel EP, Steg PG, Fitzgerald G, Jackson EA, Eagle KA. Sex-related differences in the presentation, treatment and outcomes among patients with acute coronary syndromes: the Global Registry of Acute Coronary Events. *Heart* 2009;**95**:20–26.
- Larsen AI, Nilsen DW, Yu J, Mehran R, Nikolsky E, Lansky AJ, Caixeta A, Parise H, Fahy M, Cristea E, Witzenbichler B, Guagliumi G, Peruga JZ, Brodie BR, Dudek D, Stone GW. Long-term prognosis of patients presenting with ST-segment elevation myocardial infarction with no significant coronary artery disease (from the HORIZONS-AMI trial). *Am J Cardiol* 2013;**111**:643–648.
- Patel MR, Chen AY, Peterson ED, Newby LK, Pollack CV Jr, Brindis RG, Gibson CM, Kleiman NS, Saucedo JF, Bhatt DL, Gibler WB, Ohman EM, Harrington RA, Roe MT. Prevalence, predictors, and outcomes of patients with non-ST-segment elevation myocardial infarction and insignificant coronary artery disease: results from the Can Rapid risk stratification of Unstable angina patients Suppress Adverse outcomes with Early implementation of the ACC/AHA Guidelines (CRUSADE) initiative. *Am Heart J* 2006;**152**:641–647.
- Roe MT, Harrington RA, Prosper DM, Pieper KS, Bhatt DL, Lincoff AM, Simoons ML, Akkerhuis M, Ohman EM, Kitt MM, Vahanian A, Ruzyllo W, Karsch K, Califf RM, Topol EJ. Clinical and therapeutic profile of patients presenting

- with acute coronary syndromes who do not have significant coronary artery disease: the platelet glycoprotein IIb/IIIa in unstable angina: receptor suppression using integrilin therapy (PURSUIT) trial investigators. *Circulation* 2000;**102**:1101–1106.
29. Rossini R, Capodanno D, Lettieri C, Musumeci G, Limbruno U, Molfese M, Spatari V, Calabria P, Romano M, Tarantini G, Gavazzi A, Angiolillo DJ. Long-term outcomes of patients with acute coronary syndrome and nonobstructive coronary artery disease. *Am J Cardiol* 2013;**112**:150–155.
 30. Kaski JC, Crea F, Meran D, Rodriguez L, Araujo L, Chierchia S, Davies G, Maseri A. Local coronary supersensitivity to diverse vasoconstrictive stimuli in patients with variant angina. *Circulation* 1986;**74**:1255–1265.
 31. Pasupathy S, Air T, Dreyer RP, Tavella R, Beltrame JF. Systematic review of patients presenting with suspected myocardial infarction and non-obstructive coronary arteries (MINOCA). *Circulation* 2015;**131**:861–870.
 32. Yasue H, Takizawa A, Nagao M, Nishida S, Horie M, Kubota J, Omote S, Takaoka K, Okumura K. Long-term prognosis for patients with variant angina and influential factors. *Circulation* 1988;**78**:1–9.
 33. Ong P, Athanasiadis A, Sechtem U. Pharmacotherapy for coronary microvascular dysfunction. *Eur Heart J Cardiovasc Pharmacother* 2015;**1**:65–71.
 34. Ong P, Athanasiadis A, Hill S, Vogelsberg H, Voehringer M, Sechtem U. Coronary artery spasm as a frequent cause of acute coronary syndrome: the CASPAR (Coronary Artery Spasm in Patients With Acute Coronary Syndrome) Study. *J Am Coll Cardiol* 2008;**52**:523–527.
 35. Arrebola-Moreno AL, Arrebola JP, Moral-Ruiz A, Ramirez-Hernandez JA, Melgares-Moreno R, Kaski JC. Coronary microvascular spasm triggers transient ischemic left ventricular diastolic abnormalities in patients with chest pain and angiographically normal coronary arteries. *Atherosclerosis* 2014;**236**:207–214.
 36. Caforio ALP, Pankuweit S, Arbustini E, Basso C, Gimeno-Blanes J, Felix SB, Fu M, Heliö T, Heymans S, Jahns R, Klingel K, Linhart A, Maisch B, McKenna W, Mogensen J, Pinto YM, Ristic A, Schultheiss HP, Seggewiss H, Tavazzi L, Thiene G, Yilmaz A, Charron P, Elliott PM, European Society of Cardiology Working Group on Myocardial and Pericardial Diseases. Current state of knowledge on aetiology, diagnosis, management and therapy of myocarditis. A Position statement of the European Society of Cardiology Working Group on Myocardial and Pericardial Diseases. *Eur Heart J* 2013; **34**:2636–2648.
 37. Ferreira VM, Piechnik SK, Dall'armellina E, Karamitsos TD, Francis JM, Ntusi N, Holloway C, Choudhury RP, Kardos A, Robson MD, Friedrich MG, Neubauer S. T(1) mapping for the diagnosis of acute myocarditis using CMR: comparison to T-weighted and late gadolinium enhanced imaging. *JACC Cardiovasc Imaging* 2013; **6**:1048–1058.
 38. Alfonso F, Paulo M, Dutary J. Endovascular imaging of angiographically invisible spontaneous coronary artery dissection. *JACC Cardiovasc Interv* 2012;**5**:452–453.
 39. Antonsen L, Thaysen P, Jensen LO. Large coronary intramural hematomas: a case series and focused literature review. *Cardiovasc Revasc Med* 2015;**16**:116–123.
 40. Saw J, Mancini GB, Humphries K, Fung A, Boone R, Starovoytov A, Aymong E. Angiographic appearance of spontaneous coronary artery dissection with intramural hematoma proven on intracoronary imaging. *Catheter Cardiovasc Interv* 2015. doi: 10.1002/ccd.26022.
 41. Saw J, Aymong E, Sedlak T, Buller CE, Starovoytov A, Ricci D, Robinson S, Vuurmans T, Gao M, Humphries K, Mancini GB. Spontaneous coronary artery dissection: association with predisposing arteriopathies and precipitating stressors and cardiovascular outcomes. *Circ Cardiovasc Interv* 2014;**7**:645–655.
 42. Tweet MS, Hayes SN, Pitta SR, Simari RD, Lerman A, Lennon RJ, Gersh BJ, Khambatta S, Best PJ, Rihal CS, Gulati R. Clinical features, management, and prognosis of spontaneous coronary artery dissection. *Circulation* 2012;**126**:579–588.
 43. Tweet MS, Eleid MF, Best PJ, Lennon RJ, Lerman A, Rihal CS, Holmes DR Jr, Hayes SN, Gulati R. Spontaneous coronary artery dissection: revascularization versus conservative therapy. *Circ Cardiovasc Interv* 2014;**7**:777–786.
 44. Tsuchihashi K, Ueshima K, Uchida T, Oh-mura N, Kimura K, Owa M, Yoshiyama M, Miyazaki S, Haze K, Ogawa H, Honda T, Hase M, Kai R, Morii I. Angina Pectoris-Myocardial Infarction Investigations in Japan. Transient left ventricular apical ballooning without coronary artery stenosis: a novel heart syndrome mimicking acute myocardial infarction. *J Am Coll Cardiol* 2001;**38**:11–18.
 45. Bybee KA, Kara T, Prasad A, Lerman A, Barsness GW, Wright RS, Rihal CS. Systematic review: transient left ventricular apical ballooning: a syndrome that mimics ST-segment elevation myocardial infarction. *Ann Int Med* 2004;**141**:858–865.
 46. Prasad A. Apical ballooning syndrome: an important differential diagnosis of acute myocardial infarction. *Circulation* 2007;**115**:e56–e59.
 47. Pelliccia F, Greco C, Vitale C, Rosano G, Gaudio C, Kaski JC. Takotsubo (stress cardiomyopathy). *Am J Med* 2014;**127**:699–704.
 48. Prasad A, Lerman A, Rihal CS. Apical ballooning syndrome (Tako-Tsubo or stress cardiomyopathy): a mimic of acute myocardial infarction. *Am Heart J* 2008;**155**:408–417.
 49. Madhavan M, Rihal CS, Lerman A, Prasad A. Acute heart failure in apical ballooning syndrome (Tako-Tsubo/stress cardiomyopathy): clinical correlates and Mayo Clinic risk score. *J Am Coll Cardiol* 2011;**57**:1400–1401.
 50. Citro R, Rigo F, D'Andrea A, Ciampi Q, Parodi G, Provenza G, Piccolo R, Mirra M, Zito C, Giudice R, Patella MM, Antonini-Canterin F, Bossone E, Piscione F, Salerno-Uriarte J, Tako-Tsubo Italian Network Investigators. Echocardiographic correlates of acute heart failure, cardiogenic shock, and in-hospital mortality in tako-tsubo cardiomyopathy. *JACC Cardiovasc Imaging* 2014;**7**:119–129.
 51. Elesber AA, Prasad A, Lennon RJ, Wright RS, Lerman A, Rihal CS. Four-year recurrence rate and prognosis of the apical ballooning syndrome. *J Am Coll Cardiol* 2007; **50**:448–452.
 52. Sharkey SW, Wendenburg DC, Lesser JR, Maron MS, Hauser RG, Lesser JN, Haas TS, Hodges JS, Maron BJ. Natural history and expansive clinical profile of stress (tako-tsubo) cardiomyopathy. *J Am Coll Cardiol* 2010;**55**:333–341.
 53. Nef HM, Mollmann H, Akashi YJ, Hamm CW. Mechanisms of stress (Takotsubo) cardiomyopathy. *Nat Rev Cardiol* 2010;**7**:187–193.
 54. Paur H, Wright PT, Sikkil MB, Tranter MH, Mansfield C, O'Gara P, Stuckey DJ, Nikolaev VO, Diakonov I, Pannell L, Gong H, Sun H, Peters NS, Petrou M, Zheng Z, Gorelik J, Lyon AR, Harding SE. High levels of circulating epinephrine trigger apical cardiodepression in a beta2-adrenergic receptor/Gi-dependent manner: a new model of Takotsubo cardiomyopathy. *Circulation* 2012;**126**:697–706.
 55. Tornvall P, Gerbaud E, Behaghel A, Chopard R, Collste O, Larauogoitia E, Leurent G, Meneveau N, Montaudon N, Perez-David E, Sörensson P, Agewall S. A meta-analysis of individual data regarding prevalence and risk markers for myocarditis and infarction determined by cardiac magnetic resonance imaging in myocardial infarction with non-obstructive coronary artery disease. *Atherosclerosis* 2015;**241**:87–91.
 56. Leone O, Veinot JP, Angelini A, Baandrup UT, Basso C, Berry G, Bruneval P, Burke M, Butany J, Calabrese F, d'Amati G, Edwards WD, Fallon JT, Fishbein MC, Gallagher PJ, Halushka MK, McManus B, Pucci A, Rodriguez ER, Saffitz JE, Sheppard MN, Steenbergen C, Stone JR, Tan C, Thiene G, van der Wal AC, Winters GL. 2011 consensus statement on endomyocardial biopsy from the Association for European Cardiovascular Pathology and the Society for Cardiovascular Pathology. *Cardiovasc Pathol* 2012;**21**:245–274.
 57. Caforio ALP, Marcolongo R, Jahns R, Fu M, Felix SB, Iliceto S. Immune-mediated and autoimmune myocarditis: clinical presentation, diagnosis and management. *Heart Fail Rev* 2013;**18**:715–732.
 58. Bock CT, Klingel K, Kandolf R. Human parvovirus B19-associated myocarditis. *N Engl J Med* 2010;**362**:1248–1249.
 59. Caforio ALP, Keeling PJ, Zachara E, Mestroni L, Camerini F, Mann JM, Bottazzo GF, McKenna WJ. Evidence from family studies for autoimmunity in dilated cardiomyopathy. *Lancet* 1994;**344**:773–777.
 60. Caforio AL, Mahon NG, Baig MK, Tona F, Murphy RT, Elliott PM, McKenna WJ. Prospective familial assessment in dilated cardiomyopathy. Cardiac autoantibodies predict disease development in asymptomatic relatives. *Circulation* 2007;**115**:76–83.
 61. Maron BJ, Towbin JA, Thiene G, Antzelevitch C, Corrado D, Arnett D, Moss AJ, Seidman CE, Young JB, American Heart Association, Council on Clinical Cardiology, Heart Failure and Transplantation Committee, Quality of Care and Outcomes Research and Functional Genomics and Translational Biology Interdisciplinary Working Groups, Council on Epidemiology and Prevention. Contemporary definitions and classification of cardiomyopathies. An American Heart Association Scientific statement from the Council on Clinical Cardiology, Heart Failure and Transplantation Committee, quality of Care and Outcome research and Functional Genomics and Translational Biology Interdisciplinary Working Groups: and Council on Epidemiology and Prevention. *Circulation* 2006;**113**:1807–1816.
 62. Elliott P, Andersson B, Arbustini E, Bilinska Z, Cecchi F, Charron P, Dubourg O, Kühl U, Maisch B, McKenna WJ, Monserrat L, Pankuweit S, Rapezzi C, Seferovic P, Tavazzi L, Keren A. Classification of the cardiomyopathies: a position statement from the European Society of Cardiology working group on myocardial and pericardial disease. *Eur Heart J* 2007;**29**:270–276.
 63. Lurz P, Eitel I, Adam J, Steiner J, Grothoff M, Desch S, Fuernau G, de Waha S, Sareban M, Luecke C, Klingel K, Kandolf R, Schuler G, Gutberlet M, Thiele H. Diagnostic performance of CMR imaging compared with EMB in patients with suspected myocarditis. *JACC Cardiovasc Imaging* 2012;**5**:513–524.
 64. Adler Y, Charron P, Imazio M, Badano L, Barón-Esquivias G, Bogaert J, Brucato A, Gueret P, Klingel K, Lionis C, Maisch B, Mayosi B, Pavić A, Ristic AD, Sabaté Tenas M, Seferovic P, Swedberg K, Tomkowski W. Document Reviewers: Achenbach S, Agewall S, Al-Attar N, Angel Ferrer J, Arad M, Asteggiano R, Bueno H, Caforio AL, Carerj S, Ceconi C, Evangelista A, Flachskampf F, Giannakoulas G, Gielen S, Habib G, Kolh P, Lambrinou E, Lancellotti P, Lazaros G, Linhart A, Meurin P, Nieman K, Piepoli MF, Pricer S, Roos-Hesslein J, Roubille F, Ruschitzka F, Sagristà Sauleda J, Sousa-Uva M, Uwe Voigt J, Luis Zamorano J. 2015 ESC Guidelines for the diagnosis and management of pericardial

- diseases: The Task Force for the Diagnosis and Management of Pericardial Diseases of the European Society of Cardiology (ESC) Endorsed by: The European Association for Cardio-Thoracic Surgery (EACTS). *Eur Heart J* 2015;**36**:2921–2964.
65. Sandoval Y, Smith SW, Thordsen SE, Apple FS. Supply/demand type 2 myocardial infarction. *J Am Coll Cardiol* 2014;**63**:2079–2087.
66. Lemos JA. Increasingly sensitive assays for cardiac troponins. *JAMA* 2013;**309**:2262–2269.
67. Saaby L, Poulsen TS, Hosbond S, Larsen TB, Pyndt Diederichsen AC, Hallas J, Thygesen K, Mickley H. Classification of myocardial infarction: frequency and features of type 2 myocardial infarction. *Am J Med* 2013;**126**:789–797.
68. Gerbaud E, Harcaut E, Coste P, Erickson M, Lederlin M, Labèque JN, Perron JM, Cochet H, DosSantos P, Durrieu-Jais C, Laurent F, Montaudon M. Cardiac magnetic resonance imaging for the diagnosis of patients presenting with chest pain, raised troponin, and unobstructed coronary arteries. *Int J Cardiovasc Imaging* 2012;**28**:783–794.
69. Stensaeth K, Fossum E, Hoffmann P, Mangschau A, Klow N. Clinical characteristics and role of early cardiac magnetic resonance imaging in patients with suspected ST-elevation myocardial infarction and normal coronary arteries. *Int J Cardiovasc Imaging* 2011;**27**:355–365.
70. Baccouche H, Mahrholdt H, Meinhardt G, Merher R, Voehringer M, Hill S, Klingel K, Kandolf R, Sechtem U, Yilmaz A. Diagnostic synergy of non-invasive cardiovascular magnetic resonance and invasive endomyocardial biopsy in troponin-positive patients without coronary artery disease. *Eur Heart J* 2009;**30**:2869–2879.
71. Assomull RG, Lyne JC, Keenan N, Gulati A, Bunce NH, Davies SW, Pennell DJ, Prasad SK. The role of cardiovascular magnetic resonance in patients presenting with chest pain, raised troponin, and unobstructed coronary arteries. *Eur Heart J* 2007;**28**:1242–1249.
72. Leurent G, Langella B, Fougerou C, Lentz PA, Larralde A, Bedossa M, Boulmier D, Le Breton H. Diagnostic contributions of cardiac magnetic resonance imaging in patients presenting with elevated troponin, acute chest pain syndrome and unobstructed coronary arteries. *Arch Cardiovasc Dis* 2011;**104**:161–170.
73. Chopard R, Jehl J, Dutheil J, Genon VD, Seronde MF, Kastler B, Schiele F, Meneveau N. Evolution of acute coronary syndrome with normal coronary arteries and normal cardiac magnetic resonance imaging. *Arch Cardiovasc Dis* 2011;**104**:509–517.
74. Laraudogoitia Zaldumbide E, Perez-David E, Larena JA, Velasco del Castillo S, Rumoroso Cuevas JR, Onaindía JJ, Lekuona Goya I, García-Fernández MA. The value of cardiac magnetic resonance in patients with acute coronary syndrome and normal coronary arteries. *Rev Esp Cardiol* 2009;**62**:976–983.
75. Masci PG, Bogaert J. Post myocardial infarction of the left ventricle: the course ahead seen by cardiac MRI. *Cardiovasc Diagn Ther* 2012;**2**:113–127.
76. Christiansen JP, Edwards C, Sinclair T, Armstrong G, Scott A, Patel H, Hart H. Detection of myocardial scar by contrast-enhanced cardiac magnetic resonance imaging in patients with troponin-positive chest pain and minimal angiographic coronary artery disease. *Am J Cardiol* 2006;**97**:768–771.