

Non-syndromic isolated dominant optic atrophy caused by the p.R468C mutation in the AFG3 like matrix AAA peptidase subunit 2 gene

DAVIDE COLAVITO^{1*}, VERONICA MARITAN^{2*}, AGNESE SUPPIEJ³, ELDA DEL GIUDICE¹, MONICA MAZZAROLO², STEFANIA MIOTTO⁴, SOFIA FARINA¹, MAURIZIO DALLE CARBONARE¹, STEFANO PIERMAROCCHI⁵ and ALBERTA LEON¹

¹Research and Innovation Srl, I-35127 Padua; ²Paediatric Low Vision Center, Women's and Children's Health Department, University of Padua; ³Child Neurology and Clinical Neurophysiology Unit, Pediatric University Hospital of Padua, I-35100 Padua; ⁴ULSS 6 Euganea, phthalmology Unit, Camposampiero Hospital, I-35012 Padua; ⁵Neuroscience Department, University of Padua, I-35100 Padua, Italy

Received March 31, 2017; Accepted September 14, 2017

DOI: 10.3892/br.2017.987

Abstract. Autosomal dominant optic atrophy (DOA) is the most frequent form of hereditary optic atrophy, a disease presenting with considerable inter- and intra-familial clinical variability. Although a number of mutations in different genes are now known to cause DOA, many cases remain undiagnosed. In an attempt to identify the underlying genetic defect, whole exome sequencing was performed in a 19-year-old male that had been affected by isolated DOA since childhood. The exome sequencing revealed a pathogenic mutation (p.R468C, c.1402C>T) in the AFG3 like matrix AAA peptidase subunit 2 (AFG3L2) gene, a gene known to be associated with spinocerebellar ataxia. The patient did not show any signs other than DOA. Thus, the result demonstrates the possibility that mutations in the AFG3L2 gene may be a cause of isolated autosomal DOA.

Introduction

Autosomal dominant optic atrophy (DOA) is a disorder that results from the degeneration of the optic nerve fibers (1). It is one of the most prevalent forms of inherited optic neuropathies, which are genetic conditions affecting the retinal ganglion cells whose axons constitute the optic nerve (2). DOA is an important cause of inherited visual failure and occurs equally among males and females (1). Its prevalence is estimated to be

1 per 30,000 worldwide with higher frequencies in Denmark (1 per 10,000) due to a founder effect (3). It is generally diagnosed during childhood and is characterized by loss of visual acuity, dyschromatopsia, visual field defects and optic nerve pallor with optic disc excavation (4).

The majority of DOA cases (80%) are isolated (non-syndromic) while the remaining (20%) are syndromic (2). DOA that presents clinically as an isolated optic neuropathy is caused by mutations in OPA1, mitochondrial dynamin like GTPase (OPA1) (4), OPA3, outer mitochondrial membrane lipid metabolism regulator (OPA3; also associated with cataracts) (5), aconitase 2 (ACO2) (6) and transmembrane protein 126A (TMEM126A) (7) genes, while syndromic DOA forms show greater genetic heterogeneity (8). To date, 224 genes associated with optic atrophy are listed in the Human Phenotype Ontology (HPO) database, the majority presenting with neurological symptoms, such as ataxia, mental retardation and spastic paraplegia (9). Increasing evidence also indicates that other genes, in addition to yet unidentified genes, are involved (10). Yet, despite these advancements, more than half of DOA patients still await a genetic diagnosis (11). This shortcoming may be overcome using whole exome sequencing, which has the potential to define the molecular diagnosis of patients presenting with a negative result for mutations in the OPA1, OPA3, ACO2 and TMEM126A genes.

In the current study, the exome of an Italian patient affected by isolated DOA was analyzed. By combining exome sequencing with phenotype-driven variant analysis, a heterozygous mutation was identified in the AFG3 like matrix AAA peptidase subunit 2 (AFG3L2) gene. Notably, the p.R468C (c.1402C>T) mutation was recently described in a family exhibiting syndromic DOA co-segregating with mild intellectual disability (11).

Correspondence to: Dr Davide Colavito, Research and Innovation Srl, 4 Corso Stati Uniti, I-35127 Padua, Italy
E-mail: colavito@researchinnovation.com

*Contributed equally

Key words: optic atrophy, AFG3 like matrix AAA peptidase subunit 2, ataxia, spinocerebellar ataxia-28, exome sequencing

Patients and methods

Patient and clinical evaluation. A 19-year-old Italian male was admitted to the Pediatric Low Vision Unit of the University

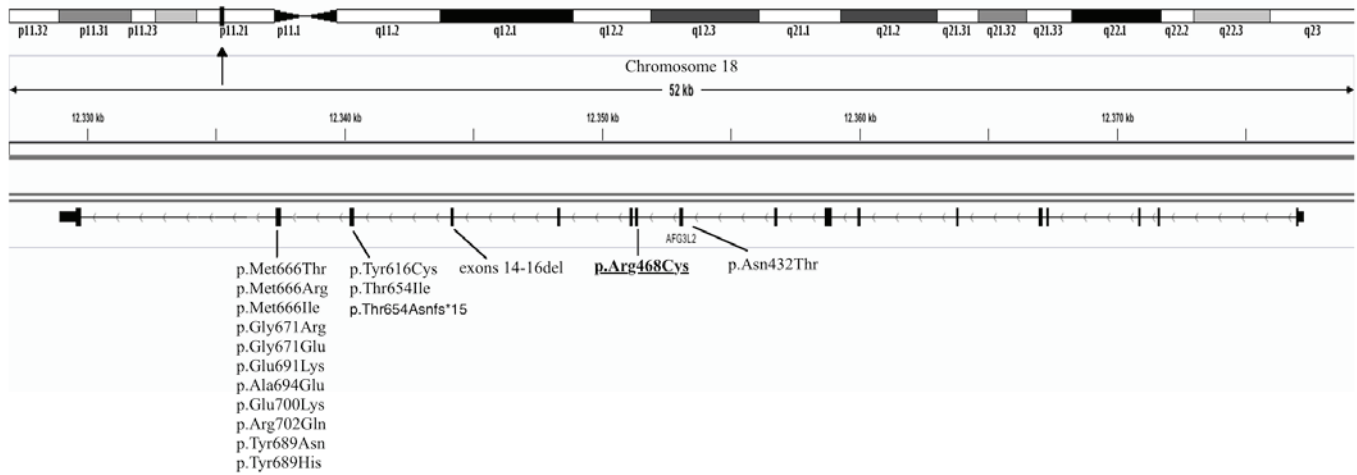


Figure 1. AFG3L2 gene end associated mutations reported in the literature. AFG3L2, AFG3 like matrix AAA peptidase subunit 2.

Hospital of Padua (Padua, Italy) with suspected optic atrophy. The patient had experienced visual difficulties from the age of 6, including color vision impairment and photophobia. When first examined, at 6 years of age, ophthalmological investigations revealed a best corrected visual acuity (BCVA) of 0.4 in each eye. Farnsworth testing revealed dyschromatopsia and fundus examination exhibited bilateral temporal optic nerve pallor. Intraocular pressure was within the normal range (15 and 13 mmHg in the right and left eye, respectively; normal range <18 mmHg). The anterior chamber of the eyes exhibited no pathological features.

At the age of 13, photopic and scotopic electroretinography tests did not reveal abnormal patterns, whereas visual evoked potentials (VEPs) to pattern reversal stimuli documented a significant decrease in the amplitude of the P100 wave at 15' and 30' angular frequencies. As hereditary optic neuropathy was suspected, genetic testing for OPA1 mutations, as well as for the mitochondrial mutations associated with Leber neuropathy, were performed with negative results.

BCVA worsened from 0.4 in each eye at age 6 to 0.2 in each eye at age 15. VEPs were repeated at the age of 17 and exhibited considerable worsening of amplitude and waveform.

The individual, who is currently 21-years-old, did not demonstrate further clinical deterioration. Furthermore, multifocal electroretinogram and electrooculography did not detect any alterations.

Whole exome sequencing. Whole blood (3 ml) was collected for exome analysis subsequent to obtaining informed consent. DNA was extracted using the Qiagen BioRobot DNA extraction kit (cat. no. 965162; Qiagen Benelux B.V., Venlo, the Netherlands) according to the manufacturer's instructions and quantified using Nanodrop spectral analysis (Thermo Fischer Scientific, Inc., Waltham, MA, USA). DNA fragmentation and degradation were evaluated by standard agarose gel electrophoresis (100 V, 30 min, 1.5% agarose gel in Tris-borate-EDTA buffer). DNA Library preparation and whole exon enrichment were performed employing Agilent SureSelectXT and Agilent SureSelect Clinical Research Exome (Agilent Technologies, Inc., Santa Clara CA, USA). Library sequences were obtained using the HiSeq2500

Illumina Sequencer (125-bp paired end sequence mode). Bioinformatics analysis included the following: Next-generation sequencing (NGS) reads mapping to whole genomes using the Burrows-Wheeler Alignment tool (12) with default parameters, polymerase chain reaction (PCR) duplicate removal using Picard (<http://picard.sourceforge.net>), single nucleotide polymorphisms and indel calling using the Genome Analysis Toolkit (GATK) UnifiedGenotyper (13), variant annotation using snpEff (<http://snpeff.sourceforge.net>) and false positive variant filtration using the GATK VariantFiltration module.

Exome sequencing data and reads alignment analysis had a mean depth of coverage (DoC) of 122.71x, with 95.7% of the captured sequences displaying a mean DoC of 20x. The mean DoC calculated for the mutated nucleotides was 69.0x.

An *in silico* multigene panel of 224 genes listed in the HPO database, associated with optic atrophy, was used to filter and select genetic variants obtained following exome sequencing (gene list is available upon request). Variant classification was performed in accordance with the recently published guidelines from the American College of Medical Genetics and Genomics (14).

Sanger sequencing of the variant p.R468C (c.1402C>T) in the AFG3L2 gene. DNA (100 ng) was amplified using a standard PCR procedure with a PCR mixture containing 2.5 μ l 10X concentrated PCR buffer, 0.7 μ l 50 mM MgCl₂ and 0.75 μ l 10 mM deoxyribonucleotide triphosphates (all from Solis BioDyne OÜ, Tartu, Estonia), 0.3 μ l of 100 μ M forward primer (5'-TTTAGCGGTCGGAGATGAAC-3') and 0.3 μ l of 100 μ M reverse primer (5'-CTGATGGTGCCTGTTGCTT-3'; Integrated DNA Technologies, Coralville, IA, USA), and 0.5 μ l 5 U/ μ l Hot Start DNA Polymerase (Solis BioDyne OÜ). Thermocycling consisted of one cycle of enzyme activation (at 95°C for 15 min), followed by 35 cycles of DNA amplification (at 95°C for 45 sec, at 59°C for 45 sec and at 72°C for 1 min). PCR products were then separated by agarose gel electrophoresis (100 V, 30 min, 1.5% agarose gel in Tris-borate-EDTA buffer; Sigma-Aldrich; Merck KGaA, Darmstadt, Germany) and purified with Invisorb Spin columns (Invitek Inc., Hayward, CA, USA). PCR-purified products were re-amplified with terminating nucleotides using

Big Dye Terminator v3.1 (Applied Biosystems; Thermo Fisher Scientific, Inc.). Sequencing analysis was performed with an ABI Prism 3100 Avant automated sequencer (Thermo Fisher Scientific, Inc.) equipped with 36-cm capillary array filled with POP6 polymer (Thermo Fisher Scientific, Inc.). Electropherograms were analyzed using Sequencing Analysis software version 5.1.1 (Applied Biosystems; Thermo Fisher Scientific, Inc.).

Results

Whole exome sequencing. Exome sequencing restricted to the 224 HPO genes that were associated with isolated and syndromic optic atrophy exhibited a mean DoC of 149.46x, with 99.00% of the captured sequences displaying a DoC >10x, 98.07% >20x and 91.56% >50x.

A total of 144 non-synonymous variants were detected in the 224 HPO genes that were screened; of these, 19 had an allele frequency <5% (data available upon request). Upon data analysis and interpretation none of these variants were found to be of pathogenic or potentially pathogenic significance. However, when extending the genetic analysis across the whole exome, a heterozygous p.R468C (c.1402C>T) mutation was identified in the AFG3L2 gene. The p.R468C mutation is not reported in the public accessible databases of human genetics (the Exome Aggregation Consortium, Exome Variant Server or 1000 Genome Project). It is located in an evolutionary conserved residue and computational analysis predicts a potentially damaging effect on the resulting protein (PholyPhen2 = 1.00) (phyloP-Vertebrate = 6.25/6.42) (phyloP-Primate = 0.56/0.65).

Sanger sequencing. Sanger sequencing analysis confirmed the presence of the p.R468C mutation in the patient and excluded its presence in the patient's mother. The father was untraceable; however, no signs of optic atrophy or cerebellar dysfunctions were reported on his behalf.

Discussion

DOA is a highly genetically heterogeneous type of optic neuropathy. Current diagnostic genetic testing approaches in DOA searches for mutations in OPA1, OPA3, ACO2 and TMEM126A, with a diagnostic success rate estimated to be ~70% (2). Gene sequencing is either performed by conventional methods, such as Sanger sequencing or by targeted capture NGS protocols. However, while single gene sequencing (Sanger sequencing) is impractical for clinical practice, due to time and budget constraints, the multigene targeted capture NGS approach is limiting due to gene selection bias. In addition, increasing genotype-phenotype associations indicates that other genes, in addition to yet unidentified genes, are likely to be implicated in DOA. Currently, the genetic testing approaches that theoretically guarantee the greatest diagnostic success are whole exome and whole genome sequencing.

In the current study, exome sequence analysis and interpretation in the patient revealed that there were no pathogenic or likely pathogenic mutations in the four genes typically associated with isolated DOA. Subsequently, the analysis was extended to include those genes listed in the HPO database

associated with optic atrophy (primarily syndromic) and again the results were negative. Therefore, the whole exome was subsequently analyzed using the phenotype-driven strategy for exome prioritization of human Mendelian disease genes (15,16). Notably, a heterozygous p.R468C (c.1402C>T) mutation was identified in exon 11 of the AFG3L2 gene. This gene interacts with the protein encoded by the SPG7 gene, which is one of the 224 genes listed in the HPO database.

The AFG3L2 gene contains 17 exons spanning 48 kb and maps to chromosome 18p11.21 (17). It encodes a 797-amino acid protein localized in the mitochondria and it is ubiquitously expressed in central and peripheral nerves (17). The AFG3L2 protein assembles with the homologous protein paraplegin to form large proteolytic complexes responsible for mitochondrial protein quality control (18,19). Functional studies in neurons demonstrated a role of AFG3L2 in axonal development and activity of mitochondrial respiratory complexes I and III (19). DOA is a mitochondrial disorder, thus reinforcing the possibility of an association between AFG3L2 and this particular neuropathy.

The p.R468C mutation in the AFG3L2 gene observed in the patient has previously been described in two patients (a father and son) with DOA and mild intellectual disability (11). The authors, however, did not exclude the possibility of a fortuitous association between the two phenotypes (11). In the present study, the proband exhibited no signs of intellectual disability. However, as the p.R468C mutation in the AFG3L2 gene is particularly rare, and given the limited available information in previous studies, interfamilial phenotype differences and/or penetrance cannot be excluded.

Currently, the majority of mutations in the AFG3L2 gene have been reported to be associated with autosomal dominant spinocerebellar ataxia 28 (17,20) and autosomal recessive spastic ataxia 5 (21,22) (MIM no. 604581). The patient in the present study currently exhibits isolated DOA with no signs of ataxia. This indicates that different mutations in various locations in the AFG3L2 gene may lead to different clinical phenotypes. Furthermore, the p.R468C mutation is located in exon 11, while all known ataxia-causing mutations, except one, are located in exons 15 and 16 of AFG3L2 (23,24) (Fig. 1). However, the mutation may be mild and/or cause late-onset ataxia or extra-ocular signs (11), thus requiring ongoing surveillance of the patient.

In conclusion, the current study identified, to the best of our knowledge, the first case of non-syndromic isolated optic atrophy potentially associated with a heterozygous pathogenic mutation in the AFG3L2 gene. Screening for mutations in this gene may facilitate with characterizing the genotype-phenotype association of AFG3L2 genetic variations in those patients without a genetic diagnosis of DOA. Using whole exome sequencing in clinical practice will further identify the disease aetiology of DOA, ideally facilitating genetic diagnosis, as well as the design of future treatment strategies.

References

1. Yu-Wai-Man P, Griffiths PG, Burke A, Sellar PW, Clarke MP, Gnanaraj L, Ah-Kine D, Hudson G, Czermin B, Taylor RW, *et al*: The prevalence and natural history of dominant optic atrophy due to OPA1 mutations. *Ophthalmology* 117: 1538-1546.e1, 2010.
2. Lenaers G, Hamel C, Delettre C, Amati-Bonneau P, Procaccio V, Bonneau D, Reynier P and Milea D: Dominant optic atrophy. *Orphanet J Rare Dis* 7: 46, 2012.

3. Thiselton DL, Alexander C, Morris A, Brooks S, Rosenberg T, Eiberg H, Kjer B, Kjer P, Bhattacharya SS and Votruba M: A frameshift mutation in exon 28 of the OPA1 gene explains the high prevalence of dominant optic atrophy in the Danish population: Evidence for a founder effect. *Hum Genet* 109: 498-502, 2001.
4. Ferré M, Caignard A, Milea D, Leruez S, Cassereau J, Chevrollier A, Amati-Bonneau P, Verny C, Bonneau D, Procaccio V and Reynier P: Improved locus-specific database for OPA1 mutations allows inclusion of advanced clinical data. *Hum Mutat* 36: 20-25, 2015.
5. Reynier P, Amati-Bonneau P, Verny C, Olichon A, Simard G, Guichet A, Bonnemains C, Malecaze F, Malinge MC, Pelletier JB, *et al*: OPA3 gene mutations responsible for autosomal dominant optic atrophy and cataract. *J Med Genet* 41: e110-e110, 2004.
6. Metodiev MD, Gerber S, Hubert L, Delahodde A, Chretien D, Gérard X, Amati-Bonneau P, Giacomotto MC, Boddaert N, Kaminska A, *et al*: Mutations in the tricarboxylic acid cycle enzyme, aconitase 2, cause either isolated or syndromic optic neuropathy with encephalopathy and cerebellar atrophy. *J Med Genet* 51: 834-838, 2014.
7. Hanein S, Perrault I, Roche O, Gerber S, Khadom N, Rio M, Boddaert N, Jean-Pierre M, Brahimi N, Serre V, *et al*: TMEM126A, encoding a mitochondrial protein, is mutated in autosomal-recessive nonsyndromic optic atrophy. *Am J Hum Genet* 84: 493-498, 2009.
8. Maresca A, la Morgia C, Caporali L, Valentino ML and Carelli V: The optic nerve: A 'mito-window' on mitochondrial neurodegeneration. *Mol Cell Neurosci* 55: 62-76, 2013.
9. Optic atrophy. <http://compbio.charite.de/hpweb/showterm?id=HP:0000648>. Accessed July 18, 2016.
10. Grenier J, Meunier I, Daien V, Baudoin C, Halloy F, Bocquet B, Blanchet C, Delettre C, Esmenjaud E, Roubertie A, *et al*: WFS1 in optic neuropathies: Mutation findings in nonsyndromic optic atrophy and assessment of clinical severity. *Ophthalmology* 123: 1989-1998, 2016.
11. Charif M, Roubertie A, Salime S, Mamouni S, Goizet C, Hamel CP and Lenaers G: A novel mutation of AFG3L2 might cause dominant optic atrophy in patients with mild intellectual disability. *Front Genet* 6: 311, 2015.
12. Li H and Durbin R: Fast and accurate short read alignment with Burrows-Wheeler transform. *Bioinformatics* 25: 1754-1760, 2009.
13. Van der Auwera GA, Carneiro MO, Hartl C, Poplin R, Del Angel G, Levy-Moonshine A, Jordan T, Shakir K, Roazen D, Thibault J, *et al*: From FastQ data to high confidence variant calls: The Genome Analysis Toolkit best practices pipeline. *Curr Protoc Bioinformatics* 11: 11.10.1-11.10.33, 2013.
14. Richards S, Aziz N, Bale S, Bick D, Das S, Gastier-Foster J, Grody WW, Hegde M, Lyon E, Spector E, *et al*: ACMG Laboratory Quality Assurance Committee: Standards and guidelines for the interpretation of sequence variants: A joint consensus recommendation of the American College of Medical Genetics and Genomics and the Association for Molecular Pathology. *Genet Med* 17: 405-424, 2015.
15. Zemojtel T, Köhler S, Mackenroth L, Jäger M, Hecht J, Krawitz P, Graul-Neumann L, Doelken S, Ehmke N, Spielmann M, *et al*: Effective diagnosis of genetic disease by computational phenotype analysis of the disease-associated genome. *Sci Transl Med* 6: 252ra123, 2014.
16. Smedley D and Robinson PN: Phenotype-driven strategies for exome prioritization of human Mendelian disease genes. *Genome Med* 7: 81, 2015.
17. Di Bella D, Lazzaro F, Brusco A, Plumari M, Battaglia G, Pastore A, Finardi A, Cagnoli C, Tempia F, Frontali M, *et al*: Mutations in the mitochondrial protease gene AFG3L2 cause dominant hereditary ataxia SCA28. *Nat Genet* 42: 313-321, 2010.
18. Zühlke C, Mikat B, Timmann D, Wiczorek D, Gillesen-Kaesbach G and Bürk K: Spinocerebellar ataxia 28: A novel AFG3L2 mutation in a German family with young onset, slow progression and saccadic slowing. *Cerebellum Ataxias* 2: 19, 2015.
19. Maltecca F, Aghaie A, Schroeder DG, Cassina L, Taylor BA, Phillips SJ, Malaguti M, Previtali S, Guénet JL, Quattrini A, *et al*: The mitochondrial protease AFG3L2 is essential for axonal development. *J Neurosci* 28: 2827-2836, 2008.
20. Cagnoli C, Stevanin G, Brussino A, Barberis M, Mancini C, Margolis RL, Holmes SE, Nobili M, Forlani S, Padovan S, *et al*: Missense mutations in the AFG3L2 proteolytic domain account for ~1.5% of European autosomal dominant cerebellar ataxias. *Hum Mutat* 31: 1117-1124, 2010.
21. Pierson TM, Adams D, Bonn F, Martinelli P, Cherukuri PF, Teer JK, Hansen NF, Cruz P, Mullikin For The Nisc Comparative Sequencing Program JC, Blakesley RW, *et al*: Whole-exome sequencing identifies homozygous AFG3L2 mutations in a spastic ataxia-neuropathy syndrome linked to mitochondrial m-AAA proteases. *PLoS Genet* 7: e1002325, 2011.
22. Muona M, Berkovic SF, Dibbens LM, Oliver KL, Maljevic S, Bayly MA, Joensuu T, Canafoglia L, Franceschetti S, Michelucci R, *et al*: A recurrent de novo mutation in KCNC1 causes progressive myoclonus epilepsy. *Nat Genet* 47: 39-46, 2015.
23. Löbbe AM, Kang JS, Hilker R, Hackstein H, Müller U and Nolte D: A novel missense mutation in AFG3L2 associated with late onset and slow progression of spinocerebellar ataxia type 28. *J Mol Neurosci* 52: 493-496, 2014.
24. Musova Z, Kaiserova M, Kriegova E, Fillerova R, Vasovcak P, Santava A, Mensikova K, Zumrova A, Krepelova A, Sedlacek Z and Kanovsky P: A novel frameshift mutation in the AFG3L2 gene in a patient with spinocerebellar ataxia. *Cerebellum* 13: 331-337, 2014.