

Neuroendoscopic biopsy of ventricular tumors: a multicentric experience

PIERO ANDREA OPPIDO, M.D., PH.D.,¹ ALESSANDRO FIORINDI, M.D., PH.D.,⁴
LUCIA BENVENUTI, M.D.,² FABIO CATTANI, M.D.,¹ SAVERIO CIPRI, M.D.,³
MICHELANGELO GANGEMI, M.D.,⁵ UMBERTO GODANO, M.D.,⁶ PIERLUIGI LONGATTI, M.D.,⁴
CARMELO MASCARI, M.D.,⁶ ENZO MORACE, M.D.,¹ AND LUIGINO TOSATTO, M.D.⁷

¹Department of Neurosurgery, National Cancer Institute IFO—Regina Elena, Roma; ²Department of Neurosurgery, Livorno Hospital, Livorno; ³Department of Neurosurgery, Reggio Calabria Hospital, Reggio Calabria; ⁴Department of Neurosurgery, Treviso Hospital, Padova University, Treviso; ⁵Department of Neurosurgery, Federico II University School of Medicine, Naples; ⁶Department of Neurosurgery, Bellaria Hospital, Bologna; and ⁷Department of Neurosurgery, Padua University Hospital, Padua, Italy

Object. Although neuroendoscopic biopsy is routinely performed, the safety and validity of this procedure has been studied only in small numbers of patients in single-center reports. The Section of Neuroendoscopy of the Italian Neurosurgical Society invited some of its members to review their own experience, gathering a sufficient number of cases for a wide analysis.

Methods. Retrospective data were collected by 7 centers routinely performing neuroendoscopic biopsies over a period of 10 years. Sixty patients with newly diagnosed intraventricular and paraventricular tumors were included. No patient harboring a colloid cyst was included. Data regarding clinical presentation, neuroimaging findings, operative techniques, pathological diagnosis, postoperative complications, and subsequent therapy were analyzed.

Results. In all patients, a neuroendoscopic tumor biopsy was performed. In 38 patients (64%), obstructive hydrocephalus was present. In addition to the tumor biopsy, 32 patients (53%) underwent endoscopic third ventriculostomy (ETV), and 7 (12%) underwent septum pellucidotomy. Only 2 patients required a ventriculoperitoneal shunt shortly after the endoscopy procedure because ETV was not feasible. The major complication due to the endoscopy procedure was ventricular hemorrhage noted on the postoperative images in 8 cases (13%). Only 2 patients were symptomatic and required medical therapy. Infection occurred in only 1 case, and the other complications were all reversible. In no case did clinically significant sequelae affect the patient's outcome. Tumor types ranged across the spectrum and included glioma (low- and high-grade [27%]), pure germinoma (15%), pineal parenchymal tumor (12%), primary neuroectodermal tumor (4%), lymphoma (9%), metastasis (4%), craniopharyngioma (6%), and other tumor types (13%). In 10% of patients, the pathological findings were inconclusive. According to diagnosis, specific therapy was performed in 35% of patients: 17% underwent microsurgical removal, and 18% underwent chemotherapy or radiotherapy.

Conclusions. This is one of the largest series confirming the safety and validity of the neuroendoscopic biopsy procedure. Complications were relatively low (about 13%), and they were all reversible. Neuroendoscopic biopsy provided meaningful pathological data in 90% of patients, making subsequent tumor therapy feasible. Cerebrospinal fluid pathways can be restored by ETV or septum pellucidotomy (65%) to control intracranial hypertension. In light of the results obtained, a neuroendoscopic biopsy should be considered a possible alternative to the stereotactic biopsy in the diagnosis and treatment of ventricular or paraventricular tumors. Furthermore, it could be the only surgical procedure necessary for the treatment of selected tumors. (DOI: 10.3171/2011.1.FOCUS10326)

KEY WORDS • intraventricular tumor • endoscopic biopsy • endoscopic third ventriculostomy • hydrocephalus

THE use of endoscopy in the biopsy of ventricular tumors was first reported by Fukushima⁷ in 1978. Subsequently, the increasing experience with this technique has clearly shown its advantage in visualizing the tumors during removal of biopsy samples while simultaneously avoiding highly vascularized structures. In ven-

Abbreviations used in this paper: ETV = endoscopic third ventriculostomy; VP = ventriculoperitoneal.

tricular tumors causing obstructive hydrocephalus, neuroendoscopy has gained even more appeal as a first-choice procedure since it is possible to simultaneously perform tumor biopsy and ETV or septostomy.^{8,17,21,24} The immediate relief of intracranial hypertension and the availability of specimens for a pathological diagnosis allow time for planning the most suitable treatment strategy based on histological diagnosis and CSF tumor markers.¹⁴ In fact, in a subset of ventricular or paraventricular tumors, further

surgical ablation is not required, and the endoscopic procedure may be the only surgical procedure necessary.¹⁸

Unfortunately, due to the infrequency of these lesions, comprising about 2% of all primary CNS tumors,^{13,23} only limited series have been reported in the literature^{2,3,6,16,26} and some questions remain unanswered. In light of this observation, the Section of Neuroendoscopy of the Italian Neurosurgical Society (SINCH) invited some expert members to review their own experience, gathering a sufficient number of cases for a wide analysis.¹

Methods

The data regarding neuroendoscopic procedures performed between 1997 and 2007 in 7 Italian centers, in which these procedures are routine, were retrospectively collected. Only neuroendoscopic procedures in which a biopsy sample was obtained from intraventricular and paraventricular tumors were analyzed. Patients affected by colloid cysts or benign intracranial cysts were excluded. All tumors were newly diagnosed, and histological diagnosis for deciding the specific treatment was necessary. A total of 60 patients (33 male and 27 female) were included from the 7 institutions involved (Bologna, Livorno, Naples, Padua, Roma, Reggio Calabria, and Treviso). Ages ranged from 5 to 78 years (median 48 years); 9 patients (15%) were children. All patients were symptomatic. Twenty patients (33%) presented with a classic intracranial hypertension syndrome, 2 of whom were lethargic on admission. The other patients presented with focal neurological signs (Table 1). Preoperative imaging consisted essentially of MR images to record ventricle diameters, tumor size, site, enhancement, and morphological characteristics. All tumors were associated with ventricular dilation, and had the following ranges in diameters: frontal horn, 13–75 mm (median 24 mm); Monro foramen, 5–20 mm (median 8 mm); and third ventricle, 9–25 mm (median 15 mm). The most frequent site of origin was the pineal region (38%), followed by the thalamic region (20%) and mesencephalon (18%). Forty-six tumors (77%) showed contrast enhancement, and 10 tumors (17%) were cystic. Six tumors (10%) were less than 10 mm in diameter, 21 (35%) were between 10 and 20 mm, and 29 (48%) were larger than 20 mm. The remaining 4 patients presented with diffuse lesions along the ventricle wall.

In all cases, a coronal or precoronal bur hole was cho-

sen as the entry point. Depending on the location of the tumor and the ventricle size, a unilateral access (mainly right side) was performed in all cases except one in which it was bilateral. A flexible steerable fiberoptic scope (4-mm external diameter) was used in 40 cases, a rigid endoscope (6-mm external diameter) was used in 15 cases, and both rigid and fiberoptic scopes were used in 5 cases. Stereotactic guidance or neuronavigation was used in only 6 cases to identify the best entry point and trajectory of the rigid endoscope to the posterior part of the third ventricle. Biopsy forceps were used to obtain tumor specimens from different areas of the tumor. Intraoperative bleeding was classified as mild when partial blurred vision occurred, moderate when blurred vision lasted between 3 and 5 minutes, and severe when it persisted for more than 5 minutes.

Results

Endoscopic Procedures

In all, specimens from 60 patients were obtained. The total surgical time ranged from 15 to 180 minutes (median 57 minutes). Timing was prolonged when ETV or septostomy were required in addition to biopsy or when bleeding occurred.

At least 4 biopsy samples for each case (range 4–14 samples) were obtained. In 12 cases, frozen sections were obtained intraoperatively but were conclusive for diagnosis only in 6. In 38 patients (64%), obstructive hydrocephalus was present; triventricular hydrocephalus was noted in 32 and biventricular hydrocephalus in 6 patients.

In 32 patients (53%), ETV was successfully performed during the same endoscopic procedure to treat obstructive hydrocephalus (Fig. 1). Only 2 patients required a VP shunt shortly after the endoscopic procedure because ETV was not feasible. Relief of CSF pathway obstructions to control intracranial hypertension in 7 cases (12%) was obtained through septostomy with the aid of an Ommaya reservoir. Six of these patients were affected by tumors larger than 20 mm in diameter, bulging into the lateral ventricle from the thalamus. One of them was a lymphoma, which was subsequently treated using chemotherapy (Fig. 2).

In 21 procedures (35%), bleeding occurred and was more frequent in the 12 tumors (20%) that were larger than 20 mm in diameter. In 13 cases (22%), bleeding was mild, in 6 it was moderate, and only in 2 patients it was severe. In all cases, bleeding was stopped by cautery or continuous irrigation with Ringer lactate solution. It was never necessary to abandon the procedure because of bleeding.

In 90% of cases, a tissue diagnosis was obtained, and the diagnostic yield is listed in Table 2. A diagnosis of “nonspecific origin” tumor was made in only 5 patients (8%), most of whom had malignant tumors. In only 6 cases (10%), the tissue diagnosis remained inconclusive for insufficient material.

Following diagnosis of the biopsy specimen, 21 patients (35%) underwent a specific treatment regimen: 10 (17%) underwent surgical removal, while 11 (18%) (with pure germinoma or lymphoma) were treated using chemotherapy or radiotherapy alone.

TABLE 1: Clinical findings at admission

Symptoms	No. of Patients
intracranial hypertension syndrome	20
ataxic gait	13
headache w/ papilledema	8
cognitive disorders	7
visual field deficits	4
ophthalmoplegia	4
Parinaud syndrome	2
hemiparesis	1
diabetes insipidus	1

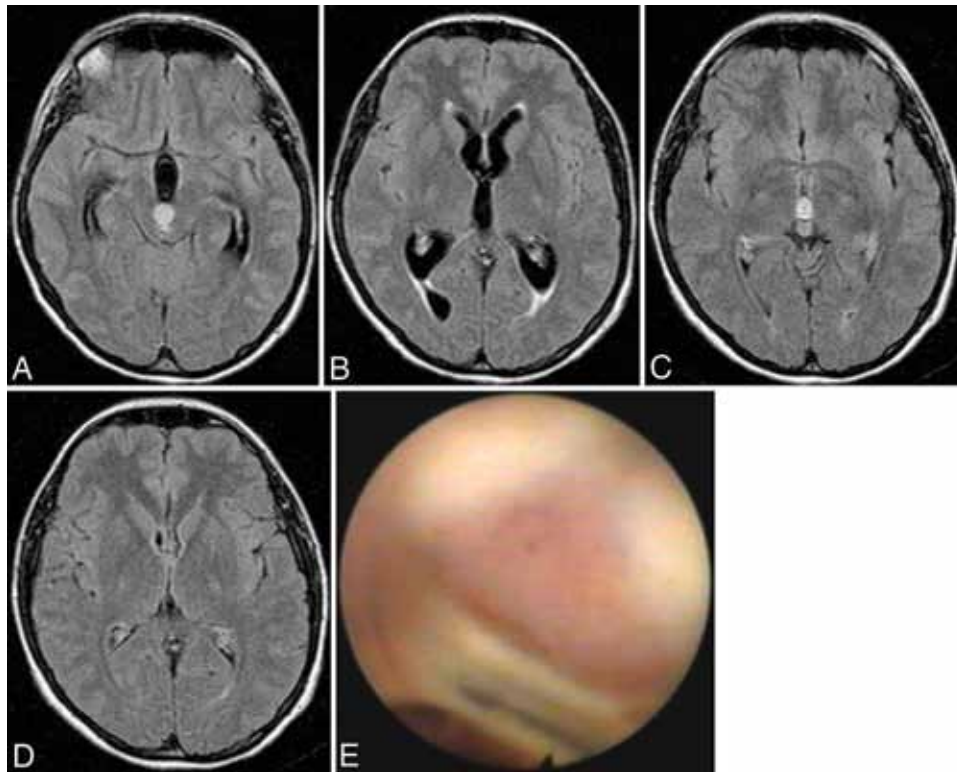


Fig. 1. Images obtained in a 33-year-old woman with a fibrillary astrocytoma associated with hydrocephalus. **A–D:** Axial FLAIR MR images. Preoperative images showing the tumor occluding the aqueduct (**A**) and hydrocephalus (**B**). Images obtained 1 year after the biopsy and ETV, showing stable tumor (**C**) and reduction of ventricular diameters (**D**). **E:** Endoscopic view of the tumor arising by the posterior commissure.

Complications

Due to the nature of the endoscopic procedure, no mortality or permanent morbidity was reported.

On postoperative imaging, 8 patients (13%) presented with intraventricular hemorrhagic complications due to endoscopic biopsy. In 4 (50%) of these, the hemorrhage was related to moderate bleeding ($p = 0.04$). All 8 tumors enhanced on MR imaging after administration of a contrast agent. Only 2 patients, presenting with a large and rich vascular tumor, were symptomatic and required medical therapy. In these patients, excessive biopsy sampling caused the tumor to hemorrhage. In the other 6 patients, hemorrhagic complications were not symptomatic and were noted only on postoperative images. In no case did clinically significant sequelae affect the patient's outcome.

Based on the discretion of the surgeon at the time of surgery, in 18 patients (30%) an external ventricular drain was placed for a few days, governed by the degree of intraventricular CSF flow. Other complications consisted of epilepsy in 2 patients, and hydrocephalus, meningitis, transient Parinaud syndrome, and intracerebral hematoma subsequent to ventricular puncture in 1 patient each.

Discussion

Neuroendoscopy is an accepted and widely used technique for obtaining biopsy material from tumors located within the ventricular system. It also offers the possibility of using ETV for treatment of associated hydrocephalus.^{9,11} Ventricular tumors represent a heterogeneous group in

terms of histology and therapy and often present with common clinical history and radiological aspects. These lesions can be benign or malignant and may simulate malformative or infectious diseases. Although histological diagnosis can be suspected on the basis of clinical and neuroimaging findings, pathological investigation of tumor samples is mandatory, especially if a choice exists between surgical and nonsurgical treatment options.^{2,13} Some tumors (for example, lymphoma or germinoma) are radiosensitive, and their surgical removal is excluded.^{4,19} On the other hand, the most frequent type of clinical presentation is a syndrome from intracranial hypertension. This was present in 33% of our patients and was accompanied by ventricular dilation, even in tumors smaller than 10 mm in diameter, due to blockage of the CSF pathways with hydrocephalus or an entrapped ventricle. In these cases, the patients' clinical features ruled out the possibility of performing other therapies as an alternative to surgery, which is used for the diagnosis and relief of intracranial hypertension.¹² Some authors have proposed obtaining a histological diagnosis by stereotactic biopsy and then, on the basis of the histological findings, deciding whether to perform surgical removal, radiotherapy, or chemotherapy.^{4,8,10} Large series of patients undergoing a stereotactic biopsy have reported a mortality rate of 0.7% with a 3.5% rate of permanent morbidity. The diagnostic accuracy is 91%, but it becomes remarkably lower in midline tumors with a higher incidence of complications.¹⁵ The alternative for the treatment of hydrocephalus is VP shunting, a procedure that may play a

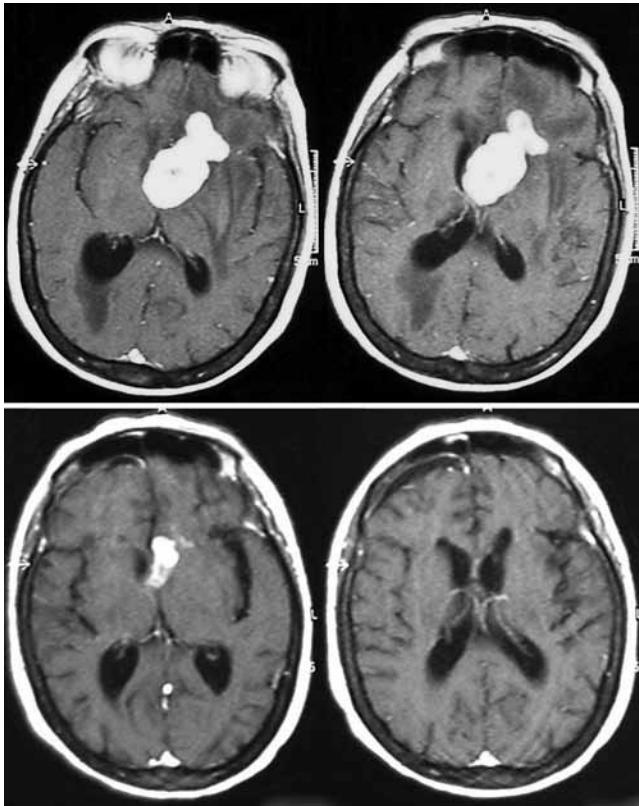


FIG. 2. Axial MR images obtained in a 65-year-old woman with a large intraventricular lymphoma. **Upper:** Preoperative images showing the lesion. **Lower:** Six months after the biopsy and septostomy, the images show remarkable tumor reduction during chemotherapy.

role in dissemination of some tumors such as pinealoblastoma and germ cell tumors into the peritoneum.²⁴ For this reason, even today, microsurgical removal is considered the best therapeutic option in selected cases. However, due to the deep location of intra- and paraventricular tumors, it remains challenging and is fraught with potential complications, which may be functional and cognitive or even life-threatening.^{12,25}

Over the past 10 years, the advances made in endoscopic technology have made it possible to suggest that the neuroendoscopic biopsy may represent an alternative strategy to stereotactic biopsy and microsurgery for obtaining a diagnosis.¹ At the same time, the neuroendoscope can harvest, under direct vision, biopsy specimens for defining histology and CSF samples for researching tumor markers. In fact, the CSF biochemical analysis to determine an accurate diagnosis of primary intracranial germ cell tumors is recommended.¹⁴ This procedure is absolutely indicated even in conditions of hydrocephalus and intracranial hypertension, and makes it possible to restore CSF pathways by ETV or septostomy.^{9,11} Endoscopic navigation to detect the lesion in patients with small ventricles is also possible using frameless neuronavigation.^{1,18,22} Because intra- and paraventricular tumors account for just 2% of all intracranial tumors, studies regarding the effectiveness and safety of endoscopic biopsy have been limited to just a few series of patients.^{3,6,13,16,20,26}

To the best of our knowledge, the present series, which

TABLE 2: Histopathological diagnosis

Diagnosis	No. of Patients
low-grade glioma	7
high-grade glioma	9
pure germinoma	9
malignant teratoma	1
pineoblastoma	2
pineocytoma	5
craniopharyngioma	4
primitive neuroectodermal tumor	3
lymphoma	6
metastasis	3
nonspecific tumor	5
inconclusive	6

does not include colloid cysts or other nontumoral lesions, is one of the largest series to evaluate retrospectively the validity of the endoscopic biopsy procedure. However, the analysis of the data recorded by the 7 Italian centers that boast the greatest experience in the past decade could be limited by the heterogeneity of the technique and the instruments used. Furthermore, our results could be representative of what would be expected by experts and not by neurosurgeons with less experience. Neuronavigation-guided endoscopy was helpful only in 6 selected cases to plan the best entry point and trajectory of the rigid endoscope to the posterior part of the third ventricle. Furthermore, neuronavigation guidance is still useful for intraoperative orientation, especially when there is impaired visualization or narrowing of the ventricles.^{1,18,22} In our series, neuronavigation guidance was rarely used due to its need for a rigid endoscope. Therefore, a flexible steerable fiberoptic scope was more frequently used. A histological diagnosis was obtained in 90% of cases, a success rate similar to that reported by other authors.^{2,3,6,16,20,26} In our experience, endoscopic biopsy had the same degree of accuracy as the stereotactic technique, but without the mortality and limited permanent morbidity of this procedure.^{5,10,15} In our opinion, the superiority of endoscopic over stereotactic biopsy is due to the fact that it offers the possibility of simultaneously relieving the CSF pathways by ETV or septostomy, which was feasible in 65% of our cases. In comparison with open surgery, the neuroendoscopic biopsy is limited by the small size of the specimens harvested, which was the reason for diagnostic failure in 10% of the present series. Equally, neuroendoscopy has the possibility of controlling the tumor target and generally produces less bleeding. In our experience, bleeding was controllable, and hemorrhagic complications occurred only in 13% of patients, mainly in tumors larger than 20 mm in diameter that are presumably more malignant and more richly vascularized. In the future, we can predict that improved coagulation techniques (laser or radiofrequency) will make it possible to harvest the biopsy sample more safely and reduce the hemorrhagic complications. All the major complications were reversible and those minor ones, resolved by medical therapy, did not alter the natural history of the disease. Only 2 patients re-

quired a VP shunt shortly after the endoscopic procedure. Therefore, in our opinion the simultaneous biopsy does not increase the risk of ETV failure. The rationale behind the choice of performing neuroendoscopic biopsy is therefore not only to obtain a diagnosis, but also to control intracranial hypertension, enabling subsequent specific treatment. In fact, in our series, 18% of the tumors were treated by chemotherapy or radiotherapy alone. In lymphomas and pure germinomas, a regression of the tumor can be expected, restoring CSF pathways.^{4,19} We believe that the histological diagnosis of tumors bulging into the lateral and third ventricles represents the first step in selecting patients for microsurgical removal, and that neuroendoscopy is a useful technique for obtaining tumor specimens and treating hydrocephalus in such cases.

Conclusions

Our data confirm that the endoscopic biopsy, in comparison with open surgery and stereotactic biopsy, is a safe and minimally invasive procedure. Its diagnostic accuracy and capacity to restore CSF pathways by ETV, especially in the presence of obstructive hydrocephalus, offer the possibility of subsequent therapeutic options as an alternative or adjuvant to surgical therapy burdened by higher morbidity and mortality, even today.

Disclosure

The authors report no conflict of interest concerning the materials or methods used in this study or the findings specified in this paper.

Author contributions to the study and manuscript preparation include the following. Conception and design: Gangemi, Godano, Longatti. Acquisition of data: Oppido, Cattani, Cipri, Mascari, Morace, Tosatto. Analysis and interpretation of data: Oppido, Morace. Drafting the article: Oppido. Critically revising the article: Fiorindi, Gangemi, Godano, Longatti. Reviewed final version of the manuscript and approved it for submission: Oppido, Godano, Longatti. Study supervision: Oppido, Benvenuti, Gangemi, Godano, Longatti, Morace.

References

- Cappabianca P, Cinalli G, Gangemi M, Brunori A, Cavallo LM, de Divitiis E, et al: Application of neuroendoscopy to intraventricular lesions. **Neurosurgery** **62** (Suppl 2):575–598, 2008
- Chernov MF, Kamikawa S, Yamane F, Ishihara S, Kubo O, Hori T: Neurofiberscopic biopsy of tumors of the pineal region and posterior third ventricle: indications, technique, complications, and results. **Neurosurgery** **59**:267–277, 2006
- Depreitere B, Dasi N, Rutka J, Dirks P, Drake J: Endoscopic biopsy for intraventricular tumors in children. **J Neurosurg** **106** (5 Suppl):340–346, 2007
- Ferreri AJM, Dell’Oro S, Foppoli M, Bernardi M, Brandes AA, Tosoni A, et al: MATILDE regimen followed by radiotherapy is an active strategy against primary CNS lymphomas. **Neurology** **66**:1435–1438, 2006
- Field M, Witham TF, Flickinger JC, Kondziolka D, Lunsford LD: Comprehensive assessment of hemorrhage risks and outcomes after stereotactic brain biopsy. **J Neurosurg** **94**:545–551, 2001
- Fiorindi A, Longatti P: A restricted neuroendoscopic approach for pathological diagnosis of intraventricular and paraventricular tumours. **Acta Neurochir (Wien)** **150**:1235–1239, 2008
- Fukushima T: Endoscopic biopsy of intraventricular tumors with the use of a ventriculofiberscope. **Neurosurgery** **2**:110–113, 1978
- Gangemi M, Maiuri F, Colella G, Buonamassa S: Endoscopic surgery for pineal region tumors. **Minim Invasive Neurosurg** **44**:70–73, 2001
- Gangemi M, Mascari C, Maiuri F, Godano U, Donati P, Longatti PL: Long-term outcome of endoscopic third ventriculostomy in obstructive hydrocephalus. **Minim Invasive Neurosurg** **50**:265–269, 2007
- Hall WA: The safety and efficacy of stereotactic biopsy for intracranial lesions. **Cancer** **82**:1749–1755, 1998
- Hellwig D, Grotenhuis JA, Tirakotai W, Riegel T, Schulte DM, Bauer BL, et al: Endoscopic third ventriculostomy for obstructive hydrocephalus. **Neurosurg Rev** **28**:1–38, 2005
- Johnson RR, Baehring J, Piepmeyer J: Surgery for third ventricular tumors. **Neurosurg Q** **13**:207–225, 2003
- Koeller KK, Sandberg GD, Armed Forces Institute of Pathology: From the archives of the AFIP. Cerebral intraventricular neoplasms: radiologic-pathologic correlation. **Radiographics** **22**:1473–1505, 2002
- Luther N, Edgar MA, Dunkel IJ, Souweidane MM: Correlation of endoscopic biopsy with tumor marker status in primary intracranial germ cell tumors. **J Neurooncol** **79**:45–50, 2006
- McGirt MJ, Woodworth GF, Coon AL, Frazier JM, Amundson E, Garonzik I, et al: Independent predictors of morbidity after image-guided stereotactic brain biopsy: a risk assessment of 270 cases. **J Neurosurg** **102**:897–901, 2005
- Najjar MW, Azzam NI, Baghdadi TS, Turkmani AH, Skaf G: Endoscopy in the management of intra-ventricular lesions: preliminary experience in the Middle East. **Clin Neurol Neurosurg** **112**:17–22, 2010
- O’Brien DF, Hayhurst C, Pizer B, Mallucci CL: Outcomes in patients undergoing single-trajectory endoscopic third ventriculostomy and endoscopic biopsy for midline tumors presenting with obstructive hydrocephalus. **J Neurosurg** **105** (3 Suppl):219–226, 2006
- Prat R, Galeano I: Endoscopic biopsy of foramen of Monro and third ventricle lesions guided by frameless neuronavigation: usefulness and limitations. **Clin Neurol Neurosurg** **111**:579–582, 2009
- Shono T, Natori Y, Morioka T, Torisu R, Mizoguchi M, Nagata S, et al: Results of a long-term follow-up after neuroendoscopic biopsy procedure and third ventriculostomy in patients with intracranial germinomas. **J Neurosurg** **107** (3 Suppl):193–198, 2007
- Souweidane MM, Luther N: Endoscopic resection of solid intraventricular brain tumors. **J Neurosurg** **105**:271–278, 2006
- Tirakotai W, Bozinov O, Sure U, Riegel T, Bertalanffy H, Hellwig D: The evolution of stereotactic guidance in neuroendoscopy. **Childs Nerv Syst** **20**:790–795, 2004
- Tirakotai W, Hellwig D, Bertalanffy H, Riegel T: The role of neuroendoscopy in the management of solid or solid-cystic intra- and periventricular tumours. **Childs Nerv Syst** **23**:653–658, 2007
- Waldron JS, Tihan T: Epidemiology and pathology of intraventricular tumors. **Neurosurg Clin N Am** **14**:469–482, 2003
- Yamini B, Refai D, Rubin CM, Frim DM: Initial endoscopic management of pineal region tumors and associated hydrocephalus: clinical series and literature review. **J Neurosurg** **100** (5 Suppl Pediatrics):437–441, 2004
- Yaşargil MG, Abdulrauf SI: Surgery of intraventricular tumors. **Neurosurgery** **62** (6 Suppl 3):1029–1041, 2008
- Yurtseven T, Erşahin Y, Demirtaş E, Mutluer S: Neuroendoscopic biopsy for intraventricular tumors. **Minim Invasive Neurosurg** **46**:293–299, 2003

Manuscript submitted December 15, 2010.

Accepted January 13, 2011.

Address correspondence to: Piero Andrea Oppido, M.D., Ph.D., Department of Neurosurgery, National Cancer Institute IFO—Regina Elena, Via Elio Chianesi 53, 00144 Roma, Italy. email: oppido@ifo.it.