

CLINICAL STUDY

Scintigraphic patterns of adrenocortical carcinoma: morpho-functional correlates

Luisa Barzon, Pietro Zucchetta¹, Marco Boscaro², Maria Cristina Marzola¹, Franco Bui¹ and Francesco Fallo

Department of Medical and Surgical Sciences, Division of Endocrinology, and ¹Nuclear Medicine Service, University of Padova, Italy and ²Department of Internal Medicine, Division of Endocrinology, University of Ancona, Italy

(Correspondence should be addressed to Francesco Fallo, Department of Medical and Surgical Sciences, Division of Endocrinology, University of Padova, Via Ospedale 105, 35128 Padova, Italy; Email francesco.fallo@unipd.it)

Abstract

Objective: Adrenocortical scintigraphy has demonstrated clinical utility in the morpho-functional characterization of adrenal tumors. The aim of this study was to identify possible relationships between the scintigraphic pattern and endocrine and/or morphological data in a series of adrenocortical carcinomas.

Design and Methods: Twenty-one patients with adrenocortical carcinoma (11 nonfunctioning and 10 hormone-secreting) were investigated with ⁷⁵Se-methyl-nor-cholesterol scintigraphy. Clinical, hormonal, radiological, and pathological data were analyzed.

Results: The adrenal mass showed no radiocholesterol uptake in 18 cases (11 nonfunctioning and 7 functioning lesions). Contralateral normal adrenal gland was visualized in all patients with nonfunctioning tumors, whereas classic bilateral nonvisualization was observed in the 7 cases with hyperfunctioning masses. Three patients with cortisol-producing carcinomas showed radiotracer uptake by the mass, without visualization of the contralateral gland. At histology, the tumors were shown to be undifferentiated adrenocortical carcinomas; they had an aggressive clinical behavior.

Conclusions: Radiocholesterol scintigraphy has an important role in diagnosing adrenocortical carcinomas, which typically are not visualized. However, 30% of hypersecreting adrenocortical carcinomas show an atypical increased tracer uptake, not predictive of the biochemical and histological features of the tumor.

European Journal of Endocrinology 145 743–748

Introduction

Adrenocortical carcinoma is a rare and aggressive cancer with a dismal prognosis (1, 2). The unresponsiveness of the tumor to most chemotherapeutic agents adds to the poor overall survival, and surgery at an early stage remains the only chance for cure (1, 2). Early diagnosis of the nature of an adrenal mass is crucial for appropriate management, in particular for nonfunctioning ones. Indeed, at variance with the rare hypersecreting adrenal tumors, which require surgery regardless of whether they are benign or malignant, the much more common nonfunctioning clinically silent masses pose the difficult task of distinguishing between benign lesions, which may be followed, and malignant primary tumors, which should be removed (3). Adrenocortical scintigraphy has demonstrated clinical utility in the assessment of the nature and hormonal activity of adrenal tumors, based on radiotracer uptake and accumulation in functioning adrenocortical tissues (4, 5). Typically, benign hypersecreting tumors,

such as cortisol-, aldosterone-, and androgen-secreting adenomas, and non-hypersecreting adenomas show radiocholesterol uptake, whereas primary and secondary adrenal malignancies appear as 'cold' masses (4–6).

In this retrospective study, we analyzed a possible relationship between scintigraphic uptake patterns and clinical and morpho-functional data in patients with adrenocortical carcinomas.

Subjects and methods

Out of 68 consecutive patients (41 females and 27 males; median age, 46 years; range, 16–77 years) with histologically diagnosed adrenocortical carcinoma (median diameter 10 cm; range, 4–23 cm; 40 functioning and 28 nonfunctioning), referred to our Institution in the last 3 decades, only those (10 females and 11 males; median age, 56 years; range, 19–74 years) who underwent scintigraphic evaluation of adrenal masses (median diameter, 8 cm; range, 4–23 cm; 13

Table 1 Clinical details of the patients with adrenocortical carcinomas.

Patient	Age (yrs)/ Sex	Functional status	Serum K ⁺ (mmol/l)*	SBP/DBP (mmHg)	Ur. cortisol (nmol/24 h)**	Size (cm); side	Scintigraphic uptake	Stage	Metastases at diagnosis	Capsular invasion	Atypical mitoses	Mitotic index (n/50 HPF)	Weiss score	Disease free (months)	Survival (months)***
1	56/M	Nonfunctioning	4.1	135/85	110	7R	Discordant	IV	Liver	+	+	15	6	0	12
2	54/M	Nonfunctioning	4.4	150/95	332	4L	Discordant	IV	Liver, lung	+	+	8	4	0	11
3	65/M	Nonfunctioning	4.4	150/90	218	7R/2L	Bilateral	IV	Liver, peritoneum	+	+	>20	7	0	5
4	55/M	Nonfunctioning	4.2	120/90	160	8L	Nonvisualization	II		-	+	10	5	13	35
5	60/M	Nonfunctioning	4.8	130/95	270	8R	Discordant	II		+	+	15	5	8	49
6	60/F	Nonfunctioning	4.8	160/100	306	8R	Discordant	II		-	+	7	4	12	20
7	72/M	Nonfunctioning	4.5	140/80	242	6R	Discordant	II		+	+	10	4	24	32
8	66/F	Nonfunctioning	4.1	130/85	126	5L	Discordant	II		+	-	6	6	8	19
9	74/M	Nonfunctioning	4.3	140/85	174	23L	Discordant	IV	Liver, lung	+	+	>20	7	0	10
10	20/M	Nonfunctioning	4.2	190/115	240	11R	Discordant	IV	Lung, bone	+	+	>20	7	0	12
11	66/F	Nonfunctioning	4.0	145/90	360	4R	Discordant	IV	Lung, bone, kidney	+	+	8	4	0	13
12	42/F	Cushing's syndrome	4.0	155/90	862	11.5R	Bilateral nonvisualization	IV	Liver	+	+	>20	5	0	19
13	19/F	Cushing's syndrome	3.8	160/95	1740	9R	Bilateral nonvisualization	IV	Lung	+	+	10	4	0	38
14	43/F	Cushing's syndrome	4.4	145/100	380	9R	Concordant	IV	Liver, bone, lung	-	+	>20	4	0	11
15	25/M	Cushing's syndrome	4.0	145/90	3700	8R	Concordant	IV	Bone	+	+	7	8	0	40
16	62/M	Cushing's syndrome	3.6	180/100	410	6R	Bilateral nonvisualization	II		+	-	10	5	14	14
17	47/F	Cushing's syndrome and virilization	3.4	160/110	1836	11.3R	Bilateral nonvisualization	II		+	+	>20	5	51+	51+
18	57/M	Cushing's syndrome	4.4	150/90	3465	20L	Bilateral nonvisualization	IV	Lung	+	+	>20	6	0	2
19	63/F	Cushing's syndrome	4.8	145/95	520	6L	Concordant	II		-	+	>20	4	6	10+
20	28/F	Cushing's syndrome and virilization	4.0	150/95	2100	6R	Bilateral nonvisualization	IV	Liver	+	-	>20	6	0	24+
21	40/F	Cushing's syndrome and virilization	3.4	150/100	788	8R	Bilateral nonvisualization	II		-	+	8	5	16	32+

SBP, systolic blood pressure; DBP, diastolic blood pressure; HPF, high power field.

*normal serum K⁺ value 3.5–5.5 mmol/l; **normal urinary (Ur.) cortisol value 82–330 nmol/24 h. ***+, alive at last follow-up.

right, 7 left and 1 bilateral) were included in this retrospective study. Part of the patient population has been described in previous reports (7–9). The criteria for prescribing adrenal scintigraphy were patient's consent, patient's performance status (Karnowsky performance score >60), short-term availability of radiocholesterol, and no clear radiological evidence of malignant adrenocortical carcinoma achieved with other imaging modalities (i.e. computed tomography (CT) and/or magnetic resonance imaging (MRI)). The 47 patients who did not undergo adrenal scintiscan included 31 females and 16 males (median age 45 years, range 16–77 years) with functioning (30 cases) and nonfunctioning (17 cases) adrenocortical carcinomas (median diameter 9.5 cm, range 4.6–22 cm; stage I–II in 17 cases, stage III–IV in 30 cases). No statistically significant differences in demographic, hormonal and tumor characteristics were observed between patients who did and those who did not undergo scintigraphy.

Tumors were considered functioning when associated with an overt clinical syndrome due to adrenocortical hormone excess, i.e. Cushing's syndrome, primary aldosteronism, virilization or feminization. Nonfunctioning tumors were defined as adrenal masses in the absence of any clinical sign of adrenal hyperfunction and in the absence of abnormally elevated adrenal hormone levels, as previously reported (8). Staging of the disease was carried out according to the MacFarlane-Sullivan classification (10, 11). Diagnosis of malignancy was confirmed by histological examination following the criteria reported by Weiss *et al.* (12) (Weiss score, see Table 1), which define malignancy as the presence of three or more histological findings, including high nuclear grade (13), mitotic rate greater than 5 per 50 high-power fields, atypical mitotic figures, eosinophilic tumor cell cytoplasm ($\geq 75\%$ of tumor cells), diffuse architecture ($\geq 33\%$ of tumor), necrosis, venous invasion, sinusoidal invasion, and capsular invasion. Informed consent was obtained from all subjects, and the investigation was performed in accordance with the principles of the Declaration of Helsinki.

Diagnostic work-up included morphological and morphofunctional investigation with adrenal CT and/or MRI, and ^{75}Se -selenomethyl-nor-cholesterol scintigraphy, as previously reported (7, 8). In detail, adrenal scintiscan was performed using 11–14 MBq [^{75}Se]-selenio-6 α -methyl-19norcholesterol (Scintadren, Amersham, Bucks, UK). Images were acquired at 72 and 120 h following tracer injection, using a large-field-of-view gamma camera equipped with a high-energy, parallel-hole collimator interfaced to a digital computer (matrix size 256 \times 256, zoom 1.8, 500 000 counts, posterior view, HEAP collimator). Scintiscan evaluation was based on the criteria of Gross *et al.* (5, 14), defining the following uptake patterns: (i) tumor uptake with no visualization of the contralateral gland (*exclusive uptake*); (ii) prevalent uptake by the tumor with visualization of the contralateral gland

(*prevalent uptake*); (iii) bilateral symmetric uptake (*symmetric uptake*); (iv) reduced or absent uptake by the tumor (*discordant uptake*); (v) no uptake by the mass and by the contralateral normal adrenal gland (*bilateral nonvisualization*). Exclusive and prevalent uptake patterns were considered *concordant uptake*.

All patients underwent tumor staging and follow-up observation by chest X-ray, chest-abdominal CT-scan or MRI, and bone scintiscan.

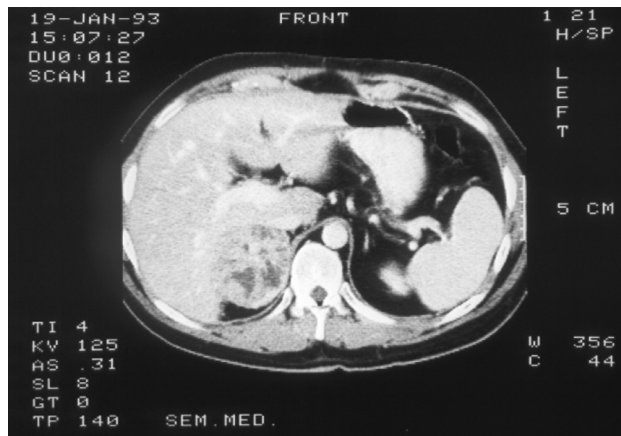Endocrine evaluation consisted of measurements of plasma cortisol at 0800 h and 1800 h in baseline condition (normal range, 138–550 nmol/l at 0800 h) and after low- and/or high-dose dexamethasone suppression tests (normal value, <138 nmol/l), morning plasma adrenocorticotropin (normal range, 4–18 pmol/l), dehydroepiandrosterone sulfate (DHEA-S; normal range, 0.5–9 $\mu\text{mol/l}$ in males; 1.8–10.5 $\mu\text{mol/l}$ in premenopausal females; 0.3–1.6 $\mu\text{mol/l}$ in postmenopausal females), 17-hydroxyprogesterone (normal range, 1.2–10 nmol/l in males; 0.3–3.6 nmol/l during the follicular phase and 1.2–14.5 nmol/l during the luteal phase in premenopausal females; 0.3–1.8 nmol/l in postmenopausal females), testosterone (normal range, 1.04–31.25 nmol/l in males; 0.71–3.12 nmol/l in females), supine and upright plasma renin activity (PRA) and aldosterone (normal range for supine PRA, 1–3 ng/ml/h; for supine plasma aldosterone, 80–280 pmol/l), 24-h urinary free cortisol (normal range, 82–330 nmol/24 h). All hormones were measured by RIA or two-site immunoradiometric assay using commercially available kits (7, 8). Urinary catecholamines and/or metanephrines (normal range for epinephrine, <80 nmol/24 h; for norepinephrine, <600 nmol/24 h; for metanephrine, 0.40–1.50 nmol/24 h; for normetanephrine, 0.6–1.9 nmol/24 h) were measured by high performance liquid chromatography using an electrochemical detector. The intra- and inter-assay coefficients of variation for all assays were below 10%. Mineralocorticoid precursors were not measured.

Results are given as the median and range. Comparisons between variables were tested with the Pearson χ^2 test and the Wilcoxon signed rank test, as appropriate. Kaplan-Meier survival analysis was used to estimate disease freedom and survival rates. A value of $P < 0.05$ was considered statistically significant.

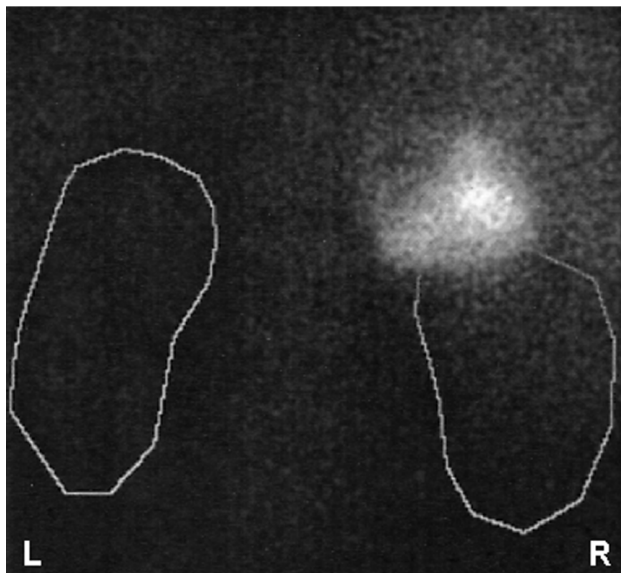
Results

Clinical data of the patients are detailed in Table 1. On the basis of clinical and endocrine data, 11 patients had nonfunctioning adrenocortical carcinomas, and 10 patients had functioning adrenocortical carcinomas (Cushing's syndrome in 7, Cushing's syndrome and virilization in 3). At diagnosis, 9 patients had stage II disease and 12 patients had distant metastases. Histological diagnosis showed high grade tumors (i.e. mitotic index >20/50 high power fields) in 9/21

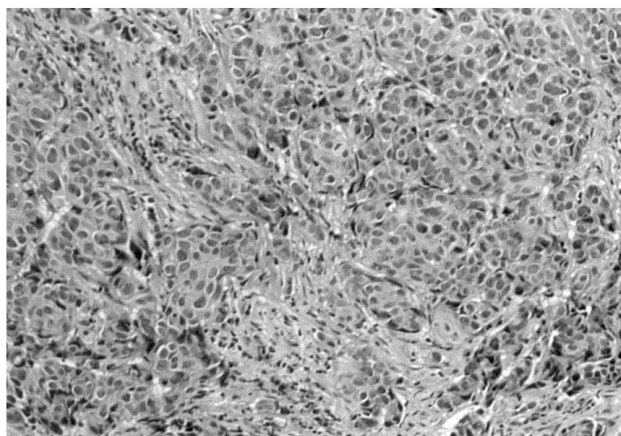
(a)



(b)



(c)



(43%) cases. According to survival analysis, 21% of patients were free from disease at 1 year from diagnosis, and 65% and 20% of patients were alive at 1 and 3 years from diagnosis respectively.

In all cases with nonfunctioning tumors, the mass identified at CT/MRI demonstrated no radiocholesterol uptake at scintiscan. The contralateral normal adrenal gland was constantly visualized in all but one patient, who had bilateral masses. Adrenocortical scintigraphy demonstrated the classical pattern of bilateral nonvisualization in 7 out of 10 patients (70%) with hypersecreting carcinomas. At variance, in 3 patients (30%) with Cushing's syndrome (Table 1, patients 14, 15, 19) the mass showed increased unilateral radiotracer uptake without visualization of the contralateral normal adrenal gland (concordant uptake).

In particular, at diagnosis, patient 14 (Table 1) showed clinical features and hormonal data typical of overt Cushing's syndrome, and a 9×6 cm right adrenal mass at abdominal CT-scan. Histological examination demonstrated an adrenocortical carcinoma, composed almost exclusively of fasciculata-like cells with high mitotic index, but without apparent capsular invasion. Post-surgical staging demonstrated liver, bone and lung metastases that progressed notwithstanding treatment with mitotane and chemotherapy (survival 11 months).

Patient no. 15 (Table 1 and Fig. 1), who was referred for severe Cushing's syndrome, underwent surgical resection of a 7×8 cm inhomogeneous right adrenal mass. Histology revealed an adrenocortical carcinoma, surrounded by an incomplete pseudocapsula, with a nodular pattern of growth, prevalent eosinophilic cells (85%), marked nuclear pleomorphism (nuclear grade 3), necrotic areas, irregular fibrosis, capsular and vascular invasion, and frequent mitoses (7/50 high power fields). After operation, the patient started mitotane therapy for bone metastases. Death occurred after 40 months from diagnosis for diffuse metastatic disease.

Neither patient 14 nor 15 showed any radiocholesterol uptake at the site of metastases.

In patient no. 19 a 5-cm left adrenal mass was incidentally discovered at abdominal ultrasonography performed for evaluation of acute renal failure and anemia. Endocrine study demonstrated elevated urinary and plasma cortisol levels. Preoperative staging demonstrated localized disease. At histology the mass appeared

Figure 1 Cortisol-secreting adrenocortical carcinoma. (a) CT scan of the abdomen showing an 8-cm inhomogeneous right adrenal mass; (b) ^{75}Se -methyl-nor-cholesterol scintigraphy showing uptake in the right adrenal mass, with no uptake in the left side. Renal outlines were obtained after the administration of $^{99\text{m}}\text{Tc}$ -diethylenetriamine pentacetic acid; (c) histological picture of the tumor displaying mainly compact cells with a diffuse pattern of growth and mitotic activity (hematoxylin-eosin, medium power photomicrograph).

multinodular, with trabecular architecture, and areas of myxoid tissue, necrosis, hemorrhage, but without vascular, sinusoidal, or capsular invasion. Most cells were eosinophils with rounded nuclei. Mitoses were frequent (>20/50 high power fields) and often atypical. Immunohistochemical staining for vimentin and cytokeratin was negative. Six months after surgery, the patient had local recurrence and liver metastases, which were in progression despite mitotane and chemotherapy.

Radiocholesterol uptake was significantly more frequent in functioning adrenocortical carcinomas than in nonfunctioning adrenal masses ($P < 0.05$). However, there were no significant differences with regard to adrenocortical hormone levels (i.e. plasma and urinary cortisol, DHEA-S, aldosterone), survival rate, tumor size, tumor weight, and pathological findings (i.e. mitotic index, Weiss score), between adrenal masses showing radiotracer uptake and those not visualized at scintigraphy.

Discussion

Adrenocortical scintigraphy has demonstrated clinical utility in the morpho-functional characterization of adrenal tumors. However, extensive data on the diagnostic accuracy of this technique are reported only for benign adrenal masses (4–6, 8, 15), whereas studies on adrenocortical malignancies deal with a very limited number of cases. In our experience, based on a large series of adrenocortical cancers evaluated with this technique in a single center, all nonfunctioning and 70% of hypersecreting carcinomas did not show radiocholesterol uptake at scintiscan. The results confirm data from the literature, where scintigraphic non-visualization of the tumor has been found capable of identifying primary or secondary adrenal malignancies with high sensitivity and specificity (5, 6, 14, 16, 17). This scintigraphic pattern has been related to the low uptake of radiocholesterol per gram of tissue, compared with normal adrenal cortex or benign adrenocortical lesions (14), and has been attributed to an altered cholesterol metabolism or to *de novo* synthesis of cholesterol by the tumor (18). Out of our 10 cortisol-secreting adrenocortical carcinomas, 3 showed marked radiotracer uptake without visualization of the contralateral normal adrenal gland. Positive scanning in hypersecreting adrenocortical carcinomas has been anecdotally reported in the literature (5, 19–21). The persistence of tracer uptake has been considered a characteristic feature of well-differentiated hyperfunctioning tumors, with less aggressive behavior (5, 21, 22). However, in our experience, 2 of our 3 patients with radiotracer uptake by the tumor showed a high mitotic index (>20/50 high power fields) at histology, a parameter used as a criterion to define high grade carcinomas and associated with a worse prognosis (12). The third patient, in spite of a low mitotic

index, showed capsular invasion and atypical mitoses. Moreover, all patients had metastases at diagnosis or soon after surgery, and were unresponsive to treatment, indicating an aggressive behavior of the disease. The three cases also had size and radiological characteristics of the adrenal mass similar to those of the cases without radiocholesterol uptake. Two patients had modestly elevated levels of cortisol, but a hypersecretion of precursor steroids causing a clinical syndrome could not be excluded. It is unclear if this hypothesis could be consistent with a potential increase of cholesterol uptake by the neoplastic tissue. Indeed, functional and molecular studies are needed to clarify the mechanism of radiocholesterol uptake in adrenocortical carcinomas.

In conclusion, radiocholesterol scintigraphy has an important role in diagnosing adrenocortical carcinoma, which is typically not visualized. However, 30% of cortisol-secreting adrenocortical carcinomas show an atypical increased tracer uptake, not predictive of the biochemical and histological features of the tumor.

Acknowledgements

This work was supported by grant no. 821/02/98 from Regione Veneto-Italy.

References

- Stratakis CA & Chrousos GP. Adrenal cancer. *Endocrinology and Metabolism Clinics of North America* 2000 **29** 15–25.
- Luton JP, Cedars S, Billaud L, Thomas G, Guilhaume B, Bertagna X *et al.* Clinical features of adrenocortical carcinoma, prognostic factors and the effect of mitotane therapy. *New England Journal of Medicine* 1990 **322** 1195–1201.
- Barzon L & Boscaro M. Diagnosis and management of adrenal incidentalomas. *Journal of Urology* 2000 **163** 398–407.
- Lieberman LM, Beierwaltes WH, Conn JW, Ansari AN & Nishiyama H. Diagnosis of adrenal disease by visualization of human adrenal glands with ¹³¹I-19-iodocholesterol. *New England Journal of Medicine* 1971 **285** 1387–1393.
- Gross MD, Shapiro B, Thrall JH, Freitas JE & Beierwaltes WH. The scintigraphic imaging of endocrine organs. *Endocrine Reviews* 1984 **5** 221–281.
- Kazerooni EA, Sisson JC, Shapiro B, Gross MD, Driedger A & Hurwitz GA. Diagnostic accuracy and pitfalls of [iodine-131]6-beta-iodomethyl-19-norcholesterol (NP-59) imaging. *Journal of Nuclear Medicine* 1990 **31** 526–534.
- Barzon L, Fallo F, Sonino N, Daniele O & Boscaro M. Adrenocortical carcinoma: experience in 45 patients. *Oncology* 1997 **54** 490–496.
- Barzon L, Scaroni C, Sonino N, Fallo F, Gregianin M, Macrì C *et al.* Incidentally discovered adrenal tumors: endocrine and scintigraphic correlates. *Journal of Clinical Endocrinology and Metabolism* 1998 **83** 55–62.
- Barzon L, Fallo F, Sonino N, Daniele O & Boscaro M. Comment - is there a role for low doses of mitotane (o,p'-DDD) as adjuvant therapy in adrenocortical carcinoma? *Journal of Clinical Endocrinology and Metabolism* 1999 **84** 1488.
- MacFarlane DA. Cancer of the adrenal cortex: the natural history, prognosis and treatment in a study of fifty-five cases. *Annals of the Royal College of Surgeons of England* 1958 **23** 155–186.

- 11 Sullivan M, Bouleau M & Hodges CV. Adrenal cortical carcinoma. *Journal of Urology* 1978 **120** 660–665.
- 12 Weiss LM, Medeiros J & Vickery AL. Pathological features of prognostic significance in adrenocortical carcinoma. *American Journal of Surgical Pathology* 1989 **13** 202–206.
- 13 Furrman SA, Lasky LC & Limas C. Prognostic significance of morphologic parameters in renal cell carcinoma. *American Journal of Surgical Pathology* 1982 **6** 655–663.
- 14 Gross MD, Shapiro B, Francis IR, Glazer GM, Bree RL, Arcomano MA *et al.* Scintigraphic evaluation of clinically silent adrenal masses. *Journal of Nuclear Medicine* 1994 **35** 1145–1152.
- 15 Bui F, Macrì C, Varotto L, Boscaro M & Mantero F. Adrenal scintigraphy in the morphological and functional evaluation of Cushing's syndrome. *Cardiology* 1985 **72** (Suppl 1) 76–83.
- 16 Schteingart DE, Seabold JE, Gross MD & Swanson DP. Iodocholesterol adrenal tissue uptake and imaging in adrenal neoplasms. *Journal of Clinical Endocrinology and Metabolism* 1981 **52** 1156–1161.
- 17 Bernini GP, Miccoli P, Moretti A, Vivaldi MS, Iacconi P & Salvetti A. Sixty adrenal masses of large dimensions: hormonal and morphologic evaluation. *Urology* 1998 **51** 920–925.
- 18 Greathouse DJ, McDermott MT, Kidd GS & Hofeldt FD. Pure primary hyperaldosteronism due to adrenal cortical carcinoma. *American Journal of Medicine* 1984 **76** 1132–1136.
- 19 Leger FA, Requeda E, Reach G, Plouin PF & Savoie JC. Scintigraphie cortico-surrénalienne au ¹³¹I-19-iodocholestérol. *La Nouvelle Presse Médicale* 1981 **10** 395–399.
- 20 Kafagi FA, Gross MD, Shapiro B, Glazer GM, Francis I & Thompson NW. Clinical significance of the large adrenal mass. *British Journal of Surgery* 1991 **78** 828–833.
- 21 Fig LM, Gross MD, Shapiro B, Ehrmann DA, Freitas JE, Schteingart DE *et al.* Adrenal localization in the adrenocorticotrophic hormone-independent Cushing syndrome. *Annals of Internal Medicine* 1988 **109** 547–553.
- 22 Pasiaka JL, McLeod MK, Thompson NW, Gross MD & Schteingart DE. Adrenal scintigraphy of well-differentiated (functioning) adrenocortical carcinomas: potential surgical pitfalls. *Surgery* 1992 **112** 884–890.

Received 26 April 2001

Accepted 31 August 2001