

INVITED REVIEW

Prevalence and natural history of adrenal incidentalomas

Luisa Barzon, Nicoletta Sonino¹, Francesco Fallo², Giorgio Palù and Marco Boscaro³*Department of Histology, Microbiology, and Medical Biotechnologies, University of Padua, Via Gabelli 63, 35121 Padua, Italy,**¹Department of Statistical Sciences, University of Padua, Padua, Italy, ²Department of Medical and Surgical Sciences, University of Padua, Padua, Italy and ³Division of Endocrinology, University of Ancona, Ancona, Italy**(Correspondence should be addressed to L. Barzon; Email: luisa.barzon@unipd.it)*

Abstract

Clinically silent adrenal masses discovered by imaging studies performed for unrelated reasons, i.e. adrenal incidentalomas, have become a rather common finding in clinical practice. However, only limited studies of incidence, prevalence, and natural history of adrenal incidentalomas are available. A comprehensive review of the literature shows the prevalence of adrenal incidentalomas to be 2.3% at autopsy and 0.5–2% at abdominal computed tomography scan. Most lesions are adrenocortical adenomas at histology, whereas the prevalence of adrenocortical carcinomas is relatively low. The risk of malignancy over time for masses defined as benign at diagnosis is estimated at about 1/1000, even though 5–25% of masses increase in size during follow-up. Hyperfunction develops in about 1.7% of cases and the risk is higher in patients with lesions larger than 3 cm. Cortisol hypersecretion is the most likely disorder that may ensue, and it remains subclinical in about two-thirds of cases. The lack of controlled studies precludes making specific management recommendations. Large perspective controlled studies to define the epidemiology, natural history, and possible associated morbidity of adrenal incidentalomas and their impact on the quality of life of patients are needed.

European Journal of Endocrinology 149 273–285

Introduction

Clinically silent adrenal masses discovered by imaging studies performed for unrelated reasons, i.e. adrenal incidentalomas, have become a rather common finding in clinical practice (1, 2). Although, in most cases, these masses are non-hypersecreting and benign, they still represent an important clinical concern because of the risk of malignancy or hormone hyperfunction. Experience in imaging and hormonal evaluation of adrenal incidentalomas and insights into the epidemiology and natural history are still growing.

Prevalence

The prevalence of adrenal incidentalomas varies with the source of data (either autopsy series or radiological series) and with the selection of patients (i.e. general population or special patient categories). With the widespread application of high-resolution imaging techniques the discovery of such masses has dramatically increased and has become a common problem in our aging population. Indeed, the prevalence of

adrenal incidentalomas also varies with the patients' age, being higher in older subjects.

Autopsy series

The prevalence of adrenal incidentalomas varies in the different autopsic studies, depending on the age of the patient and the size of the tumor. The mean prevalence in a total of 71 206 cases from the literature is 2.3%, ranging from 1 to 8.7%, without significant differences between females and males (3–15) (Table 1). The prevalence of adrenal incidentalomas increases with the patients' age, being 0.2% in young subjects as compared with 6.9% in subjects older than 70 years of age (1). Some authors have associated a higher prevalence of non-hypersecreting adrenocortical adenomas with the occurrence of diabetes mellitus, obesity, and hypertension (1, 4, 9). In this regard, a pathogenetic role for periods of ischemia followed by compensatory regeneration has been suggested (15). The variability of the prevalence of adrenal lesions among the different series also reflects the difficulty in distinguishing hyperplasia from small

Table 1 Prevalence of adrenal incidentalomas in autopsy series.

Study (reference)	No. of patients	Prevalence (%)		
		Overall	Females	Males
Rineheart <i>et al.</i> 1941 (3)	100	3.0	—	—
Russi <i>et al.</i> 1945 (4)	9000	1.45	2.0	1.2
Commons & Callaway 1948 (5)	7437	2.86	2.84	2.88
Schroeder 1953 (6)	4000	1.38	—	—
Devenyi 1967 (7)	5120	3.55	3.62	3.61
Kokko <i>et al.</i> 1967 (8)	2000	1.05	—	—
Hedeland <i>et al.</i> 1968 (9)	739	8.70	7.16	10.34
Yamada & Fukunaga 1969 (10)	948	5.40	—	—
Granger & Genest 1970 (11)	2425	2.52	2.43	2.58
Russell <i>et al.</i> 1972 (12)	35 000	1.97	2.05	1.92
Abecassis <i>et al.</i> 1985 (13)	988	1.90	—	—
Meagher <i>et al.</i> 1988 (14)	2951	5.0	—	—
Reinhard <i>et al.</i> 1996 (15)	498	5.0	—	—
Total	71 206	1441/71 206 (2.33%)		

nodules and adenomas. In 498 consecutive autopsies, Reinhard *et al.* (15) reported the presence of single or multiple nodules in 53.7% of cases and adenomas in 5.0%. The diameter of nodules ranged from 0.3 to 8.0 mm and that of adenomas from 3.2 to 28.0 mm.

Radiological series

Adrenal incidentaloma is considered a disease of modern technology, since its occurrence has become apparent with the availability of high-resolution non-invasive imaging modalities. In this regard, a survey on adrenal incidentalomas in Japan which analyzed the number of diagnoses in the period from 1980 to 1988 according to the imaging technique employed, either computed tomography (CT) scan or ultrasonography, showed an increase in the detection of adrenal incidentalomas during time, mainly due to an increased use of abdominal CT scans performed for unrelated diseases (16). Non-functioning tumors were mainly responsible for the increase in diagnosis of adrenal incidentalomas, accounting for 0% of operated cases in 1980 and about 80% of operated cases in 1988. On the contrary, no significant chronological changes in the diagnosis of cortical carcinomas or of functioning tumors, such as pheochromocytomas, aldosteronomas, and cortisol-secreting adenomas, were observed (16). The mean prevalence of adrenal incidentalomas in the CT scan series, considering a total of 82 483 scans from the literature published in the period from 1982 to 1994, was 0.64%, ranging from 0.35 to 1.9% (13, 17–21) (Table 2). This prevalence is probably underestimated, since most investigations were performed with obsolete CT scanners. By using contemporary high-resolution CT scanning technology, the prevalence should approach that of autopsy studies. Indeed, the most recent report from Caplan *et al.* (21)

shows a higher prevalence of adrenal incidentalomas, similar to that observed at autopsy.

Oncology series

Although, by definition, adrenal masses discovered in the course of abdominal imaging performed for staging of cancer are not generally considered as adrenal incidentalomas, several authors include patients with known malignancies in their series. In such patients the risk of an adrenal mass being a metastasis is high, ranging from 45 to 73% (13, 19, 22). Moreover, the risk increases with adrenal mass size, as malignancy rates of 43–100% have been reported for masses larger than 3 cm (19, 22).

The adrenal gland is a common site of metastatic spread, especially from lung, breast, stomach, and kidney cancer, and melanoma and lymphoma (23). Indeed, autopsic and radiological studies report a prevalence of adrenal metastases in patients with known extra-adrenal malignancies ranging from 3 to 40% and from 6 to 20% respectively (1, 2, 23). In a recent report from the University of Texas, M. D. Anderson Cancer Center (24), out of a series of 1639 patients with unknown primary cancer, the adrenal

Table 2 Prevalence of adrenal incidentalomas in CT-scan series.

Study (reference)	No. adrenal masses/ No. scans	Prevalence (%)
Glazer <i>et al.</i> 1982 (17)	16/2200	0.60
Printz <i>et al.</i> 1982 (18)	4/1423	0.35
Abecassis <i>et al.</i> 1985 (13)	19/1459	1.30
Belldegrun <i>et al.</i> 1986 (19)	88/12 000	0.70
Herrera <i>et al.</i> 1991 (20)	259/61 054	0.42
Caplan <i>et al.</i> 1994 (21)	33/1779	1.90
Total	531/82 483	0.64

gland was identified as a site of involvement at presentation in 5.8% of cases, and involvement was limited to the adrenal gland in 0.2% of patients. Interestingly, patients with adrenal metastases had a significantly shorter overall survival than patients without adrenal involvement (24, 25). However, no patients fulfilled the criteria for a true incidentaloma, indicating that the manifestations of a metastasing cancer presenting as an incidentaloma is extremely rare. Isolated metastases to the adrenal gland are uncommon in asymptomatic patients without a history of malignancy, accounting for 0.4% of cases in the large series reported by Herrera *et al.* (20).

Inherited endocrine cancer syndromes

Adrenal lesions may represent a feature of inherited endocrine cancer syndromes or may be the expression of a predisposition to develop endocrine neoplasms. A recent study from the Swedish Cancer Registry demonstrated that the finding of a secondary endocrine tumor was significantly increased after any other endocrine tumor (26). As for adrenal tumors, the occurrence of a secondary adrenal tumor was significantly increased after a first adrenal tumor or after a first thyroid tumor, particularly in males (68.6-fold and 40.7-fold increase respectively). On the other hand, the incidence of a thyroid cancer was very high following an adrenal tumor (122.5- and 26.1-fold increase in males and females respectively). The increased incidence of secondary tumors may have resulted from the treatment given for the first cancer and/or be caused by the same environmental or genetic factors that caused the first cancer. Indeed, in some cases the association between the first and the second endocrine gland tumor was remarkably high, suggesting that patients were affected by one of the known cancer syndromes with endocrine manifestations, particularly multiple endocrine neoplasia (MEN) type 1, MEN type 2, and Von Hippel–Lindau (VHL), as demonstrated also by the development of related cancers in family members. Further, increased diagnosis of secondary tumors was probably related to intense medical screening after diagnosing the first cancer. In any case, it should be kept in mind that the discovery of an adrenal mass could be the first manifestation of a familial cancer syndrome, although this is a very rare event. Overall, adrenal lesions are found in 40% of MEN1-affected patients (27–29), in 40–50% of MEN2-affected patients (30, 31), in 10–20% of VHL-affected patients (31–33), in 20% of patients with familial paraganglioma syndrome (31, 33), in 1% of patients with neurofibromatosis type 1 (31, 34), in 30% of those with the Carney's complex (35), in 10–30% of those with the Li–Fraumeni syndrome (36), in 7–13% of cases of familial adenomatous polyposis (37, 38), and in 15% of patients with the Beckwith–Wiedemann syndrome (39).

Congenital adrenal hyperplasia

Adrenal enlargement may be incidentally found in patients with undiagnosed mild congenital adrenal hyperplasia (40–43), even though genetic screening by mutational analysis of the *CYP21B* and the *CYP11B1* genes indicates that undiagnosed congenital adrenal hyperplasia is not a common underlying condition in patients with adrenal incidentalomas (44–46). These tumors are benign in most cases, and adrenocortical carcinomas are extremely unlikely. In congenital adrenal hyperplasia, decreased production of cortisol leads to increased adrenocorticotropin secretion, resulting in adrenal hyperplasia. Jareh *et al.* (47) reported a high prevalence of adrenal masses, nearly 82% in homozygous and 45% in heterozygous patients with congenital adrenal hyperplasia, including deficiencies of 21-hydroxylase, 11 β -hydroxylase, and 3 β -hydroxysteroid dehydrogenase. In congenital adrenal hyperplasia, adrenal size correlated with patients' age and the age at which therapy was started (47). On the other hand, no correlation between tumor size and serum 17-hydroxyprogesterone concentration was found in these patients, at variance with findings of a relationship between tumor size and 17-hydroxyprogesterone-stimulated secretion reported in patients with adrenal incidentalomas not associated with congenital adrenal hyperplasia (48–50). This observation seems to indicate that abnormal hormonal findings in sporadic adrenal incidentalomas may simply parallel the increased volume of adrenal tissue or intratumoral functional impairment of enzyme activity, rather than a true enzymatic defect.

Age and sex distribution

Adrenal incidentalomas show different distribution in the population with regard to the patients' age and sex, the side, and the size and nature of the mass (16, 20, 21, 51–73) (Table 3). However, these differences are often biased by the rate and type of diagnostic procedures performed in different categories of patients.

In clinical reports, adrenal incidentalomas show a peak incidence in the fifth to seventh decades (1, 20, 53, 69). The mean age of patients at diagnosis is 55 years, without significant age differences between females and males. Adrenal masses are more frequent in females, with a female to male ratio of 1.3–1.5 (Table 3). Since no sex differences have been reported in autopsy studies, the higher prevalence of adrenal incidentalomas in females can be ascribed to a higher rate of abdominal diagnostic procedures performed in women than in men. Although the age and sex of the patient do not appear to be helpful in predicting the presence of an adrenocortical carcinoma, adrenocortical malignancies generally occur at younger ages than benign adrenal lesions (69) and are significantly more

Table 3 Clinical features of adrenal incidentalomas.

Study (reference)	No. of patients	F/M ratio	Mean age (years)	Mean tumor size (cm)	Subclinical Cushing's syndrome (%)	Pheochromocytoma (%)	Aldosterone-producing adenoma (%)	Adreno-cortical cancer (%)	Metastatic cancer (%)	Apparent non-functioning adenoma (%)
Ambrosi <i>et al.</i> 1995 (51)	32	2.5	55	2.7	12.5	0	0	3.13	0	78.1
Aso & Homma 1992 (16)	210	0.7	53	4.9	3.3	23.3	3.3	4.29	1.4	36.7
Bardet <i>et al.</i> 1996 (52)	46	NR	NR	2.6	6.5	4.4	0	4.35	2.2	69.6
Barzon <i>et al.</i> 2002 (53)	284	1.5	56	3.6	11.3	5.9	2.1	8.80	2.8	64.8
Bastounis <i>et al.</i> 1997 (54)	86	1.5	61	4.1	3.5	2.33	0	1.16	2.3	61.6
Bencsik <i>et al.</i> 1995 (55)	63	1.1	27–85	2.5–1.4	20.6	0	0	1.59	11.1	50.8
Bondanelli <i>et al.</i> 1997 (56)	38	1.4	58	2.6	10.5	5.3	0	2.63	0	81.6
Bulow & Ahren 2002 (57)	381	1.3	64	3.0	1.0	3.9	0.5	2.6	2.1	84.2
Caplan <i>et al.</i> 1994 (21)	26	1.9	66	NR	11.5	0	3.8	0	0	84.6
Favia <i>et al.</i> 2000 (58)	158	1.2	58	4.4	5.1	2.5	3.8	9.49	1.9	76.6
Flecchia <i>et al.</i> 1995 (59)	32	1.3	57	3.7	21.9	0	0	6.25	6.2	46.9
Herrera <i>et al.</i> 1991 (20)	342	1.5	62	2.5	0.6	1.5	0	1.17	0.3	95.9
Kasperlik-Zaluska <i>et al.</i> 1997 (60)	208	2.5	52	NR	2.9	9.1	0	8.65	9.1	70.2
Linos <i>et al.</i> 1996 (61)	57	1.3	49	5.9	8.8	7.0	0	3.51	3.5	84.2
Mantero & Arnaldi 2000 (62)	208	NR	NR	NR	13.9	3.4	1.0	0.96	1.0	76.0
Murai <i>et al.</i> 1999 (63)	59	NR	NR	NR	1.7	18.6	1.7	5.08	0	72.9
Osella <i>et al.</i> 1994 (64)	45	1.4	55	3	15.6	4.4	0	6.67	2.2	71.1
Proye <i>et al.</i> 1998 (65)	103	NR	NR	NR	0	14.6	4.8	4.85	3.9	69.9
Reincke <i>et al.</i> 1992 (66)	68	1.6	59	3.2	11.8	1.5	1.5	0	0	85.3
Rossi <i>et al.</i> 2000 (67)	65	1.7	54	3.3	18.5	7.7	0	3.08	3.1	58.5
Seppel & Schlaghecke 1994 (68)	52	1.7	56	3	1.9	1.9	0	0	0	96.1
Mantero <i>et al.</i> 2000 (69)	1004	1.4	58	3	9.2	4.2	1.6	4.68	1.2	71.3
Tanabe <i>et al.</i> 2001 (70)	38	NR	NR	NR	47.4	0	0	0	0	52.6
Terzolo <i>et al.</i> 1997 (71)	210	1.5	55	3.1	14.3	4.8	0.5	7.14	0.9	58.6
Tutuncu & Gedik 1999 (72)	33	1.2	51	5.1	6.1	18.2	0	6.06	6.1	63.6
Virkkala <i>et al.</i> 1989 (73)	20	1.4	59	2.3	25.0	0	0	0	0	75.0
Total	3868				306 (7.9%)	217 (5.6%)	48 (1.2%)	170 (4.4%)	81 (2.1%)	2781 (71.2%)

NR: not reported.

frequent in males, with a female to male ratio of 0.5 for malignant tumors and 1.7 for benign tumors (42).

Side and size distribution

Adrenal masses are found in the right adrenal gland in 50–60% of cases, in the left adrenal gland in 30–40% of cases, and bilaterally in 10–15% of cases (42, 59, 69). This difference can be accounted for by the widespread use of ultrasonography, which is less efficient than CT scan in detecting tumors on the left side, since a similar distribution between the two adrenal glands has been reported in CT scan (20) and autopsy series (1).

The mean diameter of adrenal incidentalomas discovered at CT scan is 3–3.5 cm, ranging from 0.5 to 25 cm (Table 3). Tumor size determined at CT scan is usually less than the diameter reported on histological examination. Size underestimation at CT scan has been estimated to range from 20 to 47% (19, 74). This is of interest since preoperative assessment of tumor size is one of the major decision criteria for surgery. In fact, the probability of malignancy increases as a function of mass size. A review of more than 1300 tumors reported in non-surgical series in the last 10 years (16, 20, 53, 56, 58, 62, 64) shows that incidence of malignant neoplasms is significantly higher for masses greater than 4 cm in size (Fig. 1). Considering these data, the benign to malignant ratio can be estimated as 5:1 at a cut-off of greater than 3 cm in diameter, and 3:1 at a cut-off of greater than 4 cm (Fig. 1). However, mass diameter should not be used as the only criterion of malignancy, since malignant tumors less than 3 cm in diameter are not uncommon (19, 69, 74). As to mass size, subclinical adrenal hyperfunction is significantly more frequent in patients with larger

masses than in those with small masses, as demonstrated in a review of about 1000 unselected cases from the literature (16, 20, 53, 56, 64, 66) (Fig. 2).

Etiology and function

In the vast majority of cases, adrenal incidentalomas are non-hypersecreting adrenocortical adenomas. However, they may also represent primary or metastatic malignancies and show minor endocrine abnormalities or subclinical hyperfunction. A review of the literature including 3868 patients with adrenal incidentalomas from 26 non-surgical series (16, 20, 21, 51–63) shows 70% of cases with an apparently non-functioning cortical adenoma, 5% with an adrenocortical carcinoma, 2% with metastases, 16% with hyperfunctioning tumors, and 8% with other lesions (i.e. myelolipomas, cysts, hemorrhage, etc.) (Table 3). Similar results have been recently reported in a survey in Japan (75) including 2455 cases of adrenal incidentalomas (i.e. 52.3% non-functioning adenomas, 7.9% cortisol-secreting adenomas, 7.9% pheochromocytomas, 4.1% aldosterone-secreting adenomas, and 1.5% adrenocortical carcinomas).

Pathology

Most incidentally discovered adrenal masses are adrenocortical adenomas, while adrenal medullary tumors are less frequent and represented mainly by pheochromocytomas (76) (Table 4). Combinations of cortical and medullary tumors (corticomedullary tumors) are found occasionally (42). Other adrenal lesions, such as myelolipomas, lipomas, cysts, hemangiomas, angiosarcomas, and lymphomas, are rare. The prevalence of metastases

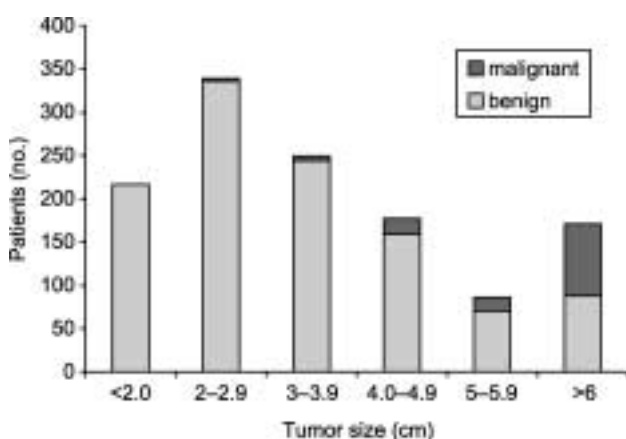


Figure 1 Distribution of adrenal incidentalomas ($n = 1322$) according to size and nature (benign vs malignant). For review of the literature see references 16, 20, 53, 56, 57, 61, 63. The prevalence of malignancy was significantly higher among masses ≥ 4 cm in diameter (χ^2 ; $P < 0.001$).

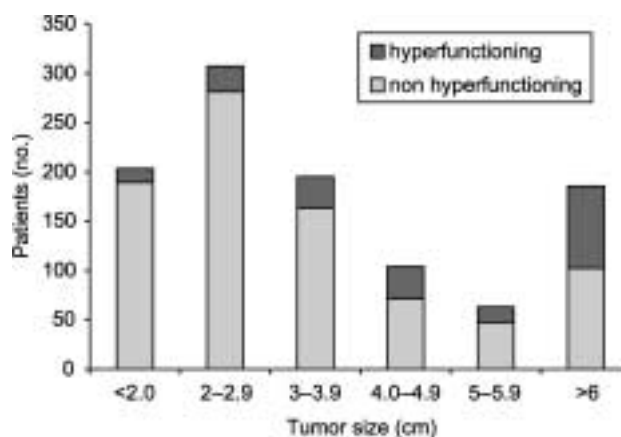


Figure 2 Distribution of adrenal incidentalomas ($n = 987$) according to size and functional status (hyperfunctioning vs non-hyperfunctioning). For review of the literature see references 16, 20, 53, 56, 63, 65. The prevalence of hormone hyperfunction was significantly higher among masses ≥ 4 cm in diameter (χ^2 ; $P < 0.001$).

Table 4 Etiology and relative frequency of adrenal incidentalomas.

Etiology	Frequency (%)
Adrenal cortical tumors	
Adenoma	36–94
Nodular hyperplasia	7–17
Carcinoma	1.2–11
Adrenal medullary tumors	
Pheochromocytoma	1.5–23
Ganglioneuroma	0–6
Ganglioneuroblastoma, neuroblastoma, carcinoma	<1
Other adrenal tumors	
Myelolipoma	7–15
Lipoma	0–11
Lymphoma, hemangioma, angiomyolipoma, hamartoma, liposarcoma, myoma, fibroma, neurofibroma, teratoma	<1
Cysts and pseudocysts	4–22
Hematoma and hemorrhage	0–4
Infections, granulomatosis	<1
Metastases (breast, kidney, lung, ovarian cancer, melanoma, Lymphoma, leukemia)	0–21
Pseudoadrenal masses (stomach, pancreas, kidney, liver, lymph node, vascular lesions, technical artifacts)	0–10

Modified from Barzon & Boscaro 2000 (76).

varies in different series, accounting for about 2% of cases in studies not including cancer patients, and 30–70% of cases in series including patients with known extra-adrenal cancers. Among adrenal incidentalomas, adrenal pseudotumors are radiological images

that seem to be of adrenal origin, but in reality arise from adjacent structures, such as kidney, spleen, pancreas, and lymph nodes. Occasionally, adrenal tumors of different natures may simultaneously be present in the same patient, e.g. a subclinical cortisol-secreting adenoma, an aldosteronoma, or a pheochromocytoma co-existing with a contralateral non-functioning mass (42, 77, 78), or adenomas with different pathological and hormonal features occurring within the same adrenal gland (79).

Subclinical hyperfunction

Upon accurate hormone assessment, most adrenal incidentalomas are non-hypersecreting; however, about 15% of cases show hypersecretion of either cortical or medullary hormones (Table 3). Adrenal hyperfunction seems to be more common in bilateral than in unilateral lesions (42). The mechanism of subclinical cortisol hypersecretion in bilateral adrenocortical lesions may involve aberrant expression of membrane hormone receptors, such as V1-vasopressin, luteinizing hormone/human chorionic gonadotropin, or serotonin receptors (80).

Subclinical hypercortisolism is the most common hormone abnormality detected in patients with adrenal incidentalomas (81, 82). The prevalence varies in different studies from 1 to 29%, with an average frequency of 9% (20, 21, 51, 53, 56–60, 64, 66–70, 83–90) (Table 5). The term subclinical or preclinical

Table 5 Prevalence of subclinical Cushing's syndrome (SCS) in patients with adrenal incidentalomas.

Study (reference)	Prevalence of SCS	Diagnostic criteria
Hensen <i>et al.</i> 1990 (83)	4/50 (8.0%)	Dex 1 mg
McLeod <i>et al.</i> 1990 (84)	6/122 (5.0%)	Cortisol rhythm, Dex 8 mg, ACTH, unilateral NP-59 scan
Reincke <i>et al.</i> 1992 (66)	8/68 (11.7%)	Dex 8 mg/2 days
Herrera <i>et al.</i> 1991 (20)	2/172 (1.1%)	Dex 2 mg or 8 mg
Siren <i>et al.</i> 1993 (85)	2/36 (5.5%)	Dex 1 mg, F, UFC
Caplan <i>et al.</i> 1994 (21)	3/26 (11.5%)	ACTH
Fernandez-Real <i>et al.</i> 1994 (86)	3/21 (14.3%)	Dex 8 mg
Osella <i>et al.</i> 1994 (64)	7/45 (15.6%)	Dex 1 mg
Seppel & Schlaghecke 1994 (68)	1/52 (1.9%)	Dex 1 mg, ACTH
Ambrosi <i>et al.</i> 1995 (51)	4/29 (13.7%)	Dex 1 mg + other abnormalities
Flecchia <i>et al.</i> 1995 (59)	7/24 (29.1%)	UFC, Dex 1 mg, ACTH
Bondanelli <i>et al.</i> 1997 (56)	4/38 (10.5%)	Dex 8 mg/2 days
Kasperlik-Zaluska <i>et al.</i> 1997 (60)	6/208 (2.9%)	Dex 8 mg/2 days
Terzolo <i>et al.</i> 1998 (87)	3/53 (5.7%)	Dex 1 mg + UFC
Rossi <i>et al.</i> 2000 (67)	12/65 (18.4%)	Dex 1 mg + another abnormal test
Mantero <i>et al.</i> 2000 (69)	92/1004 (9.2%)	≥2 abnormal tests
Morioka <i>et al.</i> 2000 (88)	7/56 (12.5%)	≥2 abnormal tests (Dex 1 mg, ACTH, UFC, cortisol rhythm, unilateral NP-59 scan)
Favia <i>et al.</i> 2000 (58)	8/158 (5.1%)	Dex 1 mg, plasma cortisol
Tanabe <i>et al.</i> 2001 (70)	18/38 (47.3%)	Dex 1 mg + Dex 8 mg*
Midorikawa <i>et al.</i> 2001 (89)	4/20 (20.0%)	Dex 8 mg/2 days
Grossrubatscher <i>et al.</i> 2001 (90)	3/53 (5.7%)	≥3 abnormal tests (UFC, ACTH, cortisol rhythm, Dex 1 mg, unilateral NP-59 scan)
Barzon <i>et al.</i> 2002 (53)	32/284 (11.3%)	Dex 1 mg + another abnormal test (UFC, cortisol rhythm, ACTH)
Total	236/2622 (9.0%)	

Dex, dexamethasone suppression test; UFC, urinary free cortisol; *criteria for normality: plasma cortisol after 1 mg dex <3 µg/dl, plasma cortisol after 8 mg dex <1 µg/dl. NP-59, [iodine-131]6-β-iodomethyl-19-norcholesterol.

Cushing's syndrome was first introduced by Charbonnel and coworkers in 1981 (81) to describe patients with adrenal incidentalomas and autonomous glucocorticoid production, but without specific signs and symptoms of overt Cushing's syndrome. Different diagnostic criteria have been used to define this condition (Table 5). Most authors employed the overnight low-dose dexamethasone suppression test as a screening tool to detect autonomous cortisol hypersecretion, but due to the high rate of false-positive results, confirmatory tests are usually recommended (76). On the other hand, revised criteria for a normal response to the low-dose dexamethasone suppression test have been suggested to improve its sensitivity and detect even subtle glucocorticoid autonomy (91–93). With these revised criteria, the prevalence of cortisol hypersecretion ranges from 30 to 50% of incidentally discovered adrenal adenomas (70, 92–94).

Aldosteronomas have been reported in 1.5–3.3% of adrenal incidentalomas (12, 16, 21, 42, 69). A recent study on normokalemic patients with adrenal incidentalomas found primary aldosteronism in 4.0% of all patients with adrenal incidentalomas and in 5.5% of those with hypertension (95), a prevalence higher than that found in the general hypertensive population.

Although at autopsy studies up to 76% of pheochromocytomas are clinically silent and unsuspected before death (96), the prevalence of pheochromocytomas in patients with adrenal incidentalomas is relatively low (1.5–11%) (1, 16, 18, 20, 42, 60, 64, 97, 98) and only 10–20% of pheochromocytomas are incidentally discovered (99–101). Patients with incidentally discovered pheochromocytoma are older than those with symptomatic pheochromocytoma; in half of the

cases, they are normotensive and often do not show any signs and symptoms (101, 102). Their catecholamine levels are significantly lower than those of patients with typical symptomatic pheochromocytomas (101, 102).

Natural history

The natural course of adrenal incidentalomas and the risk that such lesions evolve toward hormonal hypersecretion or malignancy are still under evaluation. Although there are only a few studies in the literature reporting long-term follow-up observation of adrenal incidentalomas, it seems that the majority of masses, classified as benign and non-hypersecreting at diagnosis, subsequently remains hormonally and morphologically unchanged (20, 53–56, 62, 64, 67, 71, 73, 87, 90, 103–108) (Table 6). Nonetheless, in a percentage which varies in different series, some cases develop mass enlargement and/or adrenal hyperfunction, ranging from 0 to 26% and from 0 to 11% respectively (Table 6).

Mass enlargement and risk of malignancy

In a review of 18 published series, including a total of 873 patients followed for a mean period of 3 years, 9% of cases showed mass enlargement greater than 1 cm and/or the appearance of another mass in the contralateral adrenal gland (Table 6). Mass enlargement was generally limited to 1–2 cm increase in diameter over a period of 1–3 years. Radiological images suggestive of malignancy together with mass enlargement, rather than a mere slight increase in mass size,

Table 6 Long-term follow-up of adrenal incidentalomas.

Study (reference)	Follow-up (years (range))	Mass size enlargement	Mass size reduction	Malignancy	Hyperfunction
Reincke <i>et al.</i> 1989 (103)	1.2 (0.5–4)	0/11 (0%)	0/11 (0%)	0/11 (0%)	0/11 (0%)
Virkkala <i>et al.</i> 1989 (73)	2 (0.8–4.1)	0/12 (0%)	1/12 (8.3%)	0/12 (0%)	0/12 (0%)
Herrera <i>et al.</i> 1991 (20)	2 (0.1–5.6)	5/159 (3.1%)	4/159 (2.5%)	0/159 (0%)	0/287 (0%)
Jockenhovel <i>et al.</i> 1992 (104)	2.7 (1–8.4)	1/18 (5.5%)	2/18 (11.1%)	0/18 (0%)	2/18 (11.1%)
Osella <i>et al.</i> 1994 (64)	1.0	2/9 (22.2%)	0/9 (0%)	0/9 (0%)	1/9 (11.1%)
Bencsik <i>et al.</i> 1995 (55)	1.5 (0.3–3.4)	1/27 (3.7%)	0/27 (0%)	0/27 (0%)	0/27 (0%)
Courtade <i>et al.</i> 1997 (105)	3.6 (0.3–6.3)	0/25 (0%)	10/25 (40%)	0/25 (0%)	0/32 (0%)
Bastounis <i>et al.</i> 1997 (54)	3.6 (1–5.3)	2/60 (3.3%)	0/60 (0%)	0/60 (0%)	0/60 (0%)
Bondanelli <i>et al.</i> 1997 (56)	(0.5–1.5)	1/14 (7.1%)	0/14 (0%)	0/14 (0%)	0/14 (0%)
Terzolo <i>et al.</i> 1998 (71)	1	1/41 (2.4%)	NA	0/41 (0%)	0/41 (0%)
Barry <i>et al.</i> 1998 (106)	7 (0.1–11.7)	4/91 (4.4%)	0/91 (0%)	0/224 (0%)	0/224 (0%)
Terzolo <i>et al.</i> 1998 (87)	>1	0/53 (0%)	0/53 (0%)	0/53 (0%)	0/53 (0%)
Rossi <i>et al.</i> 2000 (67)	3.2 (0.7–6.1)	1/32 (3.1%)	0/32 (0%)	0/32 (0%)	1/32 (3.1%)
Siren <i>et al.</i> 2000 (107)	7 (2–16.3)	4/21 (19.0%)	7/21 (33.3%)	0/21 (0%)	0/27 (0%)
Mantero <i>et al.</i> 2000 (62)	>1	14/53 (26.4%)	NA	0/53 (0%)	2/53 (3.8%)
Grossrubatscher <i>et al.</i> 2001 (90)	2 (0.5–6.5)	10/53 (18.9%)	1/53 (1.9%)	0/53 (0%)	0/53 (0%)
Barzon <i>et al.</i> 2002 (53)	4.6 (2–12)	19/130 (14.4%)	3/130 (2.3%)	0/130 (0%)	10/130 (7.7%)
Libè <i>et al.</i> 2002 (108)	2.1 (1–10)	13/64 (20.3%)	0/64 (0%)	1/64 (1.6%)	4/64 (6.2%)
Total		78/873 (9.0%)	28/779 (3.6%)	1/1081 (0.09%)	20/1147 (1.7%)

NA, not available.

should be considered more reliable indicators of tumor progression, since only one case was demonstrated to be a malignant tumor at follow-up. It was the case of a non-Hodgkin's lymphoma showing a conspicuous tumoral growth within a short period of time (108). The likelihood of malignant transformation at long-term follow-up for masses considered as benign at diagnosis is therefore minimal, and is estimated at one case per 1000 incidentalomas (Table 6). An anecdotal case of a small adrenocortical carcinoma evolving after diagnosis of subclinical Cushing's syndrome in a patient with an apparently benign adrenal incidentaloma has been reported in the literature (109). In our patient population, the case of a young woman referred for a 9 cm metastatic adrenocortical carcinoma associated with Cushing's syndrome is noteworthy. The patient, 2 years earlier, showed a 2.5 cm adrenal lesion in the course of ultrasonography for abdominal pain. Another interesting case was that of a female patient referred for a 6 cm incidentally discovered non-functioning adrenocortical carcinoma, which had increased 3 cm in size in 1 year at radiological imaging (authors' unpublished observations).

Reduction or even disappearance of the adrenal mass have been reported in up to 40% (mean, 3.6%) of adrenal incidentalomas, most often in the case of cystic lesions, hematomas, or adrenal pseudotumors (Table 6).

Incidentally discovered adrenocortical carcinoma

Adrenocortical carcinomas represent 5% of incidentalomas (Table 3). Most non-functioning adrenocortical carcinomas are incidentally discovered and account for about half of all adrenocortical carcinomas. These tumors are typically large masses at diagnosis, ranging from 3 to 20 cm in diameter (mean 8 cm), with distant metastases in 20–50% of cases (110–113). Our patients with incidentally discovered carcinomas ($n = 28$) had a significantly longer survival than those with non-incidentally discovered carcinomas ($n = 40$) (79% survival rate vs 73.9% at 1 year from diagnosis respectively, and 50% vs 24% at 5 years from diagnosis respectively), even though tumor size and staging were similar between the two groups (authors' unpublished observations). However, other investigators have reported similar staging of disease at diagnosis and survival rates between incidentally discovered adrenocortical carcinomas and non-incidentally discovered carcinomas (111–114). Indeed, the incidental identification of asymptomatic adrenocortical incidentalomas seems to have led to only a very modest reduction in the number of patients who present with metastatic disease (113, 115).

Hormone production

Overall, out of 1147 patients with adrenal incidentalomas from the literature, 20 (1.7%) developed adrenal

hyperfunction during follow-up, in a percentage ranging in different studies from 0 to 11% (Table 6). Out of these patients, 13 (0.65%) developed subclinical hypercortisolism, six (0.3%) overt Cushing's syndrome, and one (0.05%) catecholamine hypersecretion (53, 62, 104). In our recent follow-up study of 130 patients with adrenal incidentalomas, the estimated cumulative risk to develop either subclinical or overt glucocorticoid hypersecretion was 3.8% after 1 year and 6.6% after 5 years (53). Development of primary hyperaldosteronism and catecholamine hypersecretion during follow-up seems extremely rare, since no cases of hyperaldosteronism and only one of pheochromocytoma (116) have been reported (Table 6).

From subclinical Cushing's syndrome to overt Cushing's syndrome

The risk of progression from subclinical to overt Cushing's syndrome is controversial. Terzolo *et al.* (87) reported a spontaneous endocrine normalization in 50% of patients with subclinical hypercortisolism, whereas no patient developed clinical Cushing's syndrome. At variance, in other reports subclinical hypercortisolism persisted throughout follow-up or became clinically evident in some patients (62, 67, 83, 90, 104, 116). In our experience, one out of eight patients with subclinical Cushing's syndrome at diagnosis developed overt Cushing's syndrome during follow-up (53). Moreover, of the seven patients reported in the literature (including four patients of our own) who developed Cushing's syndrome during follow-up, only three already had subclinical hypercortisolism at the time of adrenal mass discovery (53, 62, 83, 104, 116). In two of these cases, a concomitant adrenal mass enlargement was observed (53, 104). A slight increase of tumor size may also occur in patients with subclinical Cushing's syndrome who do not demonstrate worsening of their endocrine function (53, 67, 116).

Even though, by definition, no clinical sign or symptom of Cushing's syndrome should be present, patients with adrenal incidentalomas and especially those with subclinical Cushing's syndrome have a higher prevalence of hypertension (40–90% of cases), obesity (35–50%), diabetes mellitus or glucose intolerance (20–75%), hyperlipidemia (50%), or osteopenia (40–50%) than the general population (42, 51, 64, 66, 67, 89, 94, 117–123). Whether these features, which are typical of the metabolic syndrome, will have an impact on the long-term morbidity of patients with subclinical Cushing's syndrome remains to be determined. Long-term perspective studies are lacking; however, an amelioration of clinical or biochemical abnormalities in patients with subclinical hypercortisolism after surgery has been reported (42, 51, 53, 66, 67, 88–90). Improvement of blood pressure, obesity, metabolic abnormalities, collagen and bone turnover markers was observed after adrenalectomy in patients

with subclinical Cushing's syndrome (51, 66, 67). In particular, Midorikawa *et al.* (89) demonstrated an improvement in systolic blood pressure and insulin resistance after adrenalectomy both in patients with subclinical Cushing's syndrome and in those with non-functioning cortical adenoma, but not in patients with non-cortical tumors (89). Cross-sectional and case-control studies indicate that the degree of metabolic abnormalities in patients with adrenal incidentalomas is directly related to the severity of the hypercortisolism (94, 118, 121–124). Thus, subtle cortisol hypersecretion by apparently non-functioning adrenal adenomas might be the cause of insulin resistance and other features of the metabolic syndrome in such patients (118). An alternative hypothesis was suggested by Reincke *et al.* (125), based on the observation that insulin has a mitogenic effect on adrenocortical cells without affecting cortisol synthesis. They proposed the adrenal incidentaloma as an insulin-mediated tumoral manifestation of the metabolic syndrome, similar to the insulin-mediated ovary overgrowth seen in polycystic ovary syndrome. Other potential effects of hypercortisolism, such as cardiovascular disease, thrombophilia, and psychiatric disturbances, remain to be investigated in patients with adrenal incidentalomas. Increased cardiovascular risk has been recently demonstrated in patients with subclinical Cushing's syndrome (126). Abnormalities of coagulative parameters and mood disturbances were observed in our patients with subclinical Cushing's syndrome who subsequently developed the overt condition (53).

Analysis of risk factors

Patients with subclinical hypercortisolism or with large masses at diagnosis are considered to be at risk for progression toward overt Cushing's syndrome or malignancy respectively. However, no long-term perspective follow-up studies of adrenal incidentalomas with analysis of prognostic factors have been performed, except for the study we conducted in a cohort of 75 patients with non-hypersecreting, apparently benign, adrenocortical incidentalomas (116). In our experience, the majority of patients maintained unchanged mass size and hormonal function throughout follow-up. Out of 75 patients, only 17 showed changes in the mass size and/or developed endocrine hyperfunction. By analysis of risk factors (i.e. sex, age, presence of obesity, hypertension, diabetes mellitus, abnormal endocrine tests at diagnosis, mass size, mass location, and scintigraphic uptake pattern), we have demonstrated how the presence of isolated endocrine test abnormalities at diagnosis had predictive value for mass enlargement or development of bilateral masses (116). On the other hand, mass size of 3 cm or more at diagnosis and exclusive radiocholesterol

uptake by the mass with no visualization of the contralateral adrenal gland at scintigraphy had relevance for the occurrence of adrenal hyperfunction (116). Development of endocrine hyperfunction was more frequent in female, older, hypertensive subjects with endocrine abnormalities at diagnosis, although the association was not statistically significant (116). A relationship between tumor size and adrenocortical function (42, 116) was also reported by others (59, 94, 117) (Fig. 2). It is conceivable that adrenal tumors increase their cortisol secretion as they increase in volume and acquire glucocorticoid autonomy when a given size is reached. Our results have been confirmed by Libè *et al.* (108) who demonstrated that mass size greater than 3 cm and endocrine abnormalities at diagnosis were risk factors for adrenal hyperfunction and mass enlargement respectively.

As to the role of adrenocortical scintigraphy as a predictive factor for adrenal hyperfunction, findings of an increased risk of adrenal hyperfunction in patients showing exclusive uptake by the adrenal mass indicate that this scintigraphic pattern may represent an early phase of functional autonomy of the adrenal adenomas also in the case of apparently normal hormone function (42, 52, 67, 92, 127). Indeed, a mild degree of autonomy is demonstrated by lack of complete suppression after low-dose dexamethasone (92, 93). Since adrenal scintiscan may not be available in all centers, the 1 mg overnight dexamethasone suppression test may be a rapid and convenient tool to identify patients at risk for disease progression. With revised cut-off levels for a normal response, this test shows a good correlation with scintigraphic patterns and a high sensitivity in the detection of mild subclinical hypercortisolism (92, 93).

Causes of death

In the vast majority of patients with apparently benign adrenal incidentalomas, death is not directly related to the adrenal mass, but to cardiovascular accidents, malignancy, and chronic disorders, as observed in the general population (106, 107, 116). Barry *et al.* (106) reported the causes of death in 81 out of 224 patients followed for adrenal incidentalomas. All patients died of conditions unrelated to adrenal pathology, i.e. cardiac disease in 43%, malignancy in 22%, chronic obstructive pulmonary diseases in 11%, Alzheimer's disease in 6%, cerebrovascular accident in 4%, pneumonia or sepsis in 4%, ruptured abdominal aortic aneurysm in 2.5%, diabetic renal failure in 2.5%, and other causes in 5%. Also in the series reported by Siren *et al.* (107), including 21 patients with adrenal incidentaloma, the most common causes of death were related to cardiovascular disease (acute myocardial infarction, ventricular arrhythmia, cardiac failure, multi-infarct dementia, and acute cerebrovascular

infarct), which occurred in seven out of nine deaths, whereas pulmonary embolism secondary to deep vein thrombosis and lung cancer occurred in two. Mean age at death was 72.8 years. Whether the relatively high rate of mortality due to cardiovascular disease is related to hypercortisolism was not investigated.

Conclusions

A comprehensive review of the literature shows the prevalence of adrenal incidentalomas to be 2.3% at autopsy and 0.5–2% at abdominal CT scan. With the improvement in imaging techniques and the increasing use of abdominal imaging, the incidental discovery of adrenal masses will continue to increase. Most lesions are adrenocortical adenomas at histology, whereas the prevalence of adrenocortical carcinomas is relatively low. The risk of malignancy over time for masses defined as benign at diagnosis is estimated to be about 1/1000, even though 5–25% of masses increase in size during follow-up. Hyperfunction develops in about 1.7% of cases, with percentages ranging from 0 to 11%, and the risk is higher in patients with lesions larger than 3 cm and/or with unilateral radio-tracer uptake at scintigraphy. Cortisol hypersecretion is the most likely disorder that may ensue, and it remains subclinical in about two-thirds of cases. Morbidity that may derive from subclinical hormone hypersecretion should always be weighed in the management of adrenal incidentalomas. The lack of controlled studies precludes making specific management recommendations. Large perspective controlled studies to define the epidemiology, natural history, and possible associated morbidity of adrenal incidentalomas and their impact on the quality of life of patients are needed.

References

- Kloos RT, Gross MD, Francis IR, Korobkin M & Shapiro B. Incidentally discovered adrenal masses. *Endocrine Reviews* 1995 **16** 460–484.
- Grumbach MM, Biller MK, Braunstein GD, Campbell KK, Carney JA, Godley PA *et al.* Management of the clinically inapparent adrenal mass ('incidentaloma'). *Annals of Internal Medicine* 2003 **138** 424–429.
- Rineheart JE, Williams OO & Cappeller WS. Adenomatous hyperplasia of the adrenal cortex associated with essential hypertension. *Archives of Pathology* 1941 **34** 1031–1034.
- Russi S, Blumenthal HT & Gray SH. Small adenomas of the adrenal cortex in hypertension and diabetes. *Archives of Internal Medicine* 1945 **76** 284–291.
- Commons RR & Callaway CP. Adenomas of the adrenal cortex. *Archives of Internal Medicine* 1948 **81** 37–41.
- Schroeder HA. Clinical types – the endocrine hypertensive syndrome. In *Hypertensive Diseases: Causes and Control*, pp 295–333. Ed. HA Schroeder. Philadelphia: Lea & Febiger, 1953.
- Devenyi I. Possibility of normokalaemic primary aldosteronism as reflected in the frequency of adrenal cortical adenomas. *Journal of Clinical Pathology* 1967 **20** 49–51.
- Kokko JP, Brown TC & Berman MM. Adrenal adenoma and hypertension. *Lancet* 1967 **i** 468–470.
- Hedeland H, Ostberg G & Hokfelt B. On the prevalence of adrenocortical adenomas in an autopsy material in relation to hypertension and diabetes. *Acta Medica Scandinavica* 1968 **184** 211–214.
- Yamada EY & Fukunaga FH. Adrenal adenoma and hypertension. A study in the Japanese in Hawaii. *Japanese Heart Journal* 1969 **10** 11–19.
- Granger P & Genest J. Autopsy study of adrenal in unselected normotensive and hypertensive patients. *Canadian Medical Association Journal* 1970 **103** 34–36.
- Russell RP, Masi AT & Ritcher ED. Adrenal cortical adenomas and hypertension. A clinical pathologic analysis of 690 cases with matched controls and a review of the literature. *Medicine* 1972 **51** 211–225.
- Abecassis M, McLoughlin MJ, Langer B & Kudlow JE. Serendipitous adrenal masses: prevalence, significance, and management. *American Journal of Surgery* 1985 **149** 783–788.
- Meagher AP, Hugh TB, Casey JH, Chisholm DJ, Farrell JC & Yates M. Primary adrenal tumors – a ten years experience. *Australian and New Zealand Journal of Surgery* 1988 **58** 457–462.
- Reinhard C, Saeger W & Schubert B. Adrenocortical nodules in post-mortem series. Development, functional significance, and differentiation from adenomas. *General and Diagnostic Pathology* 1996 **141** 203–208.
- Aso Y & Homma Y. A survey on incidental adrenal tumors in Japan. *Journal of Urology* 1992 **147** 1478–1481.
- Glazer HS, Weyman PJ, Sagel SS, Levitt RG & McClellan BL. Nonfunctioning adrenal masses: incidental discovery on computed tomography. *American Journal of Roentgenology* 1982 **139** 81–85.
- Prinz RA, Brooks MH, Churchill R, Graner JL, Lawrence AM, Paloyan E, Sparagana M *et al.* Incidental asymptomatic adrenal masses detected by computed tomographic scanning. Is operation required? *Journal of the American Medical Association* 1982 **248** 701–704.
- Belldegrun A, Hussain S, Seltzer SE, Loughlin KR, Gittes RF & Richie JP. Incidentally discovered mass of the adrenal gland. *Surgery Gynecology and Obstetrics* 1986 **163** 203–208.
- Herrera ME, Grant CS, van Heerden JA, Sheedy PF & Ilstrup DM. Incidentally discovered adrenal tumors: an institutional perspective. *Surgery* 1991 **110** 1014–1021.
- Caplan RH, Strutt PJ & Wickus GG. Subclinical hormone secretion by incidentally discovered adrenal masses. *Archives of Surgery* 1994 **129** 291–296.
- Francis IR, Smid A, Gross MD, Shapiro B, Naylor B & Glazer GM. Adrenal masses in oncologic patients: functional and morphologic evaluation. *Radiology* 1988 **166** 353–356.
- Lam KY & Lo CY. Metastatic tumors of the adrenal glands: a 30 years experience in a teaching hospital. *Clinical Endocrinology* 2002 **56** 95–101.
- Lee JE, Evans DB, Hickey RC, Sherman SI, Gagel RF, Abbruzzese MC *et al.* Unknown primary cancer presenting as an adrenal mass: frequency and implications for diagnostic evaluation of adrenal incidentalomas. *Surgery* 1998 **124** 1115–1122.
- Hess KR, Abbruzzese MC, Lenzi R, Raber MN & Abbruzzese JL. Classification and regression tree analysis of 1000 consecutive patients with unknown primary carcinoma. *Clinical Cancer Research* 1999 **5** 3403–3410.
- Hemminki K & Jiang Y. Second primary neoplasms after 19281 endocrine gland tumors: aetiological links? *European Journal of Cancer* 2001 **37** 1886–1894.
- Skogseid B, Larsson C, Lindgren P, Kvanta E, Rastad J, Theodorsson E *et al.* Clinical and genetic features of adrenocortical lesions in multiple endocrine neoplasia type 1. *Journal of Clinical Endocrinology and Metabolism* 1992 **75** 76–81.
- Burgess JR, Harle RA, Tucker P, Parameswaran V, Davies P, Greenaway TM *et al.* Adrenal lesions in a large kindred with

- multiple endocrine neoplasia type 1. *Archives of Surgery* 1996 **131** 699–702.
- 29 Barzon L, Pasquali C, Grigoletto C, Pedrazzoli S, Boscaro M & Fallo F. Multiple endocrine neoplasia type 1 and adrenal lesions. *Journal of Urology* 2001 **166** 24–27.
- 30 Neumann H, Berger DP, Sigmund G, Blum U, Schmidt D, Parmer RJ *et al.* Pheochromocytomas, multiple endocrine neoplasia type 2, and von Hippel–Lindau disease. *New England Journal of Medicine* 1993 **329** 1531–1538.
- 31 Dluhy RG. Pheochromocytoma – death of an axiom. *New England Journal of Medicine* 2002 **346** 1486–1488.
- 32 Aprill BS, Drake AJ, Lasseter DH & Shakir M. Silent adrenal nodules in von Hippel–Lindau disease suggest pheochromocytoma. *Annals of Internal Medicine* 1994 **120** 485–487.
- 33 Neumann H, Baucsh B, McWhinney SR, Bender BU, Gimm O, Franke G *et al.* Germ-line mutations in nonsyndromic pheochromocytoma. *New England Journal of Medicine* 2002 **346** 1459–1466.
- 34 Walther MM, Herring J, Enquist E, Keiser HR & Linehan WM. von Recklinghausen's disease and pheochromocytomas. *Journal of Urology* 1999 **162** 1582–1586.
- 35 Stratakis CA, Kirschner LS & Carney JA. Clinical and molecular features of the Carney Complex: diagnostic criteria and recommendations for patient evaluation. *Journal of Clinical Endocrinology and Metabolism* 2001 **86** 4041–4046.
- 36 Varley JM, Evans DG & Birch JM. Li-Fraumeni syndrome – a molecular and clinical review. *British Journal of Cancer* 1997 **76** 1–14.
- 37 Marchesa P, Fazio VW, Church JM & McGannon E. Adrenal masses in patients with familial adenomatous polyposis. *Diseases of the Colon and Rectum* 1997 **40** 1023–1028.
- 38 Smith TG, Clark SK, Katz DE, Reznick RH & Phillips RK. Adrenal masses are associated with familial adenomatous polyposis. *Diseases of the Colon and Rectum* 2000 **43** 1739–1742.
- 39 Wiedemann HR, Burgio GR, Aldenhoff P, Kunze J, Kaufmann HJ & Schirg E. The proteus syndrome. Partial gigantism of the hands and/or feet, nevi, hemihypertrophy, subcutaneous tumors, macrocephaly or other skull anomalies and possible accelerated growth and visceral affections. *European Journal of Pediatrics* 1983 **140** 5–12.
- 40 Ravichandran R, Lafferty F, McGinniss MJ & Taylor HC. Congenital adrenal hyperplasia presenting as massive adrenal incidentalomas in the sixth decade of life: report of two patients with 21-hydroxylase deficiency. *Journal of Clinical Endocrinology and Metabolism* 1996 **81** 1776–1779.
- 41 Nagasaka S, Kubota K, Motegi T, Hayashi E, Ohta M, Takahashi K *et al.* A case of silent 21-hydroxylase deficiency with persistent adrenal insufficiency after removal of an adrenal incidentaloma. *Clinical Endocrinology* 1996 **44** 111–116.
- 42 Barzon L, Scaroni C, Sonino N, Fallo F, Gregianin M, Macri C *et al.* Incidentally discovered adrenal tumors: endocrine and scintigraphic correlates. *Journal of Clinical Endocrinology and Metabolism* 1998 **83** 55–62.
- 43 Kacem M, Said M, Achour L, Hadj Youssef F, Ben Kacem S, Mahjoub S *et al.* Large bilateral adrenal incidentalomas complicating untreated 11 β hydroxylase deficiency in the third decade of life. A case report. *Annales d'Endocrinologie* 2000 **61** 418–421.
- 44 Kjellman M, Holst M, Backdahl M, Larsson C, Farnebo L-O & Wedell A. No overrepresentation of congenital adrenal hyperplasia in patients with adrenocortical tumours. *Clinical Endocrinology* 1999 **50** 343–346.
- 45 Beuschlein F, Schulze E, Mora P, Gensheimer HP, Maser-Gluth C, Allolio B *et al.* Steroid 21-hydroxylase mutations and 21-hydroxylase messenger ribonucleic acid expression in human adrenocortical tumors. *Journal of Clinical Endocrinology and Metabolism* 1998 **83** 2585–2588.
- 46 Maser-Gluth C, Reinke M, Allolio B & Schulze E. Metabolism of glucocorticoids and mineralocorticoids in patients with adrenal incidentalomas. *European Journal of Clinical Investigation* 2000 **30** 83–86.
- 47 Jaresch S, Kornely E, Kley HK & Schlaghecke R. Adrenal incidentaloma and patients with homozygous or heterozygous congenital adrenal hyperplasia. *Journal of Clinical Endocrinology and Metabolism* 1992 **74** 685–689.
- 48 Sadoul JL, Kezachian B, Altare S, Hadjali Y & Canivet B. Apparent activities of 21-hydroxylase, 17 α -hydroxylase and 17,20-lyase are impaired in adrenal incidentalomas. *European Journal of Endocrinology* 1999 **141** 238–245.
- 49 Toth M, Racz K, Adleff V, Varga I, Futo L, Jakab C *et al.* Comparative analysis of plasma 17-hydroxyprogesterone and cortisol responses to ACTH in patients with various adrenal tumors before and after unilateral adrenalectomy. *Journal of Endocrinological Investigation* 2000 **23** 287–294.
- 50 Dall'Asta C, Barbetta L, Libe R, Passini E & Ambrosi B. Coexistence of 21-hydroxylase and 11 beta-hydroxylase deficiency in adrenal incidentalomas and in subclinical Cushing's syndrome. *Hormone Research* 2002 **57** 192–196.
- 51 Ambrosi B, Peverelli S, Passini E, Re T, Ferrario R, Colombo P *et al.* Abnormalities of endocrine function in patients with clinically 'silent' adrenal masses. *European Journal of Endocrinology* 1995 **132** 422–428.
- 52 Bardet S, Rhomer V, Murat A, Guillemot C, Marechaud R & Chupin M. ¹³¹I-Iodomethylnorcholesterol scintigraphy: an assessment of its role in the investigation of adrenocortical incidentalomas. *Clinical Endocrinology* 1996 **44** 587–596.
- 53 Barzon L, Fallo F, Sonino N & Boscaro M. Development of overt Cushing's syndrome in patients with adrenal incidentalomas. *European Journal of Endocrinology* 2002 **146** 61–66.
- 54 Bastounis EA, Karayiannakis AJ, Anapliotou MLG, Nakopoulou L, Makri GG & Papalambros EL. Incidentalomas of the adrenal gland: diagnostic and therapeutic implications. *American Surgeon* 1997 **63** 356–360.
- 55 Bencsik Z, Szabolcs I, Goth M, Voros A, Kaszas I, Gonczi J *et al.* Incidentally detected adrenal tumors (incidentalomas): histological heterogeneity and differential therapeutic approach. *Journal of Internal Medicine* 1995 **237** 585–589.
- 56 Bondanelli M, Campo M, Trasforini G, Ambrosio MR, Zatelli MC, Franceschetti P *et al.* Evaluation of hormonal function in a series of incidentally discovered adrenal masses. *Metabolism* 1997 **46** 107–113.
- 57 Bulow B & Ahren B. Adrenal incidentaloma – experience of a standardized diagnostic programme in the Swedish prospective study. *Journal of Internal Medicine* 2002 **252** 239–246.
- 58 Favia G, Lumachi F, Basso S & D'Amico DE. Management of incidentally discovered adrenal masses and risk of malignancy. *Surgery* 2000 **128** 918–924.
- 59 Flecchia D, Mazza E, Carlini M, Blatto A, Olivieri F, Serra G *et al.* Reduced serum levels of dehydroepiandrosterone sulphate in adrenal incidentalomas: a marker of adrenocortical tumor. *Clinical Endocrinology* 1995 **42** 129–134.
- 60 Kasperlik-Zaluska AA, Roslonowska E, Slowinska-Szrednicka J, Tolloczko T, Szamowska R, Leowska E *et al.* Incidentally discovered adrenal mass (incidentaloma): investigation and management of 208 patients. *Clinical Endocrinology* 1997 **46** 29–37.
- 61 Linos DA, Stylopoulos N & Raptis SA. Adrenaloma: a call for a more aggressive management. *World Journal of Surgery* 1996 **20** 788–793.
- 62 Mantero F & Arnaldi G. Management approaches to adrenal incidentalomas: a view from Ancona, Italy. *Endocrinology and Metabolism Clinics of North America* 2000 **29** 107–111.
- 63 Murai M, Baba S, Nakashima J & Tachibana M. Management of incidentally discovered adrenal masses. *World Journal of Urology* 1999 **17** 9–14.
- 64 Osella G, Terzolo M, Borretta G, Magro G, Ali A, Piovesan A *et al.* Endocrine evaluation of incidentally discovered adrenal masses. *Journal of Clinical Endocrinology and Metabolism* 1994 **79** 1532–1539.

- 65 Proye C, Jafari Manjili M, Combemale F, Pattou F, Ernst O, Carnaille B *et al.* Experience gained from operation of 103 adrenal incidentalomas. *Langenbeck's Archives of Surgery* 1998 **383** 330–333.
- 66 Reincke M, Nieke J, Krestin GP, Saeger W, Allolio B & Wienkelmann W. Preclinical Cushing's syndrome in adrenal 'incidentalomas': comparison with adrenal Cushing's syndrome. *Journal of Clinical Endocrinology and Metabolism* 1992 **75** 826–832.
- 67 Rossi R, Tauchmanova L, Luciano A, Di Martino M, Battista C, Del Viscovo L *et al.* Subclinical Cushing's syndrome in patients with adrenal incidentaloma: clinical and biochemical features. *Journal of Clinical Endocrinology and Metabolism* 2000 **85** 1440–1448.
- 68 Seppel T & Schlaghecke R. Augmented 14 α -hydroxyprogesterone response to ACTH stimulation as evidence of decreased 21-hydroxylase activity in patients with incidentally discovered adrenal tumours ('incidentalomas'). *Clinical Endocrinology* 1994 **41** 445–451.
- 69 Mantero F, Terzolo M, Arnaldi G, Osella G, Masini AM, Ali A *et al.* A survey on adrenal incidentaloma in Italy. *Journal of Clinical Endocrinology and Metabolism* 2000 **85** 637–644.
- 70 Tanabe A, Naruse M, Nishikawa T, Yoshimoto T, Shimizu T, Seki T *et al.* Autonomy of cortisol secretion in clinically silent adrenal incidentaloma. *Hormone and Metabolic Research* 2001 **33** 444–450.
- 71 Terzolo M, Ali A, Osella G & Mazza E. Prevalence of adrenal carcinoma among incidentally discovered adrenal masses. A retrospective study from 1989 to 1994. Gruppo Piemontese Incidentalomi Surrenali. *Archives of Surgery* 1997 **132** 914–919.
- 72 Tutuncu NB & Gedik O. Adrenal incidentaloma: report of 33 cases. *Journal of Surgical Oncology* 1999 **70** 247–250.
- 73 Virkkala A, Valimaki M, Pelkonen R, Huikuri K, Kahri A, Kivisaari L *et al.* Endocrine abnormalities in patients with adrenal tumours incidentally discovered on computed tomography. *Acta Endocrinologica* 1989 **121** 67–72.
- 74 Linos DA & Stylopoulos N. How accurate is computed tomography in predicting the real size of adrenal tumors? *Archives of Surgery* 1997 **132** 740–743.
- 75 Ichijo T, Ueshiba H, Yakushiji F, Nakamura T & Miyachi Y. A survey on adrenal incidentalomas in Japan. *Proceedings of the 84th Meeting of the Endocrine Society*, Abstract OR25-4, 2002.
- 76 Barzon L & Boscaro M. Diagnosis and management of adrenal incidentalomas. *Journal of Urology* 2000 **163** 398–407.
- 77 Fallo F, Barzon L, Boscaro M & Sonino N. Coexistence of aldosteronoma and contralateral nonfunctioning adrenal adenoma in primary aldosteronism. *American Journal of Hypertension* 1997 **10** 476–478.
- 78 Morimoto S, Sasaki S, Moriguchi J, Miki S, Kawa T, Nakamura K *et al.* Unique association of pheochromocytoma with contralateral nonfunctioning adrenal cortical adenoma. *American Journal of Hypertension* 1998 **11** 117–121.
- 79 Satoh F, Murakami O, Takahashi K, Ueno J, Nishikawa T, Abe K *et al.* Double adenomas with different pathological and hormonal features in the left adrenal gland of a patient with Cushing's syndrome. *Clinical Endocrinology* 1997 **46** 227–234.
- 80 Bourdeau I, D'Amour P, Hamet P, Boutin J-M & Lacroix A. Aberrant membrane hormone receptors in incidentally discovered bilateral macronodular adrenal hyperplasia with subclinical Cushing's syndrome. *Journal of Clinical Endocrinology and Metabolism* 2001 **86** 5534–5540.
- 81 Charbonnel B, Chatal JF & Ozanne P. Does the corticoadrenal adenoma with pre-Cushing's syndrome exist? *Journal of Nuclear Medicine* 1981 **22** 1059–1061.
- 82 Reincke M. Subclinical Cushing's syndrome. *Endocrinology and Metabolism Clinics of North America* 2000 **29** 42–56.
- 83 Hensen J, Buhl M, Bahr V & Oelkers W. Endocrine activity of the 'silent' adrenocortical adenoma is uncovered by response to corticotropin-releasing hormone. *Klinische Wochenschrift* 1990 **68** 608–614.
- 84 McLeod MK, Thompson NW, Gross MD, Bondeson AG & Bondeson L. Sub-clinical Cushing's syndrome in patients with adrenal gland incidentalomas. *American Surgeon* 1990 **56** 398–403.
- 85 Siren J, Haapiainen R, Huikuri K & Sivula A. Incidentalomas of the adrenal gland: 36 operated patients and review of literature. *World Journal of Surgery* 1993 **17** 634–639.
- 86 Fernandez-Real JM, Richart Engel W & Simò R. Pre-clinical Cushing's syndrome: Report of three cases and literature review. *Hormone Research* 1994 **41** 230–235.
- 87 Terzolo M, Osella G, Ali A, Borretta G, Cesario F, Paccotti P *et al.* Subclinical Cushing's syndrome in adrenal incidentaloma. *Clinical Endocrinology* 1998 **48** 89–97.
- 88 Morioka M, Fujii T, Matsuki T, Jo Y, Kobayashi T, Tanaka H *et al.* Preclinical Cushing's syndrome: report on seven cases and review of the literature. *International Journal of Urology* 2000 **7** 126–132.
- 89 Midorikawa S, Sanada H, Hashimoto S, Suzuki T & Watanabe T. The improvement of insulin resistance in patients with adrenal incidentaloma by surgical resection. *Clinical Endocrinology* 2001 **54** 797–804.
- 90 Grossrubatscher E, Vignati F, Possa M & Loli P. The natural history of incidentally discovered adrenocortical adenomas: a retrospective evaluation. *Journal of Endocrinological Investigation* 2001 **24** 846–855.
- 91 Lavoie H & Lacroix A. Partially autonomous cortisol secretion by incidentally discovered adrenal adenomas. *Trends in Endocrinology and Metabolism* 1995 **6** 191–197.
- 92 Valli N, Catargi B, Ronci N, Vergnot V, Leccia F, Ferriere JM *et al.* Biochemical screening for subclinical cortisol-secreting adenomas amongst adrenal incidentalomas. *European Journal of Endocrinology* 2001 **144** 401–408.
- 93 Barzon L, Fallo F, Sonino N & Boscaro M. Overnight dexamethasone suppression of cortisol is associated with radiocholesterol uptake patterns in adrenal incidentalomas. *European Journal of Endocrinology* 2001 **144** 223–224.
- 94 Tsagarakis S, Roboti C, Kokkoris P, Vasiliou V, Alevizaki C & Thalassinou N. Elevated post-dexamethasone suppression cortisol concentrations correlate with hormonal alterations of the hypothalamo-pituitary adrenal axis in patients with adrenal incidentalomas. *Clinical Endocrinology* 1998 **48** 165–171.
- 95 Bernini GP, Moretti A, Argenio G & Salvetti A. Primary aldosteronism in normokalemic patients with adrenal incidentalomas. *European Journal of Endocrinology* 2002 **146** 523–529.
- 96 Bravo EL. Evolving concepts in the pathophysiology, diagnosis, and treatment of pheochromocytoma. *Endocrine Reviews* 1994 **15** 356–368.
- 97 Sutton MG, Sheps SG & Lie JT. Prevalence of clinically unsuspected pheochromocytoma. Review of a 50-year autopsy series. *Mayo Clinic Proceedings* 1981 **56** 354–360.
- 98 Bernini GP, Vivaldi MS, Argenio GF, Moretti A, Sgro M & Salvetti A. Frequency of pheochromocytoma in adrenal incidentalomas and utility of the glucagon test for the diagnosis. *Journal of Endocrinological Investigation* 1997 **20** 65–71.
- 99 Mannelli M, Ianni L, Cilotti A & Conti A. Pheochromocytoma in Italy: a multicentric retrospective study. *European Journal of Endocrinology* 1999 **141** 619–624.
- 100 Kudva YC, Young WF Jr, Thompson GB, Grant CS & van Heerden JA. Adrenal incidentaloma: an important component of the clinical presentation spectrum of benign sporadic adrenal pheochromocytoma. *Endocrinologist* 1999 **9** 77–80.
- 101 Noshiro T, Shimizu K, Watanabe T, Akama H, Shibukawa S, Miura W *et al.* Changes in clinical features and long-term prognosis in patients with pheochromocytoma. *American Journal of Hypertension* 2000 **13** 35–43.
- 102 Miyajima A, Nakashima J, Baba S, Tachibana M, Nakamura K & Murai M. Clinical experience with incidentally discovered pheochromocytoma. *Journal of Urology* 1997 **157** 1566–1568.

- 103 Reincke M, Winkelmann W, Jaursch-Hancke C, Kaulen D, Nieke J, Ollenschlager G *et al.* Diagnostik und Therapie asymptomatischer Nebennierentumoren. *Deutsche Medizinische Wochenschrift* 1989 **114** 861–865.
- 104 Jockenhovel F, Kuck W, Hauffa B, Reinhardt W, Benker G, Lederbogen S *et al.* Conservative and surgical management of incidentally discovered adrenal tumors (incidentalomas). *Journal of Endocrinological Investigation* 1992 **15** 331–337.
- 105 Courtade A, Carnaille B, Ernst O, Renan CA, L'Herminé C & Proye C. Outcome of incidental adrenal masses not operated on: 44 cases over 7 years. *European Journal of Surgery* 1997 **163** 315.
- 106 Barry MK, van Heerden JA, Farley DR, Grant CS, Thompson GB & Ilstrup DM. Can adrenal incidentalomas be safely observed? *World Journal of Surgery* 1998 **22** 599–603.
- 107 Siren J, Tervahartiala P, Sivula A & Haapiainen R. Natural course of adrenal incidentalomas: seven-year follow-up study. *World Journal of Surgery* 2000 **24** 579–582.
- 108 Libè R, Dall'Asta C, Barbetta L, Baccarelli A, Beck-Peccoz P & Ambrosi B. Long-term follow-up study of patients with adrenal incidentalomas. *European Journal of Endocrinology* 2002 **147** 489–494.
- 109 Hoffe G, Gasser RW, Lhotta K, Janetschek G, Kreczy A & Finkenstedt G. Adrenocortical carcinoma evolving after diagnosis of preclinical Cushing's syndrome in an adrenal incidentaloma: a case report. *Hormone Research* 1998 **50** 237–242.
- 110 Barzon L, Zucchetto P, Boscaro M, Marzola MC, Bui F & Fallo F. Scintigraphic patterns of adrenocortical carcinomas: morpho-functional correlates. *European Journal of Endocrinology* 2001 **145** 743–748.
- 111 Favia G, Lumachi F & D'Amico DE. Adrenocortical carcinoma: is prognosis different in nonfunctioning tumors? Results of surgical treatment in 31 patients. *World Journal of Surgery* 2001 **25** 735–738.
- 112 Kasperlik-Zaluska AA, Migdalska B & Makowska A. Incidentally found adrenocortical carcinoma. A study of 21 patients. *European Journal of Cancer* 1998 **34** 1721–1724.
- 113 Vassilopoulou-Sellin R & Schultz PN. Adrenocortical carcinoma. Clinical outcome at the end of the 20th century. *Cancer* 2001 **92** 1113–1121.
- 114 Luton JP, Cerdas S, Billaud L, Thomas G, Guillaume B, Bertagna X *et al.* Clinical features of adrenocortical carcinoma, prognostic factors, and the effect of mitotane therapy. *New England Journal of Medicine* 1990 **322** 1195–1201.
- 115 Icard P, Goudet P, Charpenay C, Andreassian B, Carnaille B, Chapuis Y *et al.* Adrenocortical carcinomas: surgical trends and results of a 253-patient series from the French Association of Endocrine Surgeon Study Group. *World Journal of Surgery* 2001 **25** 891–897.
- 116 Barzon L, Scaroni C, Sonino N, Fallo F, Paoletta A & Boscaro M. Risk factors and long-term follow-up of adrenal incidentalomas. *Journal of Clinical Endocrinology and Metabolism* 1999 **84** 520–526.
- 117 Fernandez-Real JM, Richart Engel W, Simò R, Salinas I & Webb SM. Study of glucose tolerance in consecutive patients harbouring incidental adrenal tumours. *Clinical Endocrinology* 1998 **49** 53–61.
- 118 Terzolo M, Pia A, Ali A, Osella G, Reimondo G, Bovio S *et al.* Adrenal incidentaloma: a new cause of the metabolic syndrome? *Journal of Clinical Endocrinology and Metabolism* 2002 **87** 998–1003.
- 119 Tauchmanová L, Rossi R, Nuzzo V, del Puente A, Esposito-del Puente A, Pizzi C *et al.* Bone loss determined by quantitative ultrasonometry correlates inversely with disease activity in patients with endogenous glucocorticoid excess due to adrenal mass. *European Journal of Endocrinology* 2001 **145** 241–247.
- 120 Sartorio A, Conti A, Ferrero S, Giambona S, Re T, Passini E *et al.* Evaluation of markers of bone and collagen turnover in patients with active and preclinical Cushing's syndrome and in patients with adrenal incidentaloma. *European Journal of Endocrinology* 1998 **138** 146–152.
- 121 Chiodini I, Torlontano M, Carnevale V, Guglielmi G, Cammisà M, Trischitta V *et al.* Bone loss rate in adrenal incidentalomas: a longitudinal study. *Journal of Clinical Endocrinology and Metabolism* 2001 **86** 5337–5341.
- 122 Chiodini I, Tauchmanova L, Torlontano M, Battista C, Guglielmi G, Cammisà M *et al.* Bone involvement in eugonadal male patients with adrenal incidentaloma and subclinical hypercortisolism. *Journal of Clinical Endocrinology and Metabolism* 2002 **87** 4869–4871.
- 123 Garrapa GM, Pantanetti P, Arnaldi G, Mantero F & Faloia E. Body composition and metabolic features in women with adrenal incidentaloma or Cushing's syndrome. *Journal of Clinical Endocrinology and Metabolism* 2001 **86** 5301–5306.
- 124 Tsagarakis S, Kokkoris P, Roboti C, Malagari C, Kaskarelis J, Vlassopoulou V *et al.* The low-dose dexamethasone suppression test in patients with adrenal incidentalomas: comparisons with clinically euadrenal subjects and patients with Cushing's syndrome. *Clinical Endocrinology* 1998 **48** 627–633.
- 125 Reincke M, Fasnacht M, Vath S, Mora P & Allolio B. Adrenal incidentalomas: a manifestation of the metabolic syndrome? *Endocrine Research* 1996 **22** 757–761.
- 126 Tauchmanova L, Rossi R, Biondi B, Pulcrano M, Nuzzo V, Palmieri EA *et al.* Patients with subclinical Cushing's syndrome due to adrenal adenoma have increased cardiovascular risk. *Journal of Clinical Endocrinology and Metabolism* 2002 **87** 4872–4878.
- 127 Gross MD, Shapiro B, Francis IR, Glazer GM, Bree RL, Arcomano MA *et al.* Scintigraphic evaluation of clinically silent adrenal masses. *Journal of Nuclear Medicine* 1994 **35** 1145–1152.

Received 14 May 2003

Accepted 27 June 2003