
JOURNAL
OF
NEUROSURGICAL
SCIENCES

OFFICIAL JOURNAL OF THE ITALIAN SOCIETY FOR NEUROSURGERY

VOLUME 48 • NUMBER 3 • SEPTEMBER 2004



PUBLISHED BY MINERVA MEDICA

Reconstruction of a large post-traumatic cranial defect with a customized titanium plaque

R. MOTTARAN¹, L. GUARDA-NARDINI², S. FUSETTI², G. FERRONETO², G. SALAR¹

The treatment of serious cranial defects has always been a fascinating and controversial issue for craniofacial surgeons and in the last years many solutions have been proposed. One of the most effective method is a personalized titanium plaque prepared by processing anatomical data obtained with a CAT of the patient. A case of wide cranial defect on the left fronto-parietal region in a 56-year-old man treated with a personalized titanium plaque obtained by processing the data of a spiral CAT of the skull is described. No complications were observed in the postoperative course and follow-up after 6 months showed that the patient was in good general condition.

KEY WORDS: Cranial plastic - Skull defects - Titanium - Cranial plaque.

The repair of large and complex skull defects has always been a particularly demanding task for craniofacial surgeons. In fact in this procedure not only the repair of the defect should be considered but also the choice of materials easy to be handled and fairly biocompatible has to be taken into account to obtain good functional and esthetic results.

The possibility of preparing a personalized titanium plaque by processing anatomical data obtained from a CAT of the patient is one of the most efficient methods for correcting large defects often with irregular borders of the skull and craniofacial structures following a serious trauma.

¹Department of Neurological Sciences-Neurosurgery General Hospital, University of Padua, Padua, Italy
²Institute of Maxillofacial Surgery General Hospital, University of Padua, Padua, Italy

Case report

A 56-year-old man with a wide cranial defect on the left fronto-parietal zone was treated with a titanium plaque performed through CAD/CAM technology.

In July 2000 a very serious trauma occurred to the patient with a plurifragmented breaking through the skull which was treated by an emergency craniotomy for evacuating a massive residual fronto-temporal hematoma.

The small size of the bone fragments distributed on the brain surface, their exposure and hence the potential risk of infection and brain edema hindered the performance of an immediate cranial plasty. Six months after the trauma the patient had recovered and felt well, and after a period of neuromotor rehabilitation was back at work as a contractor. A clear depression in the fronto-parieto-temporal region with involvement of the frontal cheekbone process was however left with serious esthetic-psychological implications and a high risk of a further potentially brain damaging direct trauma on the zone.

Prior to the reconstruction intervention the patient underwent brain MR with and without contrast to exclude residual cerebral pathologies of surgical interest. The MR only showed the ischemic consequences of the intracerebral hematoma in the frontal region. Also the trophism of the scalp over the bone defect, together with the status of the left superficial temporal artery, were evaluated by Doppler echography.

A spiral CAT of the skull was performed and its data were computer processed and E-mailed to Cranio Construct, Bochum-Germany, the firm which built a stereolithographic resin model and from it a titanium plaque exactly fitting the anatomic form of the skull defect. The plaque positioning intervention

Address reprint requests to: Dr. R. Mottaran, Istituto di Neurochirurgia, Università degli Studi, Azienda Ospedaliera di Padova, Via Giustiniani 1, 35100 Padova. E-mail: ruggermottaran@tiscali.it

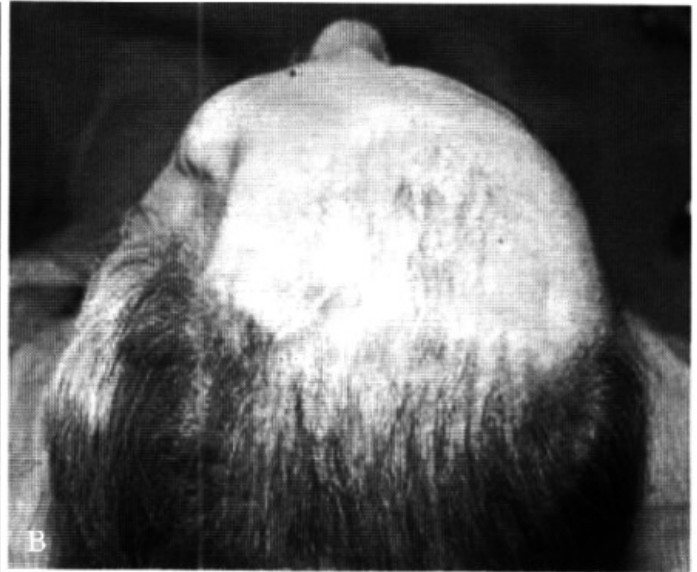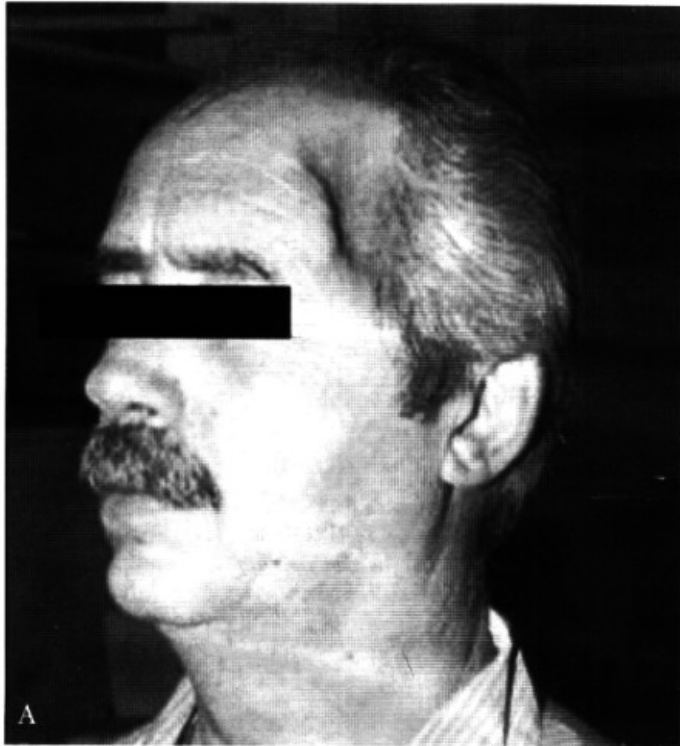


Figure 1A, B.—The patient with a large cranial defect in the temporo-parietal region.

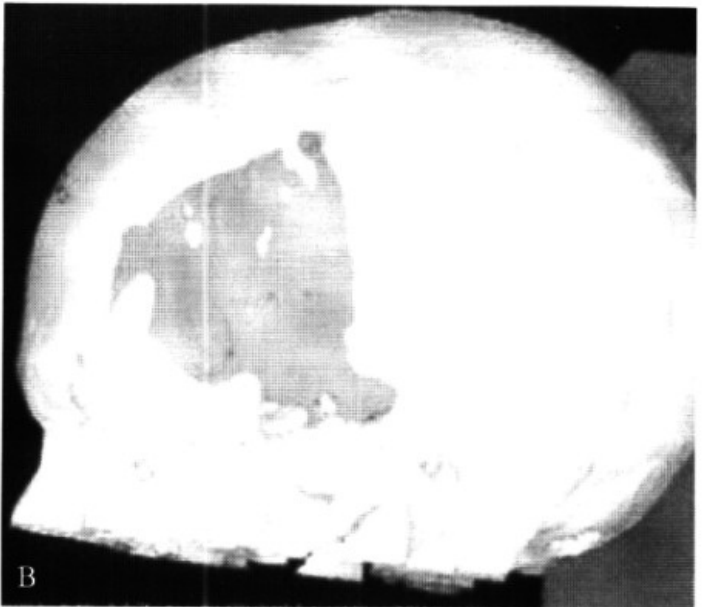
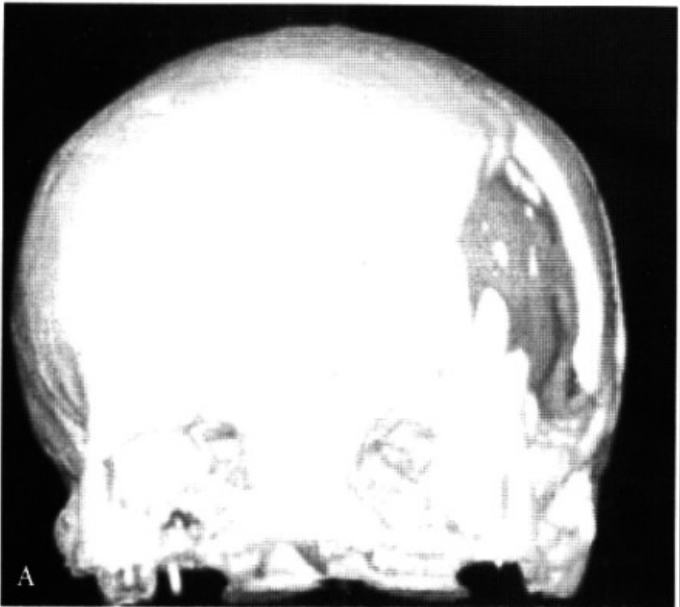


Figure 2A, B.—3D-CT used as template to prepare the titanium plate.

involved the re-opening of the previous surgical wound in the left fronto-temporal-parietal region, an epidural lysis with unbridling of the dura adhered through large fibrous shoots from the temporal muscle to the arachnoid. After an accurate hemo-

stasis a dura plasty was performed and the dura was suspended to the calvaria in several points. Finally, after double-saddling the bone margins around the minus through a delicate periosteal ungluing, the titanium plaque was positioned by anchoring

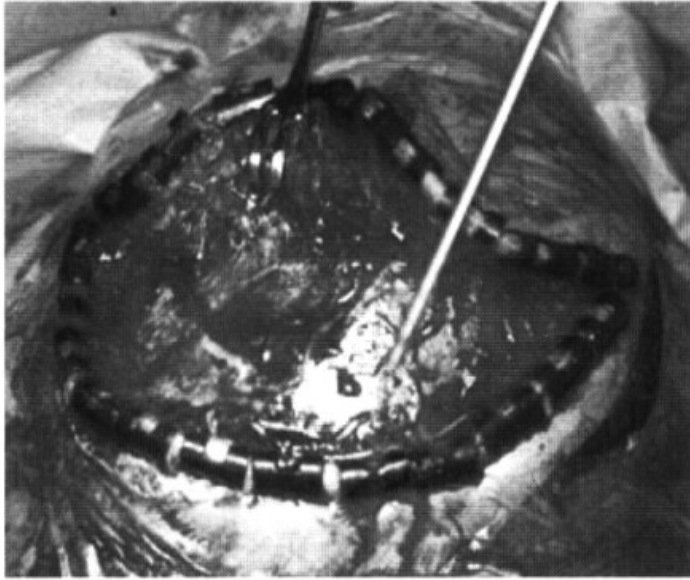


Figure 3.—Epidurolisis.

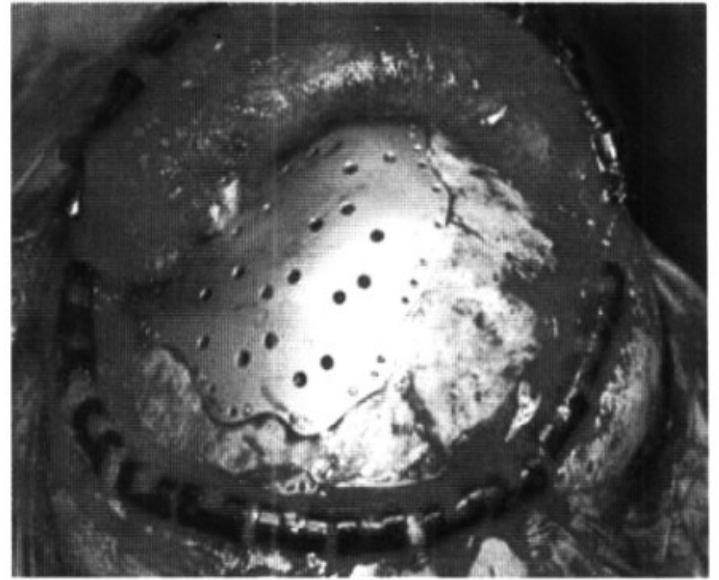


Figure 4.—The titanium plate positioned to cover the defect.

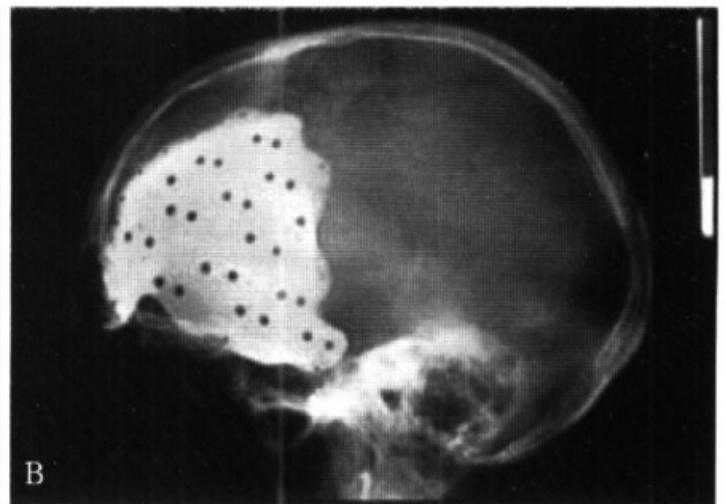
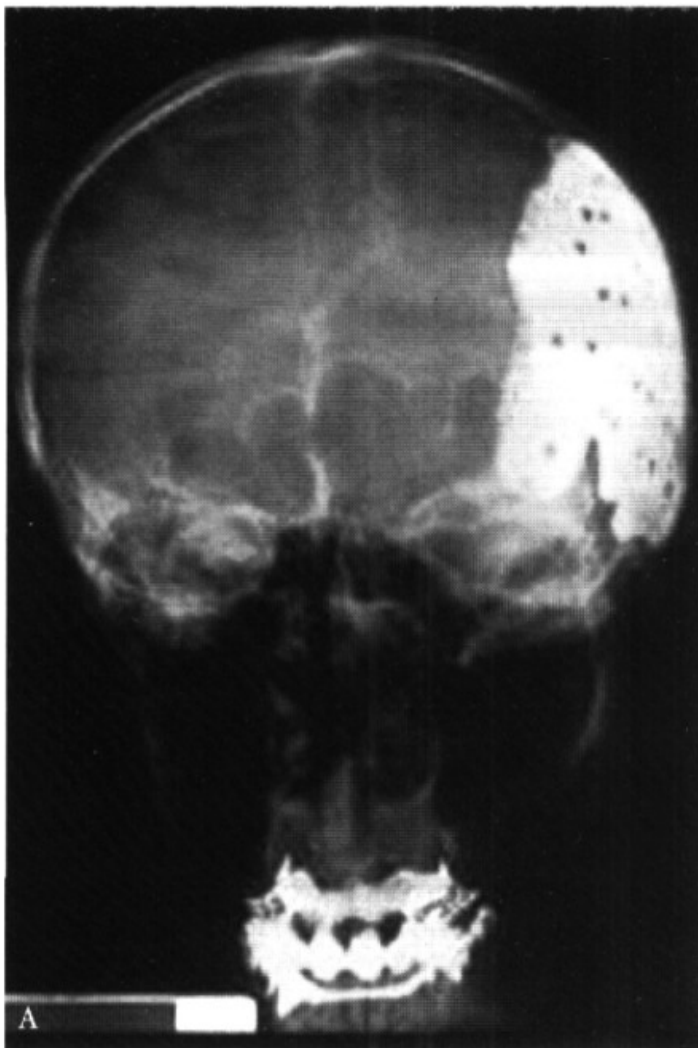

Figure 5A, B.—Post-op rx.

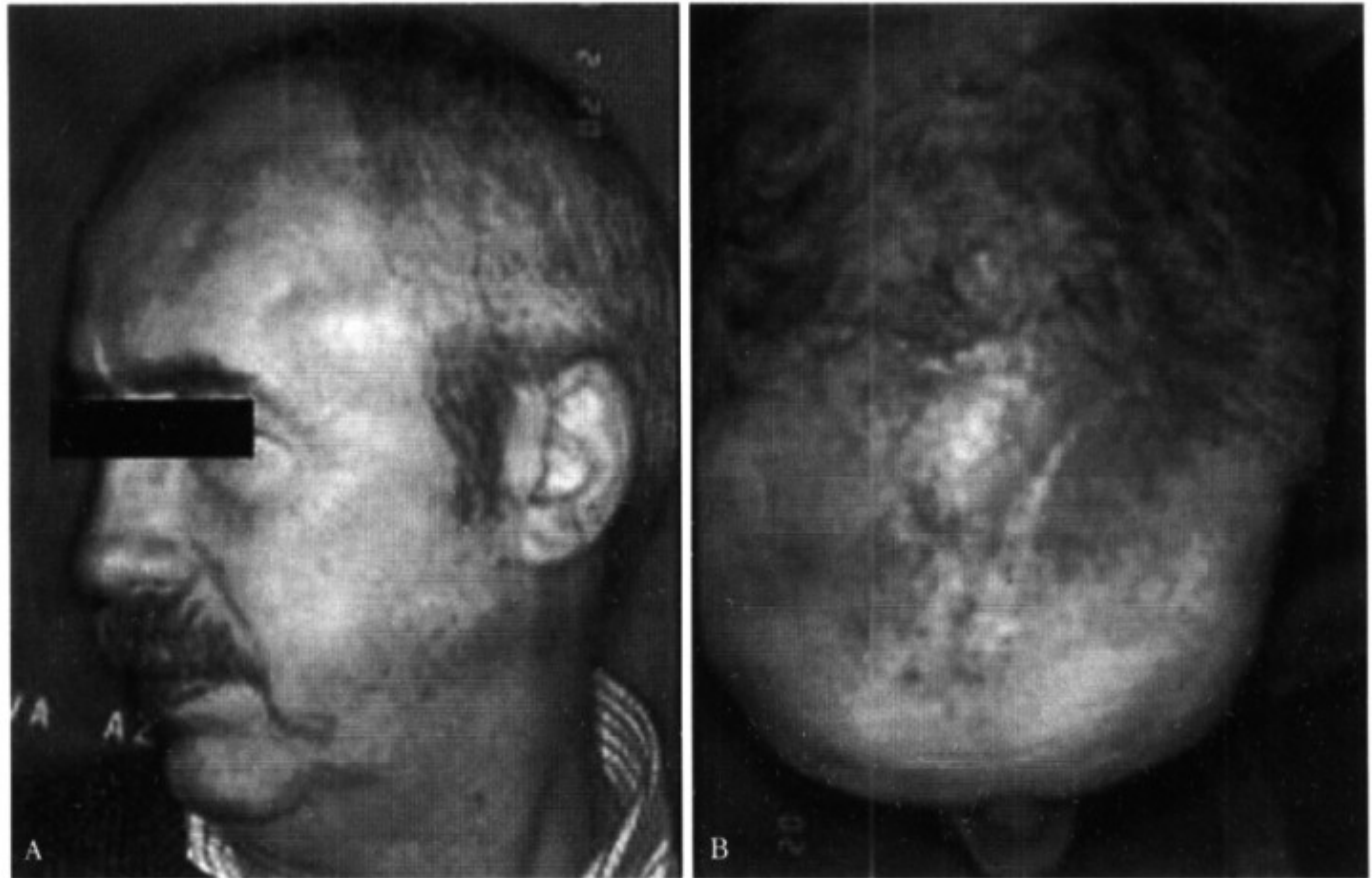


Figure 6A, B.—The patient 40 days after surgery.

it to the surrounding cranial edges with 9 microscrews in holes made on the edges. No complications were observed in the postoperative course and the patient was discharged on the 2nd day. Postoperative CAT revealed a good positioning of the plaque with no fluid accumulation beneath it. After 6 months the patient was in good general conditions and both objective and subjective results were fine with recovered integrity and symmetry of the cranial vault (Figures 1-6).

Discussion

The treatment of important cranial defects has always been a fascinating and controversial issue for the craniofacial surgeon. In the reconstruction of missing basic portions of the skull many parameters should in fact be considered, *e.g.* the curvilinear shape of the part to be reconstructed, the need to use a rigid, shock-resistant and biocompatible material, together with its reduced cost. In the last years various solutions have been proposed. Paul Tessier, the founder of cra-

niofacial surgery suggested autologous calvaria grafts which might however undergo reabsorption without often reaching the required precision for a good esthetic result.^{1, 2} In the first 90's Wellisz *et al.*,³ to cover large cranial defects, introduced the use of porous polyethylene (Medpor, POREX), a material with good organotrophic characteristics allowing a cell growth in its interior and was devoid of cytotoxic and systemic effects. Medpor is also easily molded⁴ but due to its elastic behavior it is not always suitable when the correction is too large and hollow. Other materials used for cranial reconstruction have been hydroxyapatite cement,⁵ *i.e.* calcium phosphate, the known component of the human bone which may be positioned and molded upon the osseous defect. In some cases hydroxyapatite can however flake off with consequent diffusion in the surrounding tissue.⁶ Polymethylacrylate is a resin widely used to correct cranial defects⁷ and can be prepared in the course of the operative session to be adapted to the bone defect dur-

ing the initial polymerisation phase. Its inconveniences are mostly due to the exothermic phase which may be a potential cause of damage to the dura lying below and to the resin shrinking. Moreover, the material should be manually molded with high infection risk⁸ and a frequently approximate three-dimensional result. Finally, to anchor the resin to the bone lying below, a rigid fixation system must be used for a valid holding power.

An important new in this field was the introduction of the CAD/CAM techniques and the CAT data for building up stereolithographic resin models. From the latter, laser-molded grafts can be built which can be inserted with millimetre precision to cover the bone defect.^{9, 10} Such grafts are made of titanium and have the advantage of providing a foreseeable esthetic result, of being resistant, biocompatible and capable of highly reducing the operative time, while saddled edges allow their anchoring to the skull by microscrews. These grafts have, however, the risk of infection in which case they should be immediately removed.¹¹ This method has been recently proposed also for hydroxyapatite¹² and porous polyethylene¹³ with good results.

Conclusions

In wide and irregular cranial defects, as in the present case, optimal reconstruction is obtained only with computer-aided procedures for reproducing the missing part. In addition to the excellent result, a preformed plaque allows the halving of the surgical intervention time for manipulation and intraoperative adaptation of the cranial plastic. According to the literature, the material of choice for the prosthesis for adults who do not have further cranial growth is titanium due to its resistance, ductility and biocompatibility. It

should be pointed out that the development of modern technologies of imaging, data processing and transmission, and sophisticated working out of materials allow to obtain products in rapid and precise fashion and to perform interventions in a way unthinkable not long time ago.

References

1. Tessier P. Autogenous bone grafts taken from the calvarium for facial and cranial applications. *Clin Plast Surg* 1982;9:531-8.
2. Kline RM, Wolfe SA. Complications associated with the harvesting of cranial bone grafts. *Plast Reconstr Surg* 1995;95:5-20.
3. Wellisz T, Dougherty W, Gross J. Craniofacial applications for the Medpor porous polyethylene flexblock implant. *J Craniofac Surg* 1992;3:101-7.
4. Qian Y, Fan Z, Yang Q. Application of Medpor surgical implant in the craniofacial reconstruction. *Zhongguo Xiu Fu Chong Jian Wai Ke Za Zhi* 1998;12:71-3.
5. Reddi SP, Stevens MR, Kline SN, Villanueva P. Hydroxyapatite cement in craniofacial trauma surgery: indications and early experience. *J Craniofac Surg* 1999;5:7-12.
6. Maniker A, Cantrell S, Vaicys C. Failure of hydroxyapatite cement to set in repair of a cranial defect: case report. *Neurosurgery* 1998;43:953-4.
7. Luparello D, Bruschi S, Verna G, Bogetti P, Datta G, Fraccalvieri M *et al.* Cranioplasty with polymethylmethacrylate: clinico-statistical considerations. *Minerva Chir* 1998;53:575-9.
8. Eufinger H, Wehmoller M, Scholz M, Harders A, Machtens E. Reconstruction of an extreme frontal and frontobasal defect by microvascular tissue transfer and prefabricated titanium implant. *Plast Reconstr Surg* 1999;104:198-203.
9. Eufinger H, Wehmoller M. Individual prefabricated titanium implants in reconstructive craniofacial surgery: clinical and technical aspects of the first 22 cases. *Plast Reconstr Surg* 1998;102:300-8.
10. Eufinger H, Saylor B. Computer-assisted prefabrication of individual craniofacial implants. *AORN J* 2001;74:648-54.
11. Kamyszek T, Weihe S, Scholz M, Wehmoller M, Eufinger H. Management of craniofacial bone defects with individually prefabricated titanium implants. Follow-up and evaluation on 78 patients with 78 titanium implants 1994-1998. *Mund Kiefer Gesichtschir* 2001;5:233-8.
12. Ono I, Tateshita T, Satou M, Sasaki T, Matsumoto M, Kodama N. Treatment of large complex cranial bone defects by using hydroxyapatite ceramic implants. *Plast Reconstr Surg* 1999;104:339-49.
13. Eppley BL, Kilgo M, Coleman JJ. Cranial reconstruction with computer-generated hard-tissue replacement patient-matched implants: indications, surgical technique and long-term follow-up. *Plast Reconstr Surg* 2002;109:864-71.