

## A Systematic Review and Meta-Analysis of Outcomes and Adverse Events for Juxtafacet Cysts Treatment

Enrico Giordan, Paolo Gallinaro, Altin Stafa, Giuseppe Canova, Roberto Zanata, Elisabetta Marton and Jacopo Del Verme

*Int J Spine Surg* 2022, 16 (1) 124-138

doi: <https://doi.org/10.14444/8181>

<https://www.ijssurgery.com/content/16/1/124>

This information is current as of December 30, 2024.

---

**Email Alerts** Receive free email-alerts when new articles cite this article. Sign up at:  
<http://ijssurgery.com/alerts>

# A Systematic Review and Meta-Analysis of Outcomes and Adverse Events for Juxtafacet Cysts Treatment

ENRICO GIORDAN, MD<sup>1</sup>; PAOLO GALLINARO, MD<sup>1</sup>; ALTIN STAFA, MD<sup>2</sup>; GIUSEPPE CANOVA, MD<sup>1</sup>; ROBERTO ZANATA, MD<sup>1</sup>; ELISABETTA MARTON, MD<sup>1,3</sup>; AND JACOPO DEL VERME, MD<sup>1</sup>

<sup>1</sup>Department of Neurosurgery, Aulss 2 Marca Trevigiana, Treviso, Veneto, Italy; <sup>2</sup>Department of Neuroradiology, Aulss2 Marca Trevigiana, Treviso, Italy; <sup>3</sup>Department of Neuroscience, University of Padova, Padova, Italy

## ABSTRACT

**Background:** Different procedures have been used for the treatment of lumbar juxtafacet cysts (JFCs). Recently, full-endoscopic cyst excision has been suggested as a reasonable alternative. We performed a meta-analysis to assess the overall rates of favorable outcomes and adverse events for each available treatment and determine the outcome and complication rates concerning spine stability.

**Methods:** Multiple databases were searched for English-language studies involving adult patients with lumbar JFCs who had been followed for more than 6 months. Outcomes included the proportion of patients with a satisfactory outcome. Adverse events included recurrence and revision rates as well as intraoperative complications. We further stratified the analysis based on the spine's condition (degenerative listhesis vs without degenerative listhesis).

**Results:** A total of 43 studies, including 2226 patients, were identified. Over 80% of patients experienced satisfactory improvement after surgical excision but only 66.2% after percutaneous cyst rupture and aspiration. Overall, recurrence and revision rates were almost double in patients with preoperative degenerative listhesis at the cyst level, especially in the minimally invasive group (2.1% vs 31.3% and 6.8% vs 13.1%, respectively). The rate of full-endoscopic satisfactory outcomes was approximately 90%, with low rates of adverse events (<2%).

**Conclusion:** We analyzed the outcome and adverse event rates for each kind of available treatment for JFC. Full endoscopy has outcomes and rates of adverse events that overlap with open and minimally invasive approaches.

**Level of Evidence:** 2A.

Endoscopic Minimally Invasive Surgery

Keywords: juxtafacet cyst, lumbar, synovial cyst, endoscopic, spine, minimally invasive, percutaneous, cyst rupture

## INTRODUCTION

Lumbar juxtafacet cysts (JFCs) are common in patients with degenerative spine disease and are responsible for radicular pain and neurological symptoms. The development of JFCs is linked to degenerative spondylosis, segmental instability, and trauma.<sup>1-3</sup> The reported incidence of JFCs among patients undergoing lumbar surgery ranges from 0.1% to 0.8%, and degenerative listhesis is estimated to be present in 38% to 75% of these patients.<sup>4,5</sup>

JFC treatment's mainstay is laminectomy/hemilaminectomy and cyst excision, sometimes coupled with total facetectomy and fusion.<sup>6</sup> Conservative management or percutaneous cyst rupture and aspiration,<sup>7</sup> typically used in the elderly or those unwilling or unsuited for surgical treatment,<sup>8</sup> is mostly temporarily effective and has high recurrence rates.<sup>9-12</sup>

Recently, minimally invasive techniques have been used to treat such patients, expanding spinal surgeons' therapeutic choices.<sup>13</sup> The full-endoscopic approach has also gained importance in the surgeon's armamentarium

and, more recently, has been used for degenerative disease treatment.<sup>14</sup>

Several studies have tried to review and compare the outcomes and adverse events of different surgical techniques for JFCs.<sup>15-17</sup> However, because some of these studies did not report results per the surgical procedure, they lacked detailed information about their possible outcomes. This is especially true regarding patient selection based on suspected spine instability at the cyst level. Therefore, we restricted our literature analysis to studies with detailed information about surgical management and spine stability to compare actual surgical options. For the first time in literature, this resulted in an extensive stratified analysis of outcomes and adverse events for each type of procedure: open, minimally invasive, percutaneous, and full-endoscopic management of lumbar JFCs.

## METHODS

A comprehensive search of several databases (ie, PubMed, Epub Ahead of Print, Ovid MEDLINE

In-Process & Other Non-Indexed Citations, Ovid MEDLINE, Ovid EMBASE, Ovid Cochrane Central Register of Controlled Trials, Ovid Cochrane Database of Systematic Reviews, and Scopus) was conducted with the help of an expert medical reference librarian. The search terms were “juxtafacet cyst,” “synovial,” “ganglion,” “lumbar,” “lumbar cysts,” “cyst,” and “spinal cyst,” which were used alone and in combination. Controlled vocabulary supplemented with the keywords was used to search for JFC formation in patients diagnosed with degenerative spinal diseases.

Inclusion criteria were as follows:

1. description of JFCs in both longitudinal and retrospective series that discussed the following:
  - synovial cysts in continuity with the capsule of the facet joints
  - ganglion cyst
2.  $\geq 5$  patients
3. mean or median follow-up  $> 6$  months
4. published in English between January 2000 and April 2020
5. consecutive series of patients treated with the following:
  - percutaneous techniques (cyst rupture and aspiration)
  - open surgery (interlaminar approach or laminectomy/hemilaminectomy and cyst excision)
  - minimally invasive approaches (ipsilateral or contralateral microsurgical tubular approaches)
  - full-endoscopic surgery (interlaminar and/or transforaminal full-endoscopic access)
6. intraoperative or histological confirmation of JFCs
7. preoperative imaging adequate to assess spinal stability (either spine CT or MRI and dynamic x-ray)
8. patients who did not undergo instrumented fusion at the cyst level
9. patients with or without preoperative degenerative listhesis at cyst level

Studies dealing with patients with higher than grade I preoperative degenerative listhesis based on the Meyerding classification,<sup>18</sup> with vertebral body slippage confirmed through dynamic x-rays or in case of isthmic spondylolisthesis, were excluded. Among these patients, the spine was considered severely unstable and suitable only for fusion procedures, thus

perceiving cyst formation as an epiphenomenon of severe spinal instability. Studies with patients who underwent prior instrumented fusion at the cyst level were excluded.

### Data Abstraction

We categorized the studies into 4 groups based on surgical technique, including patients who underwent either surgical or microsurgical cyst excision in the open surgery group. We included studies on patients who underwent microsurgical cyst excision with tubular retraction system in the minimally invasive group. The full-endoscopic group included those studies with patients who underwent endoscopic interlaminar or transforaminal approaches. In the percutaneous group, we included studies only on patients who had undergone computed tomography (CT or fluoroscopically guided JFC rupture and aspiration).

For each study, we extracted the following data: patient's age (years), sex, JFC level, operative time (minutes), hospitalization time (days), follow-up (months), overall outcome, description of the procedure, intraoperative adverse events, whether the adverse events (both medical and surgical) manifested after more than 30 days, same-level JFC recurrence, the proportion of patients with preoperative spinal instability, method of assessing spinal instability (ie, spine CT, dynamic x-rays, or spine magnetic resonance imaging [MRI]), time from lumbar cyst treatment to the development of spinal instability at the affected level (months), and the proportion of patients requiring revision surgery for recurrence or developing instability at the treated level. We noted the surgical approach utilized for each surgical procedure (open vs minimally invasive vs full endoscopic vs percutaneous). We excluded patients with prior fusion surgery at the level of the JFC, but we collected the percentage of patients undergoing fusion surgery either at the surgery time or at developing instability.

The outcomes were defined as "satisfactory" based on MacNab or modified MacNab criteria,<sup>19</sup> and the values were collected at the last follow-up visit or at least 6 months after the intervention. Only excellent and good scores were considered satisfactory. In some studies, we extracted the degree of postoperative satisfaction ("excellent" and "good") from scores or scales similar to or attributable to MacNab's criteria.

We included preoperative degenerative listhesis when the listhesis at the cyst level described in the pooled studies was within: (1) Meyerding grade 1

and (2) without vertebral body slippage on dynamic lumbar x-ray.

Every other intervention at the previously treated level or additional arthrodesis to overcome a developing spinal instability was considered as “revision surgery.” In the percutaneous group, revisions were divided into 2 subgroups: those needing an additional percutaneous cyst puncture and those requiring surgical cyst excision for symptom control. The following intraoperative adverse events were considered: nerve root damage, dural tear, seroma, and epidural hematoma.

When possible, we separately extracted the subpopulations of patients with confirmed preoperative degenerative listhesis from the investigated segment, calculating outcomes and adverse events for each population (no signs of preoperative degenerative listhesis or instability vs preoperative degenerative listhesis). We also abstracted the mean interval between the first surgery and the development of a more severe degree of spinal instability (ie, Meyerding grade >I or significant mobility in dynamic x-rays).

### Study Evaluation

For each study, we evaluated the design, population, and imaging used in the follow-up. We also evaluated the risk of bias with a modified New Castle-Ottawa Quality Assessment Scale.<sup>20</sup> The risk of bias was assessed based on the following questions: Did the study include all patients or consecutive patients with adequate radiological follow-up (spine MRI, CT, and dynamic x-rays)? Was the follow-up enough to ascertain the development of spinal instability or cysts recurrence (>24 months)? Was histological confirmation reported? (the histological confirmation is a measure of the original study’s methodological quality; also, JFCs may have different presentation stages [from fluid to sclerotic content], and histology may help to confirm JFCs excision). The studies were divided into “high” (≥6 points), “moderate” (4 or 5 points), and “low”(≤3 points) risk of bias categories, and 2 tiers were separately compared and analyzed to see whether there was any statistically significant difference between each (Table 1). Low risk of bias studies was defined as those with a predefined study protocol (randomized or prospective) and adequate imaging follow-up (spine MRI, CT, and dynamic x-rays; follow-up >24 months).

### Statistical Analysis

Descriptive statistics were reported as a mean/range for continuous variables and proportion/percentage for categorical variables. For each technique, the proportion of patients considered improved and with adverse events was estimated. Estimates from each cohort were pooled in a random-effects meta-analysis model, as described by DerSimonian and Laird. Anticipating heterogeneity between studies, we chose this model a priori because it incorporates within- and between-study variance. In addition, because in some studies, the rate of outcomes was close to 0 or 1, the Freeman-Tukey double-arcsine transformation was utilized. We then made pairwise comparisons between groups for the respective outcomes. All statistical analyses were performed using Stata version 13.0 (StataCorp LLC, College Station, TX).

## RESULTS

### Literature Search and Study Characteristics

The initial literature search yielded 638 articles. Upon review of abstracts and titles, 540 were excluded. In full-text review, 53 more articles were excluded because they did not match the eligibility criteria for this meta-analysis, mainly including the length of follow-up, an adequate definition of lumbar JFCs, or surgical outcomes definition (Figure 1).

Forty-three studies, with 2226 patients, describing outcomes and adverse events of JFC treatment were included. Eighteen of these studies report outcomes after open surgery (1112 patients), 7 exclusively concern minimally invasive treatment (276 patients), 8 used full-endoscopic treatment (233 patients), and 7 used percutaneous rupture and aspiration procedures (477 patients). Three studies compare different kinds of surgical treatment: 1 study compares outcomes between full-endoscopic and open surgery (60 patients) and 1 study compares outcomes between percutaneous techniques and open surgery (45 patients). In another study reporting individual patient data, we were able to extract and separately analyze the outcomes of open vs minimally invasive approaches (23 patients).

Thirty-four studies were retrospective and 9 prospective. Of the 43 studies included in our meta-analysis, 5 had a high risk of bias, 25 had a moderate risk, and 13 had a low risk of bias.

A study-selection flow diagram compiled following the PRISMA guidelines<sup>21</sup> is provided in Figure 1. A summary of the included studies is provided in

**Table 1.** Summary of the characteristics of the included studies.

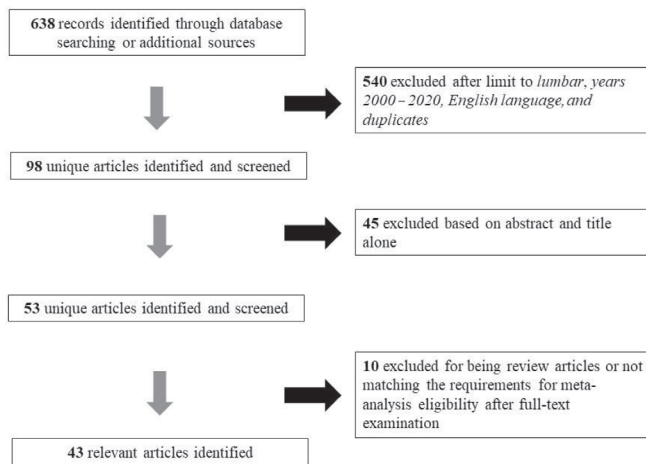
Authors	Year	Journal	Design	Recruitment Interval	N	Inclusion /Exclusion Criteria	Outcome Measurement	Cohort Characteristics
Hellinger S et al <sup>22</sup>	2020	<i>Journal of Spine Surgery</i>	P	2008–2014	48	1. Radiculopathy unresponsive to >12 wk of conservative care 2. MRI scans showing foraminal or lateral recess stenosis 3. A single-level unilateral lumbar JFC 4. Cysts localized in the paramedian, paraforaminal, or intraforaminal location 5. Invalditing radicular pain for >6 wk 6. Adequate imaging (MRI) 7. Failed percutaneous or conservative treatment 8. Lumbar JFC resistant to conservative treatment	VAS scores MacNab scores NPRS scores, MacNab scores	Full endoscopy; transforaminal or interlaminar (local anesthesia and monitored sedation) Full endoscopy; transforaminal or interlaminar (local anesthesia and monitored sedation)
Taccioni L et al <sup>13</sup>	2020	<i>World Neurosurgery</i>	P	2017–2019	35	1. Radicular leg pain refractory to conservative management methods 2. No concomitant segment instability or suspected infectious disease 3. Grade I listhesis 4. Detailed neurologic examinations focused on leg and back pain 5. Histopathologic report of the specimen 6. No previous lumbar spine surgery 7. A preoperative MRI scan 8. Patients with lumbar JFCs 9. Not specified exclusion criteria	ODI scores, VAS scores SF-12 values NPRS scores, MacNab scores	Full endoscopy; transforaminal (local anesthesia and monitored sedation) Microsurgical vs full-endoscopic approach Endoscopy; contralateral bipolar approach <sup>a</sup> (epidural/general anesthesia) 46 HL Full endoscopy; interlaminar (general anesthesia)
Kyung-Hoon K et al <sup>14</sup>	2019	<i>Pain Physician</i>	R	2014–2016	40	1. Lumbar JFCs with or without concomitant grade I degenerative spondylolisthesis 2. Patients without instability on standing flexion-extension radiographs 3. >6 wk of conservative management 4. Symptomatic JFCs	NPRS scores, MacNab scores	38 L, 102 HL Mini-invasive surgery; ipsilateral approach
Hahn P et al <sup>23</sup>	2018	<i>Orthopedic Proceedings</i>	P	2016	60	1. Patients with moderate to severe lumbar radiculopathy 2. Confirmed by CT or MRI 3. No lumbar canal stenosis, disc herniation, tumor, or infection 4. No preoperative spondylolisthesis and mechanical back pain 5. No instability on flexion/extension films	NPRS scores, MacNab scores	Mini-invasive surgery; ipsilateral approach Fluoroscopic-guided rupture (local anesthesia) 24 hemilaminoplasty
Heo DH et al <sup>24</sup>	2018	<i>World Neurosurgery</i>	R	2000–2015	10	1. Lumbago and refractory radiculopathy originated from JFCs 2. Confirmed by CT or MRI 3. No lumbar canal stenosis, disc herniation, tumor, or infection 4. No preoperative spondylolisthesis and mechanical back pain 5. No instability on flexion/extension films	JOA scores, VAS scores	Mini-invasive surgery; ipsilateral approach Fluoroscopic-guided rupture (local anesthesia) 24 hemilaminoplasty
Siu CK et al <sup>25</sup>	2018	<i>Journal of Clinical Neuroscience</i>	R	2000–2015	46	1. Lumbar JFCs with or without concomitant grade I degenerative spondylolisthesis 2. Patients without instability on standing flexion-extension radiographs 3. >6 wk of conservative management 4. Symptomatic JFCs	ODI scores, VAS scores, MacNab scores	Mini-invasive surgery; ipsilateral approach Fluoroscopic-guided rupture (local anesthesia) 24 hemilaminoplasty
Oertel J M et al <sup>26</sup>	2017	<i>World Neurosurgery</i>	P	2014–2016	11	1. Lumbar JFCs with or without concomitant grade I degenerative spondylolisthesis 2. Patients without instability on standing flexion-extension radiographs 3. >6 wk of conservative management 4. Symptomatic JFCs	NPRS scores, MacNab scores	Mini-invasive surgery; ipsilateral approach Fluoroscopic-guided rupture (local anesthesia) 24 hemilaminoplasty
Bruder M et al <sup>27</sup>	2017	<i>Journal of Neurosurgery: Spine</i>	R	1997–2004	140	1. Patients with lumbar JFCs 2. Not specified exclusion criteria	NPRS scores, MacNab scores	Mini-invasive surgery; ipsilateral approach Fluoroscopic-guided rupture (local anesthesia) 24 hemilaminoplasty
Denis DR et al <sup>2</sup>	2016	<i>International Journal of Spine Surgery</i>	R	2003–2014	53	1. Lumbar JFCs with or without concomitant grade I degenerative spondylolisthesis 2. Patients without instability on standing flexion-extension radiographs 3. >6 wk of conservative management 4. Symptomatic JFCs	MacNab scores	Mini-invasive surgery; ipsilateral approach Fluoroscopic-guided rupture (local anesthesia) 24 hemilaminoplasty
Birch BD et al <sup>28</sup>	2016	<i>World Neurosurgery</i>	R	1999–2015	40	1. Patients with moderate to severe lumbar radiculopathy 2. Confirmed by CT or MRI 3. No lumbar canal stenosis, disc herniation, tumor, or infection 4. No preoperative spondylolisthesis and mechanical back pain 5. No instability on flexion/extension films	MacNab scores	Mini-invasive surgery; ipsilateral approach Fluoroscopic-guided rupture (local anesthesia) 24 hemilaminoplasty
Eshraghi Y et al <sup>7</sup>	2016	<i>Pain Physician</i>	R	2006–2013	30	1. Lumbar JFCs with or without concomitant grade I degenerative spondylolisthesis 2. Patients without instability on standing flexion-extension radiographs 3. >6 wk of conservative management 4. Symptomatic JFCs	MacNab scores	Mini-invasive surgery; ipsilateral approach Fluoroscopic-guided rupture (local anesthesia) 24 hemilaminoplasty
Zhenbo Z et al <sup>29</sup>	2016	<i>European Spine Journal</i>	R	2000–2012	24	1. Lumbar JFCs with or without concomitant grade I degenerative spondylolisthesis 2. Patients without instability on standing flexion-extension radiographs 3. >6 wk of conservative management 4. Symptomatic JFCs	NPRS scores, VAS scores	Mini-invasive surgery; ipsilateral approach Fluoroscopic-guided rupture (local anesthesia) 24 hemilaminoplasty
Alimi M et al <sup>30</sup>	2015	<i>Journal of Neurosurgery: Spine</i>	R	2004–2011	110	1. Lumbar JFCs with or without concomitant grade I degenerative spondylolisthesis 2. Patients without instability on standing flexion-extension radiographs 3. >6 wk of conservative management 4. Symptomatic JFCs	ODI scores, VAS scores, MacNab scores	Mini-invasive surgery; ipsilateral approach Fluoroscopic-guided rupture (local anesthesia) 24 hemilaminoplasty
Sakkarieh HG et al <sup>31</sup>	2015	<i>Journal of Neurosurgery: Spine</i>	R	2010–2014	13	1. Lumbar JFCs with or without concomitant grade I degenerative spondylolisthesis 2. Patients without instability on standing flexion-extension radiographs 3. >6 wk of conservative management 4. Symptomatic JFCs	VAS scores, MacNab scores	Mini-invasive surgery; ipsilateral approach Fluoroscopic-guided rupture (local anesthesia) 24 hemilaminoplasty
Knaflo S et al <sup>32</sup>	2015	<i>Journal of Spinal Disorder &amp; Techniques</i>	R	2004–2010	23	1. Patients with lumbar JFCs 2. Not specified exclusion criteria	MacNab scores	Mini-invasive surgery; ipsilateral approach Fluoroscopic-guided rupture (local anesthesia) 24 hemilaminoplasty
Komp M et al <sup>33</sup>	2014	<i>Surgical Innovation</i>	P	2009–2010	74	1. No back pain 2. No spondylolisthesis more than Meyerding grade I; 3. No spinal stenosis or disc herniations at higher levels on the same side	VAS scores, German version of the North American Spine Society scale, Oswestry low back pain scale	Mini-invasive surgery; ipsilateral approach Fluoroscopic-guided rupture (local anesthesia) 24 hemilaminoplasty
Ortiz O et al <sup>34</sup>	2013	<i>Journal of NeuroInterventional Surgery</i>	R	2007–2010	20	1. Unilateral lower-extremity radiculopathy with or without lower back pain 2. Not responders to conservative management 3. Lower-extremity radiculopathy corresponding to the JFCs 4. MR imaging <2 mo before initial percutaneous rupture 5. No specified exclusion criteria	NPRS scores	Tandem or coaxial percutaneous CT-guided (local and intravenous anesthesia)
Camboun SC et al <sup>11</sup>	2013	<i>American Journal of Neurology</i>	R	2004–2011	154	1. Lower-extremity radiculopathy corresponding to the JFCs 2. MR imaging <2 mo before initial percutaneous rupture 3. No specified exclusion criteria	NPRS scores	CT-guided cyst aspiration and rupture (local anesthesia and intravenous sedation) 12 HL; 5 L
Ganau M et al <sup>3</sup>	2013	<i>Neurologia Medico-Chirurgica</i>	R	2000–2009	15	1. Unilateral radicular leg pain 2. No history of previous lumbar surgery 3. Failure of appropriate conservative treatment 4. Neither instability nor spondylolisthesis 5. Conservative treatment attempted for at least 3 mo	MacNab scores	Full endoscopy; transforaminal (epidural anesthesia)
Ha SW et al <sup>15</sup>	2012	<i>Journal of Korean Neurological Society</i>	R	2007–2010	8	1. JFCs on MRI (fluid, hemorrhagic, or calcification sign) 2. Imaging findings consistent with the clinical symptoms 3. VAS with a score >6/10 4. No preexistence of spinal instability in preoperative assessment	VAS scores	Full endoscopy; transforaminal (epidural anesthesia)
James A et al <sup>36</sup>	2012	<i>Journal of Spinal Disorders &amp; Techniques</i>	R	2006–2009	16	1. JFCs on MRI (fluid, hemorrhagic, or calcification sign) 2. Imaging findings consistent with the clinical symptoms 3. VAS with a score >6/10 4. No preexistence of spinal instability in preoperative assessment	VAS scores, MacNab scores	Mini-invasive; contralateral approach
Amoretti N et al <sup>11</sup>	2012	<i>European Radiology</i>	R	2006–2010	120	1. JFCs on MRI (fluid, hemorrhagic, or calcification sign) 2. Imaging findings consistent with the clinical symptoms 3. VAS with a score >6/10 4. No preexistence of spinal instability in preoperative assessment	VAS scores, ODI scores	CT-guided cyst aspiration and rupture (local anesthesia and intravenous sedation) 6 L; 9 HL
Landi A et al <sup>37</sup>	2012	<i>Neurosurgical Review</i>	R	1995–2007	15	1. JFCs on MRI (fluid, hemorrhagic, or calcification sign) 2. Imaging findings consistent with the clinical symptoms 3. VAS with a score >6/10 4. No preexistence of spinal instability in preoperative assessment	Reported percent of patients with complete vs partial satisfaction	Microsurgically vs percutaneous cyst rupture
Schulz M et al <sup>16</sup>	2011	<i>Orophade</i>	P	2011	45	1. JFCs on MRI (fluid, hemorrhagic, or calcification sign) 2. Imaging findings consistent with the clinical symptoms 3. VAS with a score >6/10 4. No preexistence of spinal instability in preoperative assessment	Reported percent of patients with complete vs partial satisfaction	Microsurgically vs percutaneous cyst rupture



Table 1. Continued.

Authors	Year	Journal	Design	Recruitment Interval	N	Inclusion/Exclusion Criteria	Outcome Measurement	Cohort Characteristics
El Shazly A et al <sup>38</sup>	2011	<i>Asian Journal of Neurosurgery</i>	R	2003–2008	13	Patients without previous spinal fusion	MacNab scores	13 L
Matsumoto M et al <sup>39</sup>	2010	<i>Minimally Invasive Neurosurgery</i>	P		7	Ineffective conservative treatment	JOA scores	Microendoscopic
Xu R et al <sup>40</sup>	2010	<i>Spine</i>	R	1990–2009	174	1. Patients with lumbar JFCs 2. No specified exclusion criteria	NRS-11 scores, RMDQ scores, satisfaction questionnaire	54 HL; 40 L; 21 FC in situ F; 60 FC and instrumented F Fluoroscopic-guided cyst rupture
Allen TL et al <sup>10</sup>	2009	<i>The Spine Journal</i>	R	2004–2007	40	1. No calcified JFCs 2. No previous cyst aspiration procedure 3. No multifactorial low back pain or symptoms associated with other underlying lumbar pathologies		
Mantha JF et al <sup>9</sup>	2009	<i>The Spine Journal</i>	R	1999–2005	101	1. Patients with lumbar JFCs 2. No specified exclusion criteria	NPRS scores, ODI scores	Fluoroscopic-guided rupture (local anesthesia)
Terao T et al <sup>41</sup>	2007	<i>Neurologia Medico-Chirurgica</i>	R	1998–2006	10	1. Patients with lumbar JFCs 2. No specified exclusion criteria	Scores: excellent/good/ poor	10 L
Weiner BK et al <sup>42</sup>	2007	<i>Journal of Orthopaedic Surgery and Research</i>	R	1984–2001	46	1. patients with lumbar JFCs 2. no specified exclusion criteria	VAS scores, satisfaction questionnaire	46 HL
Sehati N et al <sup>43</sup>	2006	<i>Neurosurgical Focus</i>	R	2003–2005	19	1. >6 wk of nonoperative management 2. No previous surgery at the JFCs level or at adjacent spinal segments	MacNab scores	Mini-invasive surgery: ipsilateral approach
Acharya R et al <sup>1</sup>	2006	<i>Neurology India</i>	R	1993–1982	26	1. Patients with lumbar JFCs 2. No specified exclusion criteria	Reported percent of satisfactory relief	15 L, 9 HL
Metellus P et al <sup>44</sup>	2006	<i>Acta Neurochirurgica</i>	R	1992–1998	77	1. Patients with lumbar JFCs 2. No specified exclusion criteria	Scores: excellent/good/ poor	51 HL + PF + MF; 26 L + F + MF
Demsberger R et al <sup>15</sup>	2006	<i>Journal of Spinal Disorder &amp; Techniques</i>	R	2002–2004	30	1. Patients with lumbar JFCs 2. No specified exclusion criteria	MacNab scores	26M MF; 4 L+MF
Sandhu FA et al <sup>45</sup>	2004	<i>Neurosurgery</i>	R	1999–2003	25	1. Detailed neurological examinations 2. Dynamic radiological studies of the lumbosacral spine 3. Preoperative MRI imaging	MacNab scores	Mini-invasive surgery: ipsilateral approach
Epstein NE et al <sup>46</sup>	2004	<i>Spine</i>	R		80	1. Patients with lumbar JFCs 2. No specified exclusion criteria	Short Form (36) Health Survey values, MacNab scores	80 L
Pirrotte B et al <sup>47</sup>	2003	<i>Journal of Neurosurgery: Spine</i>	R	1990–2001	46	1. Patients with lumbar JFCs 2. No specified exclusion criteria	Reported patients with satisfactory relief	12 IL, 24 HL 10 L
Bureau NJ et al <sup>12</sup>	2001	<i>Radiology</i>	R	1995–2000	12	1. Patients with lumbar JFCs 2. No specified exclusion criteria	MacNab scores	Fluoroscopic- and CT-guided cyst rupture
Salmon B et al <sup>48</sup>	2001	<i>Acta Neurochirurgica</i>	R	1989–1997	28	1. Patients with lumbar JFCs 2. No specified exclusion criteria	Reported percent of satisfactory relief	28 L
Banning C S et al <sup>46</sup>	2001	<i>Spine</i>	R	1993–1998	29	1. Patients with lumbar JFCs 2. No specified exclusion criteria	Measurement: completely improved/better—still some problems/no change/worse	29 L or HL
Trummer M et al <sup>49</sup>	2001	<i>Journal of Neurology, Neurosurgery, and Psychiatry</i>	R	1994–1998	19	Intractable radicular pain or neurological deficits caused JFCs	MacNab scores	6 HL, 5 L; 8 IL
Lyons MK et al <sup>50</sup>	2000	<i>Journal of Neurosurgery: Spine</i>	R	1974–1996	194	1. Patients with lumbar JFCs 2. No specified exclusion criteria	Reported patients with excellent or good scores	159 MF, 23 TF, 12 unknown

Abbreviations: CT, computerized tomography; F, fusion; FC, facetectomy; HL, hemilaminectomy; IL, interlaminar approach; JFC, juxtafacet cyst; JOA, Japanese Orthopaedic Association; L, laminectomy; M, medial; METRX, Micro Endoscopic Spine Surgery Rettractor; MF, medial facetectomy; MRI, magnetic resonance imaging; NPRS, numeric pain rating scale; NRS-11, 11-point numeric rating scale; ODI, Oswestry disability index; P, prospective; PF, posterior fixation; R, retrospective; RMDQ, Roland Morris Disability Questionnaire; SF-12, 12-item Short Form; TF, total facetectomy; VAS, visual analog scale.  
\*Percutaneous bipolar full-endoscopic procedure under continuous irrigation.



**Figure 1.** Flow diagram summarizing the process of study selection.

Table 1. Methodological quality indicators are summarized in Table 2. Overall, these noncomparative series appeared to have adequate quality.

### Open Surgery

A total of 21 studies, including 1112 patients (51.9% female), were identified. The mean age was 63 years (range 54.4–73 years). L4-L5 was the most affected level (67.3%), followed by L3-L4 (16%), L5-S1 (13.5%), L2-L3 (2.2%), and L1-L2 (1.0%). The average follow-up was 39.5 months (range 8.3–116.4 months). On average, hospital stays ranged from 3 to 7 days. Nineteen studies report the proportion of patients with preoperative degenerative listhesis at the JFC level to be 33.6%.

The most frequently used approach was laminectomy/hemilaminectomy (87.6%), followed by the interlaminar approach and flavectomy (7.5%), and laminectomy and instrumented fusion (4.9%). A medial facetectomy was usually chosen for cyst excision over a total facetectomy (5.4% vs 4.6%,  $P < 0.001$ ).

Overall, the satisfactory outcome rate after open surgical cysts excision was 93.0% (95% CI 88.3%–96.7%) (Figure 2), while the surgical adverse event rate was 1.1% (95% CI 0.1%–3.0%). Almost all the intraoperative adverse events were dural tears; only 3 epidural hematoma cases and 1 seroma occurred. Recurrence rate was low, 1.4% (95% CI 0.3%–3.2%), and surgical revision rate was 3.0% (95% CI 1.3%–5.3%). The rate of postoperative medical adverse events was negligible 0.1% (95% CI 0.0%–0.8%).

Overall, 5.9% (95% CI 0.0%–18.2%) of patients underwent unplanned intraoperative concomitant fusion in surgery, and 3.5% (95% CI 0.6%–8.0%) developed overt postoperative instability at the treated level. In

the laminectomy group, 8.5% of patients had recurrence or revision surgery for developing instability at the decompressed level. In contrast, none of the patients who underwent concomitant instrumented fusion experienced recurrences or required additional surgery for developing instability in the follow-up period ( $P < 0.001$ ).

Comparing satisfactory outcomes between patients with and without preoperative degenerative listhesis (92.7% [95% CI 85.7%–97.7%] vs 93.1% [95% CI 89.1%–95.6%]), we did not find significant differences ( $P = 0.854$ ). Also, no significant differences in recurrence rates between patients with and without degenerative listhesis were found (2.5% vs 3.0%, respectively,  $P = 0.726$ ). However, a significantly higher proportion of patients with preoperative degenerative listhesis required revision surgery than patients without listhesis (6.8% vs 3.1%, respectively,  $P = 0.020$ ). The mean time to first intervention and revision surgery ranged from 7.5 to 24 months.

### Minimally Invasive Approach

A total of 8 studies including 279 patients (women = 55.6%; mean age = 65.3 years, range 62.0–72.4 years) were identified. The most affected level was L4-L5 (62.2%), followed by L3-L4 (20.8%), L5-S1 (12.4%), and L2-L3 (4.6%). The average follow-up was 24.0 months (range 11.5–79 months). Hospital stay was consistently reported within 24 hours, while mean operative time was 130 minutes (range 58–184 minutes). Three studies describe a contralateral approach for tubular system insertion and cysts excision, while an ipsilateral method was used in 5. Six studies reported the proportion of patients with preoperative instability at the cyst level: 21.1%.

Overall, favorable outcomes were reported in 82.7% of patients (95% CI 61.2%–97.5%) (Figure 3), while surgical adverse events rate was 8.4% (95% CI 2.7%–16.3%). Most intraoperative adverse events were dural tears, and only 1 case of epidural hematoma occurred. The overall rate of patients who developed some postoperative instability was 3.2% (95% CI 0.2%–8.4%). The overall revision rate was 3.6% (95% CI 1.0%–2.3%), while overall recurrence rate was 2.3% (95% CI 0.3%–5.5%). There was no postoperative medical adversity reported. The mean time to first intervention and revision surgery ranged from 7 to 25.2 months. None of the patients underwent concomitant fusion at the time of intervention.

When comparing outcomes between patients with and without preoperative degenerative listhesis (77.8%

**Table 2.** Methodological quality evaluation.

Authors	Design	Representatives of Exposed Cohort	Selection of Nonexposed Cohort	Ascertainment of Exposure	Assesment of Outcome	Length Follow-Up
Hellinger S et al <sup>22</sup>	•	•	•	••	••	•
Tacconi L et al <sup>13</sup>	•	•	•	••	••	
Kyung-Hoon K et al <sup>14</sup>		•		•		
Hahn P et al <sup>23*</sup>	•	••		•		
Heo DH et al <sup>24</sup>		•		•	••	•
Siu CK et al <sup>25</sup>		••	•	••	•	•
Oertel JM et al <sup>26</sup>	•	•	•	••	••	
Bruder M et al <sup>27</sup>		••	•	••	•	•
Denis DR et al <sup>2</sup>		••	•	••	•	
Birch BD et al <sup>28</sup>		•		•	•	•
Eshraghi Y et al <sup>7</sup>		•		•	•	•
Zhenbo Z et al <sup>29</sup>		••	•	••	••	•
Alimi M et al <sup>30</sup>		••	•	••	•••	•
Sukkarieh HG et al <sup>31</sup>		•	•	••	••	
Knafo S et al <sup>32</sup>		•		•	•	
Komp M et al <sup>33</sup>	•	••	•	••	•••	
Ortiz O et al <sup>31</sup>		•		•	•	
Cambren SC et al <sup>11</sup>		••		••		•
Ganau M et al <sup>3</sup>		•		•	•	•
Ha SW et al <sup>35</sup>		•	•	••	•	
James A et al <sup>36</sup>		•		•	••	
Amoretti N et al <sup>11</sup>		••	•	••	••	
Landi A et al <sup>37</sup>		•	•	••	•	
Schulz M et al <sup>16</sup>	•	•		•		•
El Shazly A et al <sup>38</sup>		•		•	•	•
Matsumoto M et al <sup>39</sup>	•	•		•	•	•
Xu R et al <sup>40</sup>		••		••		
Allen TL et al <sup>10</sup>		•	•	••	•••	
Martha JF et al <sup>9</sup>		•		•	••	•
Terao T et al <sup>41</sup>		•		•	•	•
Weiner BK et al <sup>39</sup>		•		•	••	
Sehati N et al <sup>43</sup>		•		••	•	
Acharya R et al <sup>1</sup>		•		•	•	
Metellus P et al <sup>44</sup>		••		•	•	•
Deinsberger R et al <sup>15</sup>		•		•	•	•
Sandhu FA et al <sup>45</sup>		•		••	•	
Epstein NE et al <sup>46</sup>		••		•	••	
Pirotte B et al <sup>47</sup>		•		•	•	•
Bureau NJ et al <sup>12</sup>		•		•	•	
Salmon B et al <sup>48</sup>		•		•	•	•
Banning CS et al <sup>46</sup>		•		•	•	•
Trummer M et al <sup>49</sup>		••	•	•	•	
Lyons MK et al <sup>50</sup>		••		•	•	•

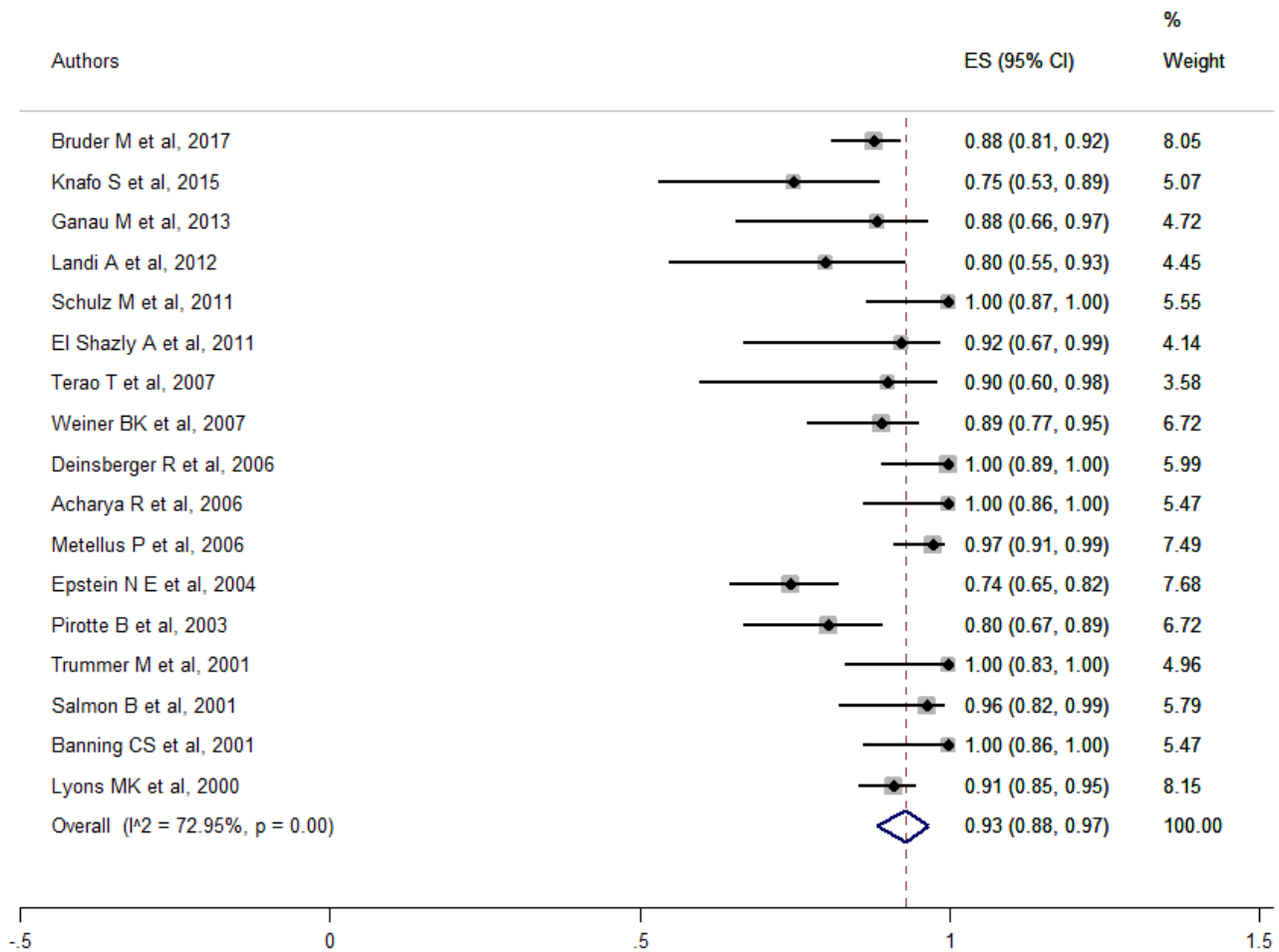
Design: One dot for prospective or randomized controlled trials. Representatives of exposed cohort: One dot for study reporting detailed inclusion criteria, two dots for studies reporting detailed inclusion and exclusion criteria. Selection of non-exposed cohort: One dot for each study reporting a control group. Ascertainment of exposure: One dot for the authors confirming the intraoperative presence of a JFC, two dots if the histological confirmation was reported and an accurate JFC description provided. Assesment of outcome: One dot for each different clinical score utilized by authors for measuring postoperative outcomes. Length of follow-up: One dot if the follow-up was more than 24 months.

[95% CI 46.7%–98.4%] vs 89.7% [95% CI 78.8%–97.6%], respectively), we found a slight decrease in the unstable patients’ outcomes ( $P = 0.011$ ). Also, higher rates of revision surgery (13.1 % [95% CI 4.8%–24.0%] vs 3.6% [95% CI 0.2%–9.4%],  $P = 0.004$ ) and intraoperative adverse events (31.3% [95% CI 18.9%–45.2%] vs 4.8% [95% CI 1.2%–9.9%],  $P < 0.001$ ) were found in the degenerative listhesis group. No differences were found between these 2 groups in terms of recurrence and adverse medical events. No differences in outcomes and adverse events were found when stratifying patients by ipsilateral and contralateral minimally invasive approach.

### Full-Endoscopic Approach

A total of 9 studies, including 263 patients (52.9% women, mean age = 49.2 years, range = 23.1–68.6 years), were identified. The most affected level was L4-L5 (70.1%), followed by L5-S1 (19.6%) and L3-L4 (10.3%). The average follow-up was 27.5 months (range 18–55.5 months). Hospital stay was consistently reported to be <24 hours, while mean operative time was 60.3 minutes (range 32–78 minutes). Three studies report the proportion of patients with degenerative listhesis at the cyst level to be 8.3%. None of the patients required additional fusion surgery in the follow-up time examined.





**Figure 2.** Forest plot for open surgery overall outcomes. ES, effect size.

Overall, favorable outcome after full-endoscopic cysts excision was 90.9% (95% CI 83.8%–96.4%) (Figure 4), while surgical adverse events rate was 1.8% (95% CI 0.0%–5.3%). Except for an epidural hematoma, all the intraoperative adverse events were dural tears, and none required additional intervention for cerebrospinal fluid (CSF) fistula development. The overall JFC recurrence rate was 3.0% (95% CI 0.0%–9.9%), while the revision rate was 2.2% (95% CI 0.0%–8.3%). There were no postoperative infections or medical complications reported.

### Percutaneous Treatment

A total of 8 studies, including 497 patients (women = 57.8%, mean age = 63.2 years, range = 58.7–68.2 years), were identified. In all the studies examined, the JFC aspiration and rupture were attempted, and

corticosteroids were locally injected. Five studies reported the caliber of the needle utilized for rupture and aspiration of cyst's content. Four studies used a 22-gauge needle, while one used a 20-gauge needle. The most affected level was L4-L5 (69.5%), followed by L5-S1 (16.5%), L3-L4 (11.6%), and L2-L3 (2.4%). The average follow-up was 24.2 months (range 11–44.5 months). On average, hospital stay was less than 1 day. One study reported the proportion of patients with preoperative instability at the cyst level to be 3.9%.

Favorable outcome rate after percutaneous rupture and aspiration was 66.2% (95% CI 52.9%–78.4%) (Figure 5), while procedural adverse events rate was 0.1% (95% CI 0.0%–1.2%). There were 2 cases of cyst rupture and bleeding in the epidural space. The overall recurrence rate was 34.3% (95% CI 20.3%–49.6%), and among those, 60.7% required additional treatment

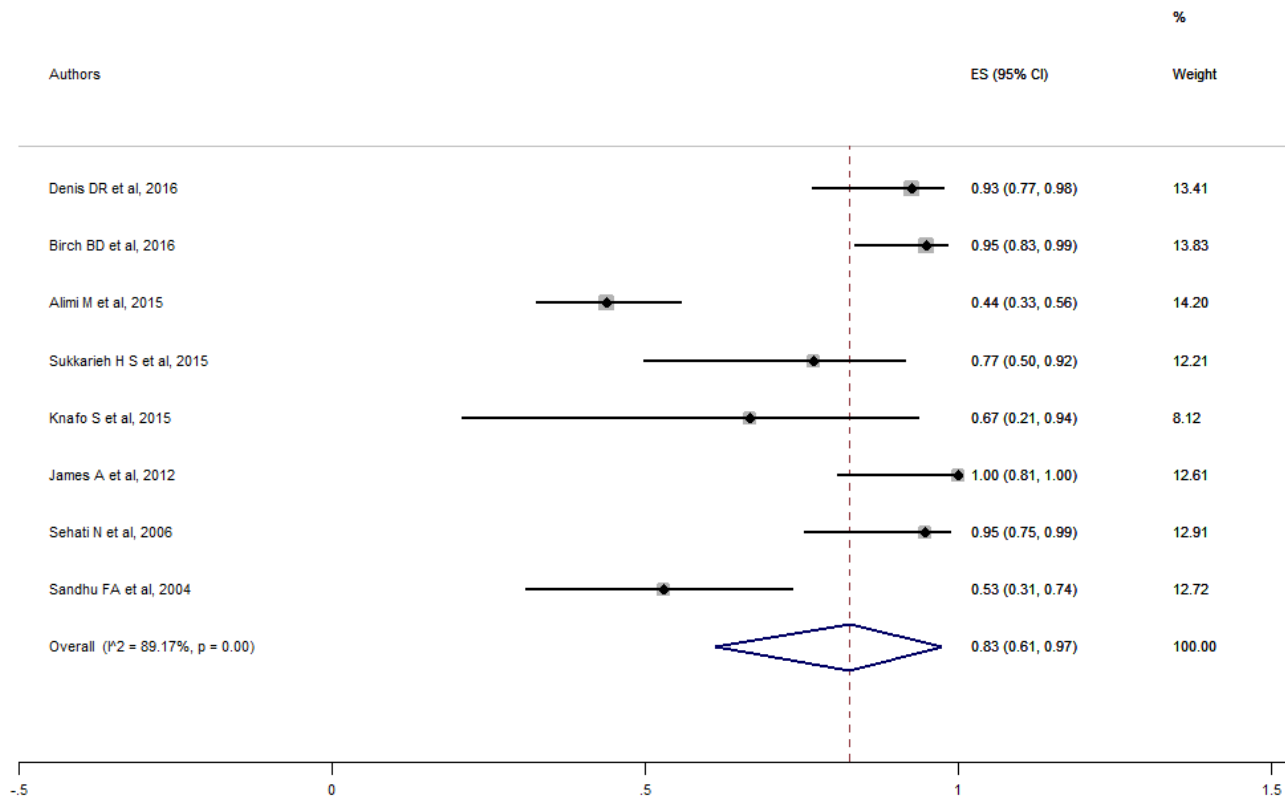


Figure 3. Forest plot for minimally invasive overall outcomes. ES, effect size.

(revision). Of the revision procedures, 47.3% underwent repeated percutaneous cyst aspiration and rupture, while 52.7% underwent surgical excision by one of the above mentioned methods. The other recurrences were treated conservatively.

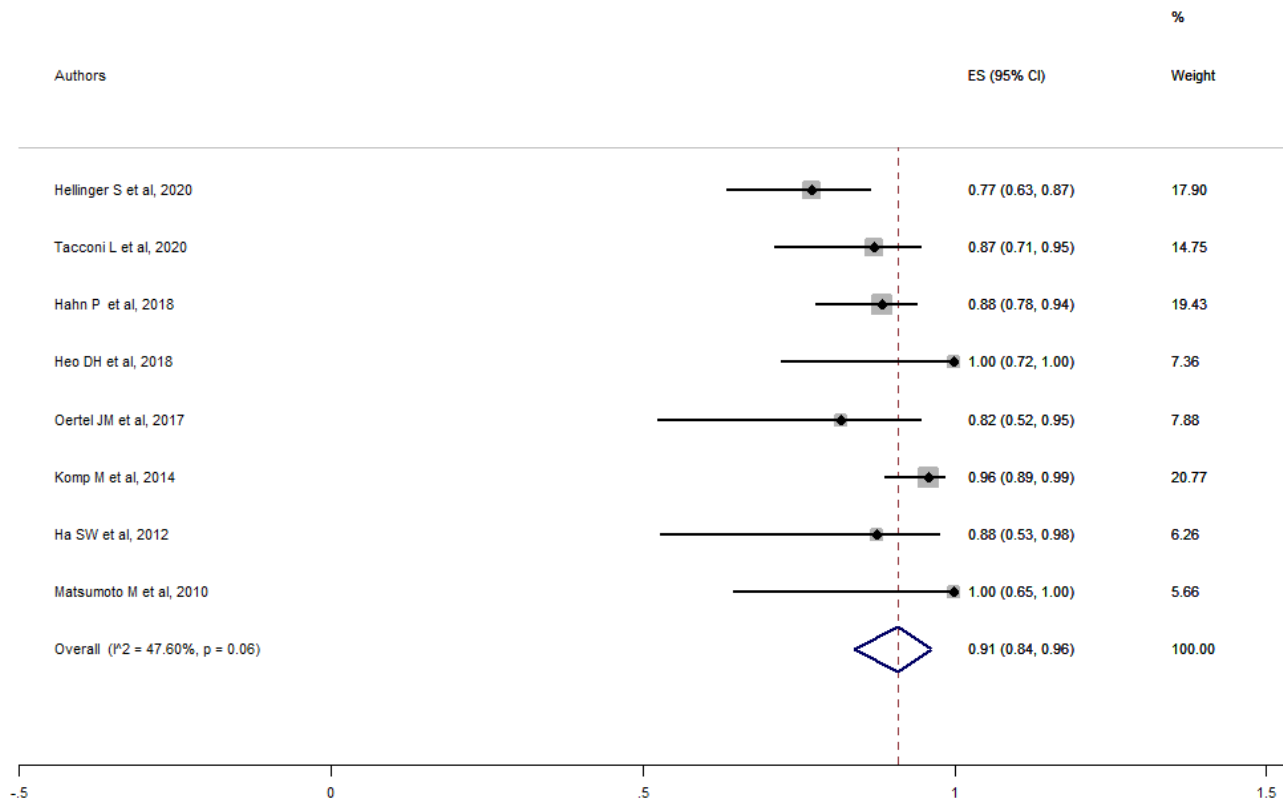
### Outcomes and Adverse Events Comparison

Overall median time from JFC excision to recurrence, excluding patients undergoing concomitant fusion surgery, was 23 months (range 1–60 months; mean 23.6 ± 20.6 months). There were no statistically significant differences in overall satisfactory outcomes between patients undergoing open, minimally invasive, and full-endoscopic approaches (Table 3). Statistically, significantly lower satisfaction rates were found between open, minimally invasive, and full-endoscopic approaches and percutaneous cysts rupture and aspiration ( $P < 0.001$ ). Higher recurrence rates were found among percutaneous cyst aspiration and rupture patients than open, minimally invasive, and full endoscopy ones ( $P < 0.001$ ). No differences in overall recurrences rates

were found between open and minimally invasive ( $P = 0.281$ ), open and full-endoscopic ( $P = 0.072$ ), and minimally invasive and full endoscopy ( $P = 0.612$ ) procedures.

No differences in overall revision rates were found between open and minimally invasive ( $P = 0.606$ ), open and full-endoscopic ( $P = 0.483$ ), and minimally invasive and full endoscopy procedures ( $P = 0.334$ ). Percutaneous cysts rupture and aspiration recurrences and revision rates were significantly higher than all other procedures ( $P < 0.001$ ). No differences in postoperative instability rates were found between open and minimally invasive approaches ( $P = 0.806$ ).

No differences in overall surgical adverse event rates were found between open and full-endoscopic procedures ( $P = 0.355$ ) but higher rates between minimally invasive and open ( $P < 0.001$ ) and full-endoscopic procedures ( $P = 0.001$ ). As expected, procedural adverse events were significantly lower for percutaneous cysts rupture and aspiration than open, minimally invasive, and full-endoscopic procedures ( $P = 0.001$ ).



**Figure 4.** Forest plot for full endoscopy overall outcomes. ES, effect size.

In our subgroup analysis (patients with preoperative degenerative listhesis vs without preoperative degenerative listhesis), open and minimally invasive surgery was used more than full-endoscopic and percutaneous procedures among patients with preoperative degenerative listhesis ( $P = 0.001$ , respectively). We additionally found lower rates of satisfactory outcomes in patients with preoperative degenerative listhesis undergoing minimally invasive approaches compared to open surgical approaches (77.8% vs 92.7%,  $P < 0.001$ ) but higher rates of adverse surgical events (31.3% vs 2.1%,  $P < 0.001$ ) and of patients requiring revision surgery (13.1% vs 6.8%,  $P$  value = 0.042).

## DISCUSSION

To the best of our knowledge, this is the most up-to-date systematic review and meta-analysis on outcomes and complications of lumbar JFC treatment. We estimated overall outcomes and adverse event rates for each surgical procedure, including percutaneous-guided cysts rupture and aspiration. We also stratified results

based on preoperative spinal stability conditions. This was done to provide a better insight into JFCs treatment, especially for open and minimally invasive procedures.

Overall, we did not find significant differences in outcomes between open, minimally invasive, and full-endoscopic cysts excision but lower satisfactory rates in patients undergoing percutaneous cysts rupture and aspiration as well as higher recurrences and revision rates. After stratifying results between patients with and without preoperative degenerative listhesis, we found slightly lower satisfactory rates but higher intraoperative adverse events and revision rates in patients with degenerative listhesis at the cyst level. Revision and adverse event rates, mainly attributable to dural tears, were higher in patients undergoing minimally invasive surgery and carrying preoperative degenerative listhesis.

Laminectomy/Hemilaminectomy has shown satisfactory outcomes in approximately 90% of patients over 6 months of follow-up,<sup>6,29,37,44,46–48,50,52</sup> though some patients still require concomitant fusion because

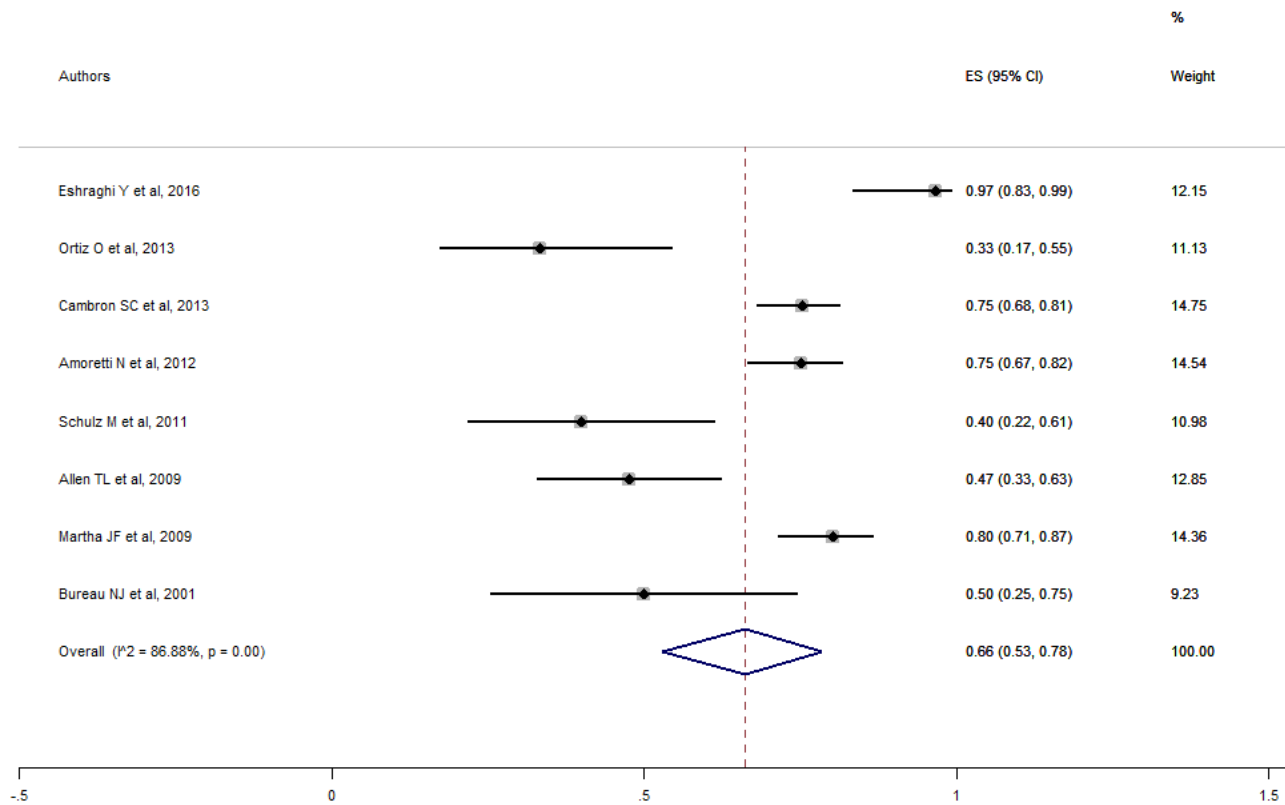


Figure 5. Forest plot for percutaneous fluoroscopic- or CT-guided overall outcomes. ES, effect size.

of preoperative instability while others required subsequent fusion due to the development of postoperative instability.<sup>25,27,38,50</sup>

Cystectomy alone may be enough for back/leg pain relief in 90% of patients, at least initially. However, decompression alone in the presence of underlying segmental instability may predispose cyst recurrence.<sup>28,29,40,42</sup> Of note, same-site recurrence was never reported in any patients receiving concomitant spinal fusion.<sup>6,40,41,52</sup>

JFC recurrence was higher in the laminectomy/hemilaminectomy patients than in patients undergoing fusion. Patients with preoperative degenerative listhesis have almost twice the risk of recurrence or revision surgery due to developing instability at the treated level.<sup>8,49</sup> However, indiscriminate fusion might aggravate adjacent level degeneration<sup>53</sup> while raising perioperative morbidity, extending hospital stay, and resulting in a higher risk of incidental durotomy and greater blood loss.<sup>25,27,32,54</sup>

Minimally invasive surgery aims to preserve the dorsal muscular and ligamentous attachments that are paramount for spinal stability.<sup>30,31,36,43</sup> It has been shown to have successful outcomes over the short- and long-term in 95% of patients.<sup>43</sup> However, the tubular approach is challenging and burdened with a higher risk of durotomy, epidural hematoma, and CSF leak in nonexperienced hands. This may be explained by the limited field of view and steep learning curve. Also, cysts adherent to the dural sheath can make dissection demanding.<sup>45</sup> These factors may explain the higher revision and adverse event rates among patients with preoperative degenerative listhesis.

Eventually, full-endoscopic techniques have reported satisfactory outcomes in treating symptomatic JFC cysts in the vast majority of cases over a mean follow-up period of >24 months.<sup>22,23,35</sup> However, it is clear from our analysis by the significantly lower percentage of patients with preoperative degenerative listhesis than open or minimally invasive approaches that endoscopic patients were carefully selected in each series.<sup>33</sup> Full

**Table 3.** Summary of outcomes and adverse events for each treatment modality.

Variable	Open Surgery	Minimally Invasive	Full Endoscopic	Percutaneous Cyst Rupture and Aspiration	P Value < 0.05
N	1112	279	263	497	
Age, y, mean (range)	63 (54.4–73)	65.3 (62–72.4)	49.2 (23.1–68.6)	63.2 (58.7–68.2)	
Sex, male	51.9%	55.6%	52.9%	57.8%	
Follow-up, mo, mean (range)	39.5 (8.3–116.4)	24.0 (11.5–79)	27.5 (18–55.5)	24.2 (11–44.5)	
Preoperative degenerative listhesis, %	33.6%	21.1%	8.3%	3.9%	
Satisfactory outcome, % MacNab excellent—good scores (95% CI)	93.0% (88.3%–96.7%)	82.7% (61.2%–97.5%)	90.9% (83.8%–96.4%)	66.2% (52.9%–78.4%)	a, b, c, d, e, f
Recurrence, % (95% CI)	1.4% (0.3%–3.2%)	2.3% (0.3%–5.5%)	3.0% (0.0%–9.9%)	34.3% (20.3%–49.6%)	c, e, f
Revisions, % (95% CI)	3.0% (1.3%–5.3%)	3.6% (1.0%–8.3%)	2.2% (0.0%–8.3%)	29.8% (18.9%–42%)	c, e, f
Developing postoperative instability, % (95% CI)	3.5% (0.6%–8.0%)	3.2% (0.2%–8.4%)	0%	/	
Intraoperative/procedural adverse events, % (95% CI)	1.1% (0.1%–3.0%)	8.4% (2.7%–16.3%)	1.8% (0.0%–5.3%)	0.1% (0.0%–1.2%)	a, d, c, e, f

Significant differences between: **a** = open vs minimally invasive; **b** = open vs full endoscopic; **c** = full-endoscopic vs percutaneous cyst aspiration and rupture; **d** = minimally invasive vs full endoscopic; **e** = minimally invasive vs percutaneous cyst aspiration and rupture; **f** = full-endoscopic vs percutaneous cyst aspiration and rupture; / : not reported.



endoscopy, especially the transforaminal approach, is associated with milder surgical trauma,<sup>24</sup> shorter operating time, negligible blood loss and CSF leakage, mild postoperative back pain, and shorter hospitalization time.<sup>13</sup>

New instruments (eg, shavers and diamond burrs) provide adequate bone resection and make cyst removal technically feasible,<sup>26</sup> but the learning curve is steep, and appropriate training is paramount for success.<sup>39</sup>

The minimally invasive technique offers similar results compared to open surgery at the cost of slightly higher adverse event rates in patients with preoperative degenerative listhesis. A trend toward higher adverse event rates, particularly postoperative nerve roots paresthesia, is similarly reported by studies comparing minimally invasive to open lumbar surgery<sup>51</sup>. By pooling such a large number of patients in subgroup analysis, we were able to confirm this trend. Our minimally invasive group results reflect a higher challenging procedure in more degenerate segments, speculatively consequent to a limited field of view and surgical freedom (instruments) inside a narrowed space leading to significant nerve root traction and manipulation compared to open surgery. Similar results may have been found in the full-endoscopic groups; however, the procedure's novelty and the stricter patient selection precluded most of the patients with degenerative degenerate segments at the cyst level to undergo endoscopy. It would be interesting to evaluate such occurrences in future analyses.

By comparison, full-endoscopic JFC excision is even less traumatic and more respectful of the articular process integrity.<sup>34</sup> Indeed, the transforaminal approach allows root and foraminal decompression without compromising spinal stability and without scar formation developing.<sup>55</sup> Thus, it is feasible to control symptoms even in mild spinal instability. Eventually, laminectomy/hemilaminectomy and fusion should be reserved in overt spinal instability cases or when total facetectomy is required for cyst excision (ie, in recurrent cases), while percutaneous cyst rupture and aspiration to patients not suited or unwilling to undergoing invasive procedures.

### Limitations

The main limitation is the lack of individual patient data, which makes prognostic analysis subject to confounding bias and limits our ability to stratify outcomes. Findings may also have been impacted by inter- and intraobserver variability in assessing the prevalence of clinical improvement, especially regarding “excellent” and “good” outcomes.

Additionally, not all the studies report every outcome evaluated in this review. Although this may have impacted the results, every attempt was made to account for heterogeneity using statistical methods. Moreover, only 5 studies were estimated to have an elevated risk of bias. Additionally, it may be argued that those cases chosen to be treated with minimally invasive or full endoscopic procedures may not be the same as treated with a conventional open procedure. Also, there is an inherent bias in the studies pooled in the meta-analysis. Many of the studies, especially minimally invasive and endoscopic, may be biased toward those procedures, thus introducing a selection bias. However, we carefully evaluated the existing literature and relative methodological flaws to account for missing information and unanswered questions relating to JFCs treatment. Considering JFCs treatments' heterogeneity, such an extensive analysis is virtually impossible without a meta-analysis process, which allows for group comparison. Therefore, the studies included in this meta-analysis were selected following a strict a priori established protocol, the literature search included multiple databases, and study selection was rigorous and based on the criteria established by the most recent guidelines. Eventually, in the meta-analysis, only studies with homogenous outcomes were included (objective and validated outcomes as described in the Methods section), excluding those who were uncertain or derived from a subjective surgeon evaluation.

## CONCLUSIONS

Besides confirming the safety and efficacy of open and minimally invasive approaches, we highlighted how full endoscopy has outcomes, rates of adverse events, and operative times that overlap those of the open and minimally invasive approaches. We believe that the spine surgeon's wealth of knowledge must include all of these techniques. These results may help the surgeon in the reasoning process of each case.

## REFERENCES

1. Acharya R, Patwardhan RV, Smith DR, Willis BK, Fowler M, Nanda A. Intraspinial synovial cysts: a retrospective study. *Neurol India*. 2006;54(1):38–41. doi:10.4103/0028-3886.24700
2. Denis DR, Hirt D, Shah S, Lu DC, Holly LT. Minimally invasive surgery for lumbar synovial cysts with coexisting degenerative spondylolisthesis. *Int J Spine Surg*. 2016;10:37. doi:10.14444/3037
3. Ganau M, Ennas F, Bellisano G, et al. Synovial cysts of the lumbar spine--pathological considerations and surgical strategy. *Neurol Med Chir*. 2013;53(2):95–102. doi:10.2176/nmc.53.95
4. Knox AM, Fon GT. The appearances of lumbar intraspinal synovial cysts. *Clin Radiol*. 1991;44(6):397–401. doi:10.1016/s0009-9260(05)80658-0

5. Cambron SC, McIntyre JJ, Guerin SJ, Li Z, Pastel DA. Lumbar facet joint synovial cysts: does T2 signal intensity predict outcomes after percutaneous rupture? *AJNR Am J Neuroradiol*. 2013;34(8):1661–1664. doi:10.3174/ajnr.A3441
6. Bydon M, Papadimitriou K, Witham T, et al. Treatment of spinal synovial cysts. *World Neurosurg*. 2013;79(2):375–380. doi:10.1016/j.wneu.2012.08.016
7. Eshraghi Y, Desai V, Cajigal Cajigal C, Tabbaa K. Outcome of percutaneous lumbar synovial cyst rupture in patients with lumbar radiculopathy. *Pain Physician*. 2016;19(7):E1019-25
8. Campbell RJ, Mobbs RJ, Rao PJ, Phan K. Interventions for lumbar synovial facet joint cysts: a comparison of percutaneous. *Surgical Decompression and Fusion Approaches World Neurosurg*. 2017;98:492–502. doi:10.1016/j.wneu.2016.11.044
9. Martha JF, Swaim B, Wang DA, et al. Outcome of percutaneous rupture of lumbar synovial cysts: a case series of 101 patients. *Spine J*. 2009;9(11):899–904. doi:10.1016/j.spinee.2009.06.010
10. Allen TL, Tatli Y, Lutz GE. Fluoroscopic percutaneous lumbar zygapophyseal joint cyst rupture: a clinical outcome study. *Spine J*. 2009;9(5):387–395. doi:10.1016/j.spinee.2008.08.008
11. Amoretti N, Huwart L, Foti P, et al. Symptomatic lumbar facet joint cysts treated by CT-guided intracystic and intra-articular steroid injections. *Eur Radiol*. 2012;22(12):2836–2840. doi:10.1007/s00330-012-2533-z
12. Bureau NJ, Kaplan PA, Dussault RG. Lumbar facet joint synovial cyst: percutaneous treatment with steroid injections and distention--clinical and imaging follow-up in 12 patients. *Radiology*. 2001;221(1):179–185. doi:10.1148/radiol.2211010213
13. Tacconi L, Spinelli R, Serra G, Signorelli F, Giordan E. Full-endoscopic removal of lumbar juxtafacet cysts: a prospective multicentric study. *World Neurosurg*. 2020;141:e414–e422. doi:10.1016/j.wneu.2020.05.166
14. Kim K-H, Kim S-Y, Ok H-G, Kim T-K. A staged treatment of symptomatic lumbar intraspinal synovial cysts. *Pain Physician*. 2019;22(5):E451–E456. doi:10.36076/ppj/2019.22.E451
15. Deinsberger R, Kinn E, Ungersböck K. Microsurgical treatment of juxta facet cysts of the lumbar spine. *J Spinal Disord Tech*. 2006;19(3):155–160. doi:10.1097/01.bsd.0000188660.31212.83
16. Schulz C, Danz B, Waldeck S, Kunz U, Mauer UM. Percutane CT-gesteuerte destruktion vs. mikrochirurgische resektion lumbaler juxtafacetzysten. *Orthopäde*. 2011;40(7):600–606. doi:10.1007/s00132-011-1744-3
17. Themistoklis KM, Papisilekas TI, Boviatsis KA, et al. Spinal synovial cysts. A case series and current treatment options. *J Clin Neurosci*. 2018;57:173–177. doi:10.1016/j.jocn.2018.08.038
18. Lasanianos NG, Triantafyllopoulos GK, Pneumaticos SG. Spondylolisthesis grades. In: Lasanianos NG, Kanakaris NK, Giannoudis PV, eds. *Trauma and Orthopaedic Classifications: A Comprehensive Overview*. London: Springer; 2015:239–242. doi:10.1007/978-1-4471-6572-9
19. Macnab I. Negative disc exploration. An analysis of the causes of nerve-root involvement in sixty-eight patients. *J Bone Joint Surg Am*. 1971;53(5):891–903. doi:10.2106/00004623-197153050-00004
20. Murad MH, Sultan S, Haffar S, Bazerbachi F. Methodological quality and synthesis of case series and case reports. *BMJ Evid Based Med*. 2018;23(2):60–63. doi:10.1136/bmjebm-2017-110853
21. Hutton B, Salanti G, Caldwell DM, et al. The PRISMA extension statement for reporting of systematic reviews incorporating network meta-analyses of health care interventions: checklist and explanations. *Ann Intern Med*. 2015;162(11):777–784. doi:10.7326/M14-2385
22. Hellinger S, Lewandrowski KU. Clinical outcomes with endoscopic resection of lumbar extradural cysts. *J Spine Surg*. 2020;6(Suppl 1):S133–S144. doi:10.21037/jss.2019.08.08
23. Hahn P, Komp M, Merk H, Godolias G, Ruetten S. Surgical treatment of lumbar juxtafacet cyst with full endoscopic interlaminar and trans-/extraforaminal approach-prospective randomized controlled study with 60 patients. *Orthop Proc*. 2012;94-B(SUPP\_XXXVII):392. doi:10.1302/1358-992X.94BSUPP\_XXXVII.EFORT2011-392
24. Heo DH, Kim JS, Park CW, Quillo-Olvera J, Park CK. Contralateral sublaminar endoscopic approach for removal of lumbar juxtafacet cysts using percutaneous biportal endoscopic surgery: technical report and preliminary results. *World Neurosurg*. 2019;122:474–479. doi:10.1016/j.wneu.2018.11.072
25. Siu KC, Stoodley MA. Decompressive laminectomy without fusion for lumbar facet joint cysts. *J Clin Neurosci*. 2018;58(August 2000):113–116. doi:10.1016/j.jocn.2018.09.013
26. Oertel JM, Burkhardt BW. Endoscopic surgical treatment of lumbar synovial cyst: detailed account of surgical technique and report of 11 consecutive patients. *World Neurosurg*. 2017;103:122–132. doi:10.1016/j.wneu.2017.02.075
27. Bruder M, Cattani A, Gessler F, et al. Synovial cysts of the spine: long-term follow-up after surgical treatment of 141 cases in a single-center series and comprehensive literature review of 2900 degenerative spinal cysts. *J Neurosurg Spine*. 2017;27(3):256–267. doi:10.3171/2016.12.SPINE16756
28. Birch BD, Aoun RJN, Elbert GA, Patel NP, Krishna C, Lyons MK. Minimally invasive tubular resection of lumbar synovial cysts: report of 40 consecutive cases. *World Neurosurg*. 2016;94:188–196. doi:10.1016/j.wneu.2016.06.125
29. Zhenbo Z, Huanting L, Jin W, Haifeng G, Yuan F, Ming L. Hemilaminoplasty for the treatment of lumbar intraspinal synovial cysts (LISCs) and literature review. *Eur Spine J*. 2016;25(11):3393–3402. doi:10.1007/s00586-014-3570-x
30. Alimi M, Hofstetter CP, Pyo SY, Paulo D, Härtl R. Minimally invasive laminectomy for lumbar spinal stenosis in patients with and without preoperative spondylolisthesis: clinical outcome and reoperation rates. *J Neurosurg Spine*. 2015;22(4):339–352. doi:10.3171/2014.11.SPINE13597
31. Sukkarieh HG, Hitchon PW, Awe O, Noeller J. Minimally invasive resection of lumbar intraspinal synovial cysts via a contralateral approach: review of 13 cases. *J Neurosurg Spine*. 2015;23(4):444–450. doi:10.3171/2015.1.SPINE14996
32. Knafo S, Page P, Pallud J, Roux FX, Abi-Lahoud G. Surgical management of spinal synovial cysts: a series of 23 patients and systematic analysis of the literature. *J Spinal Disord Tech*. 2015;28(6):211–217. doi:10.1097/BSD.0b013e31827179c8
33. Komp M, Hahn P, Ozdemir S, et al. Operation of lumbar zygoapophyseal joint cysts using a full-endoscopic interlaminar and transforaminal approach: prospective 2-year results of 74 patients. *Surg Innov*. 2014;21(6):605–614. doi:10.1177/1553350614525668
34. Ortiz AO, Tekchandani L. Improved outcomes with direct percutaneous CT guided lumbar synovial cyst treatment: advanced approaches and techniques. *J Neurointerv Surg*. 2014;6(10):790–794. doi:10.1136/neurintsurg-2013-010891
35. Ha SW, Ju CI, Kim SW, Lee S, Kim YH, Kim HS. Clinical outcomes of percutaneous endoscopic surgery for lumbar discal cyst. *J Korean Neurosurg Soc*. 2012;51(4):208–214. doi:10.3340/jkns.2012.51.4.208

36. James A, Laufer I, Parikh K, Nagineni VV, Saleh TO, Härtl R. Lumbar juxtafacet cyst resection: the facet sparing contralateral minimally invasive surgical approach. *J Spinal Disord Tech*. 2012;25(2):E13-7. doi:10.1097/BSD.0b013e31822ac4e5
37. Landi A, Marotta N, Tarantino R, et al. Microsurgical excision without fusion as a safe option for resection of synovial cyst of the lumbar spine: long-term follow-up in mono-institutional experience. *Neurosurg Rev*. 2012;35(2):245–253. doi:10.1007/s10143-011-0356-z
38. El Shazly AA, Khattab MF. Surgical excision of a Juxtafacet cyst in the lumbar spine: a report of thirteen cases with long-term follow up. *Asian J Neurosurg*. 2011;6(2):78–82. doi:10.4103/1793-5482.92162
39. Matsumoto M, Watanabe K, Tsuji T, et al. Microendoscopic resection of lumbar discal cysts. *Minim Invasive Neurosurg*. 2010;53(2):69–73. doi:10.1055/s-0030-1249052
40. Xu R, McGirt MJ, Parker SL, et al. Factors associated with recurrent back pain and cyst recurrence after surgical resection of one hundred ninety-five spinal synovial cysts: analysis of one hundred sixty-seven consecutive cases. *Spine*. 2010;35(10):1044–1053. doi:10.1097/BRS.0b013e3181bdafed
41. Terao T, Takahashi H, Taniguchi M, et al. Clinical characteristics and surgical management for juxtafacet cysts of the lumbar spine. *Neurol Med Chir*. 2007;47(6):250–257. doi:10.2176/nmc.47.250
42. Weiner BK, Torretti J, Stauff M. Microdecompression for lumbar synovial cysts: an independent assessment of long term outcomes. *J Orthop Surg Res*. 2007;2(1):3–7. doi:10.1186/1749-799X-2-5
43. Sehati N, Khoo LT, Holly LT. Treatment of lumbar synovial cysts using minimally invasive surgical techniques. *Neurosurg Focus*. 2006;20(3):1–6. doi:10.3171/foc.2006.20.3.3
44. Métellus P, Fuentes S, Adetchessi T, et al. Retrospective study of 77 patients harbouring lumbar synovial cysts: functional and neurological outcome. *Acta Neurochir*. 2006;148(1):47–54. doi:10.1007/s00701-005-0650-z
45. Sandhu FA, Santiago P, Fessler RG, Palmer S. Minimally invasive surgical treatment of lumbar synovial cysts. *Neurosurgery*. 2004;54(1):107–111. doi:10.1227/01.neu.0000097269.79994.2f
46. Banning CS, Thorell WE, Leibrock LG. Patient outcome after resection of lumbar juxtafacet cysts. *Spine*. 2001;26(8):969–972. doi:10.1097/00007632-200104150-00024
47. Pirotte B, Gabrovsky N, Massager N, Levivier M, David P, Brotchi J. Synovial cysts of the lumbar spine: surgery-related results and outcome. *J Neurosurg*. 2003;99(1 Suppl):14–19. doi:10.3171/spi.2003.99.1.0014
48. Salmon B, Martin D, Lenelle J, Stevenaert A. Juxtafacet cyst of the lumbar spine. Clinical, radiological and therapeutic aspects in 28 cases. *Acta Neurochir*. 2001;143(2):129–134. doi:10.1007/s007010170117
49. Trummer M, Flaschka G, Tillich M, Homann CN, Unger F, Eustacchio S. Diagnosis and surgical management of intraspinal synovial cysts: report of 19 cases. *J Neurol Neurosurg Psychiatry*. 2001;70(1):74–77. doi:10.1136/jnnp.70.1.74
50. Lyons MK, Atkinson JLD, Wharen RE, Deen HG, Zimmerman RS, Lemens SM. Surgical evaluation and management of lumbar synovial cysts: the Mayo Clinic experience. *J Neurosurg*. 2000;93(1 Suppl):53–57. doi:10.3171/spi.2000.93.1.0053
51. Epstein NE. More nerve root injuries occur with minimally invasive lumbar surgery: let's tell someone. *Surg Neurol Int*. 2016;7(Suppl 3):S96–S101. doi:10.4103/2152-7806.174896
52. Epstein NE, Baisden J. The diagnosis and management of synovial cysts: efficacy of surgery versus cyst aspiration. *Surg Neurol Int*. 2012;3(Suppl 3):S157–66. doi:10.4103/2152-7806.98576
53. Bydon A, Xu R, Parker SL, et al. Recurrent back and leg pain and cyst reformation after surgical resection of spinal synovial cysts: systematic review of reported postoperative outcomes. *Spine J*. 2010;10(9):820–826. doi:10.1016/j.spinee.2010.04.010
54. Khan AM, Girardi F. Spinal lumbar synovial cysts. Diagnosis and management challenge. *Eur Spine J*. 2006;15(8):1176–1182. doi:10.1007/s00586-005-0009-4
55. Tacconi L, Signorelli F, Giordan E. Is full endoscopic lumbar discectomy less invasive than conventional surgery? A randomized MRI study. *World Neurosurg*. 2020;138:e867–e875. doi:10.1016/j.wneu.2020.03.123

**Funding:** The author(s) received no financial support for the research, authorship, and/or publication of this article.

**Financial Disclosures and Conflicts of Interest:** All authors certify that they have no affiliations with or involvement in any organization or entity with any financial interest (such as honoraria; educational grants; participation in speakers' bureaus; membership, employment, consultancies, stock ownership, or other equity interest; and expert testimony or patentlicensing arrangements), or non-financial interest (such as personal or professional relationships, affiliations, knowledge or beliefs) in the subject matter or materials discussed in this manuscript.

**Corresponding Author:** Enrico Giordan, Department of Neurosurgery, Aulss 2 Marca Trevigiana, Via Piazzale 1, Treviso 31100, Italy; enrico.giordan@aulss2.veneto.it

Published 21 February 2022

This manuscript is generously published free of charge by ISASS, the International Society for the Advancement of Spine Surgery. Copyright © 2022 ISASS. To see more or order reprints or permissions, see <http://ijssurgery.com>.