

1 *This article has been accepted for publication and has undergone full peer review but has not*
2 *been through the copyediting, typesetting, pagination, and proofreading processes, that may lead*
3 *to differences between this version and the version of record.*

4

5 *Please cite this article as <https://doi.org/10.4097/kja.23900>*

6

Epub ahead of print

1 **Ultrasound mapping of soft tissue vascular anatomy in proximity of the larynx:a prospective**
2 **cohort study**

3

4 Alessandro De Cassai, M.D.¹; Margherita Iuzzolino, M.D.¹; Silvia De Pinto, M.D.¹; Giovanni
5 Zecchino, M.D.¹; Tommaso Pettenuzzo, M.D.²; Annalisa Boscolo, Ph.D.^{2,3,4}; Eugenio Biamonte,
6 M.D.⁵; Paolo Navalesi, Prof.^{2,3}; Marina Munari M.D.¹

7

8 **From the**

9 1 Sant'Antonio Anesthesia and Intensive Care Unit, University Hospital of Padova, Padova, Italy

10 2 UOC Anesthesia and Intensive Care Unit, University Hospital of Padova, Padova, Italy

11 3 Department of Medicine - DIMED, University of Padova, Padova, Italy

12 4 Thoracic Surgery and Lung Transplant Unit - Department of Cardiac, Thoracic, Vascular
13 Sciences, and Public Health, University of Padua, Italy.

14 5 Anesthesia and Intensive Care Unit, Department of Medical and Surgical Sciences, University
15 Hospital R. Dulbecco , Magna Graecia University, Catanzaro, Italy.

16 **Running title:** Vascular mapping of the larynx

17 **Address correspondence to**

18 **Alessandro De Cassai, MD;** Sant'Antonio Anesthesia and Intensive Care Unit, University Hospital
19 of Padova, Padova, Italy (**e-mail: alessandro.decassai@gmail.com**).

20 Phone: +390498216739

21 **Previous presentation in conferences:** Not applicable

22 **Conflict of interest:** No potential conflict of interest relevant to this article was reported.

23 **Funding:** Not applicable

1 **Acknowledgements:** We would like to thank Dr. Sebastiano Negro that created the illustration for
2 this research article

3 **IRB number:** AOP3019/2023

4 **Clinical trial registration number:** NCT06002178

5

Epub ahead of print

1 **Ultrasound mapping of soft tissue vascular anatomy proximal to the larynx: a prospective**
2 **cohort study**

3

4 Alessandro De Cassai, M.D.¹; Margherita Iuzzolino, M.D.¹; Silvia De Pinto, M.D.¹; Giovanni
5 Zecchino, M.D.¹; Tommaso Pettenuzzo, M.D.²; Annalisa Boscolo, Ph.D.^{2,3,4}; Eugenio Biamonte,
6 M.D.⁵; Paolo Navalesi, M.D. Prof.^{2,3}; Marina Munari, M.D.¹

7

8 ¹ Sant'Antonio Anesthesia and Intensive Care Unit, University Hospital of Padova, Padova, Italy

9 ² UOC Anesthesia and Intensive Care Unit, University Hospital of Padova, Padova, Italy

10 ³ Department of Medicine - DIMED, University of Padova, Padova, Italy

11 ⁴ Department of Cardiac, Thoracic, Vascular Sciences, and Public Health, Thoracic Surgery and Lung
12 Transplant Unit, University of Padua, Italy

13 ⁵ Department of Medical and Surgical Sciences, Anesthesia and Intensive Care Unit, University
14 Hospital R. Dulbecco, Magna Graecia University, Catanzaro, Italy

15

16 **Running title:** Vascular mapping of the larynx

17

18 **Corresponding author:**

19 Alessandro De Cassai, M.D.

20 Sant'Antonio Anesthesia and Intensive Care Unit, University Hospital of Padova, Padova, Italy

21 E-mail: alessandro.decassai@gmail.com

22 Phone: +390498216739

23

- 1 **Previous presentation in conferences:** Not applicable.
- 2 **Conflicts of interest:** No potential conflict of interest relevant to this article was reported.
- 3 **Funding:** Not applicable.
- 4 **Acknowledgements:** We would like to thank Dr. Sebastiano Negro for creating the illustrations
- 5 included in this research article.
- 6 **IRB number:** AOP3019/2023
- 7 **Clinical trial registration number:** NCT06002178

Epub ahead of print

1

2 **Ultrasound mapping of soft tissue vascular anatomy proximal to the larynx: a prospective**

3 **cohort study**

4

5

6

7 **Running title:** Vascular mapping of the larynx

Epub ahead of print

Abstract

1
2
3
4
5
6
7
8
9
10
11
12
13
14
15
16
17
18
19
20
21

Background: Bleeding incidents during percutaneous dilatational tracheostomy are concerning, and most cases occur in patients with unrecognized and unanticipated anatomical variations in the vascular anatomy. However, the extent of this variation remains unclear. To address this knowledge gap, our study aimed to comprehensively map laryngeal vascular anatomy in a cohort of adult patients.

Methods: Ultrasound assessments of the soft tissue in the neck were performed, spanning from the thyroid cartilage to the third tracheal ring and extending 2 cm laterally on both sides performed. We subdivided this area into 12 zones comprising four medial and eight lateral sections. A pre-planned form was used to document the presence of arteries or veins in each zone. The results are reported as odds ratios, 95% CIs, and corresponding P-values.

Results: Five-hundred patients were enrolled from August 14, 2023, to November 13, 2023, at the University Hospital of Padua. Arteries and veins were identified in all investigated zones (varying from a minimum of 1.0%–46.4%). The presence of vessels progressively increased from the cricothyroid membrane to the third tracheal ring and from the midline to the paramedian laryngeal area.

Conclusions: Given the prevalence of arteries and veins, particularly in areas where tracheostomies are commonly performed, we strongly advocate for routine ultrasound assessments before such procedures are performed.

Keywords: Bleeding; Complication; Mapping; Safety; Tracheostomy; Ultrasound.

1 Introduction

2 Up to 24% of patients requiring invasive mechanical ventilation may require tracheostomy [1].
3 While both surgical and percutaneous dilatational tracheostomy (PDT) have advantages and
4 disadvantages, a meta-analysis including 14 randomized controlled trials (RCTs) and 973 patients
5 showed that PDT is associated with a lower incidence of infection than surgical tracheostomy,
6 despite a higher incidence of technical difficulties [2]. However, bleeding during or immediately
7 after PDT is worrisome, and the most serious bleeding episodes occur in patients with unrecognized
8 and unanticipated anatomical variations in vascular anatomy [3]. Therefore, performing ultrasound
9 (US) assessments before PDT is recommended to reduce the incidence of complications during the
10 maneuver [4]. Initial results from US assessments performed before PDT are promising [5].
11 However, whether US assessments should be performed as routine practice has not been
12 established [4], as the variability of vascularization in the general population that could undergo this
13 procedure is not known.

14 In order to investigate this variability, this study aimed to map the vascular anatomy of the soft
15 tissue in front of the larynx in a cohort of adult patients eligible for elective surgery. This study
16 aimed and create a valuable reference tool for clinicians performing percutaneous tracheostomies.
17 Our secondary aims were to establish the odds ratio (OR) for the risk of vessel puncture in different
18 anatomical zones and to determine the OR associated with the potential risk of vessel
19 puncture in individualized anatomical zones.

1 **Materials and methods**

2 This prospective observational study was conducted in the operating room of the Sant'Antonio
3 University Hospital of Padova. The study protocol, which was designed in accordance with the 1964
4 Declaration of Helsinki and its later amendments, was approved by the Ethics Committee for Clinical
5 Research of the University Hospital of Padova (Reference: AOP3019/2023) and prospectively
6 registered at Clinicaltrials.gov (Reference: NCT06002178). Written informed consent was obtained
7 from all the participants. The inclusion criteria were patients aged > 18 years with a planned US
8 assessment of the neck (e.g., orthopedic or neck surgeries and central venous catheterization), and
9 The exclusion criteria were previous tracheostomy and lack of consent. The following demographic
10 and clinical data were obtained directly from the patient: sex, age, weight, height, and history of
11 previous neck surgery or radiotherapy.

12 As shown in Fig. 1, the anterior region of the neck was divided into 12 zones, including four medial
13 areas and eight lateral areas. The four medial areas were divided into the thyroid cartilage and
14 cricothyroid membrane (area 2), lower edge of the cricothyroid membrane to the lower edge of the
15 first tracheal ring (area 5), lower edge of the first tracheal ring to the lower edge of the second
16 tracheal ring (area 8), and lower edge of the second tracheal ring to the lower edge of the third
17 tracheal ring (area 11). The eight lateral areas were divided into 2-cm wide lateral quadrants on
18 both the right and left sides of the above-mentioned medial areas (areas 1, 4, 7, and 10 on the left
19 and areas 3, 6, 9, and 12 on the right).

20 To identify the vascular structures within each quadrant, ultrasound Doppler examinations were
21 performed with a linear 5–12 MHz probe on both the longitudinal and transverse axes. Arteries
22 were identified as pulsatile anechoic structures, while veins were identified as anechoic non-

1 pulsatile structures.; For both arteries and veins, color Doppler was performed to confirm the first
2 impression. Two experts in vascular ultrasound (MI and ADC) performed all the examinations. The
3 presence of veins (yes/no) or arteries (yes/no) and their sizes in each zone were reported on a pre-
4 planned form. To avoid bias, the carotid arteries and jugular veins were excluded whenever they
5 were identified in the lateral quadrants.

6 Considering that different patient positions can affect the size of vessels and impede vein
7 identification [6], all patients were evaluated in the supine position. Moreover, to simulate the
8 intrathoracic pressure increase that occurs during positive-pressure mechanical ventilation, patients
9 were asked to perform the Valsalva maneuver during the US exam.

10

11 **Statistical analysis**

12 Given the observational nature of the study and the lack of previous studies, a formal sample size
13 calculation was not performed. Instead, we enrolled as many patients as possible over a one-year
14 span to a maximum of 500 patients, as approved by the Institutional Review Board. The Shapiro-
15 Wilk test was used to assess the variable distribution normality. Normally distributed continuous
16 variables are described as means \pm SD, while non-normally distributed continuous variables are
17 reported as medians (Q1, Q3). Categorical variables are described as absolute numbers
18 (percentages). The results were reported as ORs, 95% CIs, and P-values. Statistical significance was
19 set at $P < 0.05$. All statistical analyses were performed using R version 4.0.2 (The R Foundation for
20 Statistical Computing).

1 **Results**

2 A total of 500 patients were enrolled between August 14, 2023, and November 13, 2023 (Fig. 2).
3 The demographic patient characteristics are shown in Table 1. UUS assessments were successfully
4 completed for each patient, and the results for each zone are reported in Table 2. The lowest
5 proportion of vessels was found in zone 2 (arteries 1.6%, veins 1.0% of the total vessels identified),
6 whereas the highest proportion was in zone 12 (arteries 36.7%, veins 46.4% of the total vessels
7 identified).

8 We stratified the risk of vessel retrieval for each tracheal ring (Table 3) and between the medial and
9 lateral zones. A lateral puncture during PDT was associated with a higher risk of venous puncture
10 (449 patients [90%]) than a central puncture (133 patients [27%]), with an OR of 24.13 (95% CI:
11 17.12, 34.58; $P < 0.001$).

12 In addition, a lateral approach was associated with a higher risk of arterial puncture (434 patients
13 [87%]) than a central puncture (141 patients [28%]), with an OR of 16.65 (95% CI: 12.11, 23.17; $P <$
14 0.001).

1 **Discussion**

2 The main finding of our study was that blood vessels were found in all zones surrounding the
3 larynx. Furthermore, the distribution of these vessels is not uniform, but progressively increases
4 from the cricothyroid membrane to the third tracheal ring, and from the midline to the paramedian
5 laryngeal areas.

6 In our study, we demonstrated that although the risk of puncture during PDT in certain areas may
7 appear to be low, all the regions studied carry a risk of vascular puncture. Bleeding during or
8 immediately after PDT is rare, though not exceptional, that and accounts for 10% of all PDT-
9 associated complications [7].

10 A 2012 national survey on catastrophic complications during tracheostomy found that, while
11 bronchoscopy guidance was commonly used (46.5%) [8], US guidance before or after the procedure
12 was not reported [8]. This indicates that the use of US in PDT has not become widespread. Our
13 findings provide support for including US examination as an assessment tool before PDT.

14 PDT is typically performed between the second and third tracheal rings because a higher-level
15 tracheostomy is associated with a higher risk of tracheal stenosis and more difficult surgical
16 correction in the subglottic area [9]. However, in emergencies or for patients with unique
17 anatomical features that make conventional locations impractical, PDTs have been performed
18 between the first and second tracheal rings [10]. One mechanism of tracheal stenosis after PDT is
19 tracheal ischemia caused by excessive pressure on the tracheal wall [9]. Based on our results, we
20 hypothesized that reduced vessel representation and blood perfusion in the upper laryngeal region
21 may contribute to a higher incidence of subglottic stenosis. However, further studies employing
22 other imaging techniques such as angiography are necessary to verify this hypothesis.

1 Our study has some limitations. First, the study was performed at a single center; therefore, our
2 population is not representative of the overall population. Second, two subgroups of patients of
3 particular interest for analysis (history of neck radiotherapy and obese patients) were
4 underrepresented. In the future, it studies focusing on these particular subgroups are necessary to
5 verify possible discrepancies with our results.

6 In conclusion, we found that the cervical region surrounding the larynx is highly vascularized, with
7 a progressive increase in the number of vessels he number from the cricothyroid membrane to the
8 third tracheal ring and from the midline to the paramedian laryngeal areas. Performing US
9 assessments before PDT is strongly recommended.

Epub ahead of print

References

1. Mehta C, Mehta Y. Percutaneous tracheostomy. *Ann Card Anaesth* 2017; 20(Supplement): S19-25.
2. Putensen C, Theuerkauf N, Guenther U, Vargas M, Pelosi P. Percutaneous and surgical tracheostomy in critically ill adult patients: a meta-analysis. *Crit Care* 2014; 18: 544.
3. McCormick B, Manara AR. Mortality from percutaneous dilatational tracheostomy. A report of three cases. *Anaesthesia* 2005; 60: 490-5.
4. Alansari M, Alotair H, Al Aseri Z, Elhoseny MA. Use of ultrasound guidance to improve the safety of percutaneous dilatational tracheostomy: a literature review. *Crit Care* 2015; 19: 229.
5. Meredith S, Kattih Z, Garcia B, Lakticova V, Mina B, Oks M, et al. Utility of bedside ultrasound in percutaneous tracheostomy. *J Intensive Care Med* 2024; 39: 447-54.
6. Kosugi K, Yamada Y, Yamada M, Yokoyama Y, Fujiwara H, Yoshida K, et al. Posture-induced changes in the vessels of the head and neck: evaluation using conventional supine CT and upright CT. *Sci Rep* 2020; 10: 16623.
7. Narwani V, Dacey S, Lerner MZ. Adverse events associated with tracheostomy: a MAUDE database analysis. *Otolaryngol Head Neck Surg* 2024; 170: 391-5.
8. Das P, Zhu H, Shah RK, Roberson DW, Berry J, Skinner ML. Tracheotomy related catastrophic events: results of a national survey. *Laryngoscope* 2012; 122: 30-7.
9. Raghuraman G, Rajan S, Marzouk JK, Mullhi D, Smith FG. Is tracheal stenosis caused by percutaneous tracheostomy different from that by surgical tracheostomy? *Chest* 2005; 127: 879-85.

10. Ferraro F, Marullo L, d'Elia A, Izzo G. Elective tracheostomy in intensive care unit: looking between techniques, a three cases report. *Indian J Anaesth* 2014; 58: 190-2.

Epub ahead of print

Table 1. Demographic characteristics of enrolled patients

Variable	n = 500
Male gender (%)	289 (57.8)
Age, years	65 (51, 77)
Height, cm	171 (165, 178)
Weight, kg	72 (63.5, 80)
Body mass index, kg/m ²	24.30 (22.43, 26.82)
Previous neck surgery (%)	23 (4.6)
Previous neck radiotherapy (%)	0 (0)

Values are presented as medians (Q1 and Q3) or numbers (%).

Epub ahead of print

Table 2. Detailed results for each zone assessed in the study

Zone	Arteries	Veins
1	20 (4.0%)	13 (2.6%)
2	8 (1.6%)	5 (1.0%)
3	23 (4.6%)	31(6.2%)
4	46 (9.2%)	48 (9.6%)
5	30 (6.0%)	20 (4.0%)
6	93 (18.6%)	99 (19.8%)
7	125 (25.0%)	137 (27.4%)
8	27 (5.4%)	33 (6.6%)
9	216 (43.2%)	232 (46.4%)
10	181 (36.3%)	181 (36.3%)
11	95 (19.1%)	89 (17.8%)
12	183 (36.7%)	232 (46.4%)

Values are presented as numbers (%).

Table 3. Statistical analysis for the risk of vessel retrieval for each tracheal ring

	Arteries	OR (95% CI)	P- value	Veins	OR (95% CI)	P- value
Thyroid cartilage- cricothyroid membrane	48 (9.6%)	Reference	-	49 (9.8%)	Reference	-
First ring	153 (30.7%)	4.13 (2.92, 5.94)	< 0.001	149 (29.9%)	3.89 (2.75, 5.58)	< 0.001
Second ring	293 (58.7%)	13.33 (9.42, 18.85)	< 0.001	311 (62.3%)	15.14 (10.72, 21.40)	< 0.001
Third ring	334 (66.9%)	18.94 (13.34, 26.91)	< 0.001	352 (70.5%)	21.89 (15.40, 31.12)	< 0.001

Values are presented as numbers (%) or (95% CI). OR: odds ratio

Figure legend

Fig. 1. Graphical representation of the individuated zones used in the study.

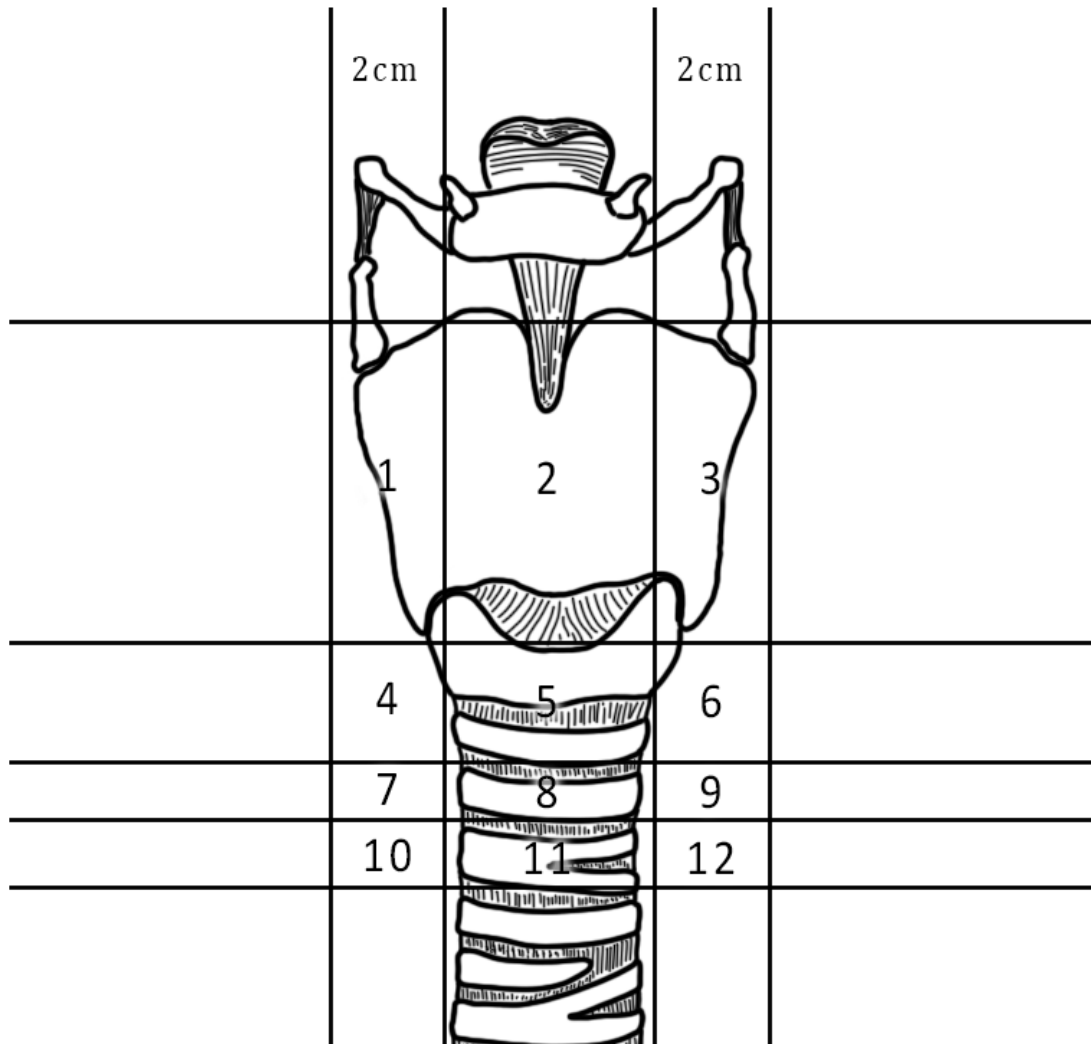


Fig. 2. Study flowchart. n: number of patients

