

ORIGINAL RESEARCH

Coronary Angiography After Transcatheter Aortic Valve Replacement (TAVR) to Evaluate the Risk of Coronary Access Impairment After TAVR-in-TAVR

Luca Nai Fovino, MD, PhD*; Andrea Scotti, MD*; Mauro Massussi, MD; Francesco Cardaioli, MD; Giulio Rodinò, MD; Yuji Matsuda, MD, PhD; Andrea Pavei, MD, PhD; Giulia Masiero, MD; Massimo Napodano, MD, PhD; Chiara Fraccaro, MD, PhD; Tommaso Fabris, MD; Giuseppe Tarantini , MD, PhD

BACKGROUND: Transcatheter aortic valve replacement (TAVR)-in-TAVR is a possible treatment for transcatheter heart valve (THV) degeneration. However, the displaced leaflets of the first THV will create a risk plane (RP) under which the passage of a coronary catheter will be impossible. The aim of our study was to evaluate the potential risk of impaired coronary access (CA) after TAVR-in-TAVR.

METHODS AND RESULTS: We prospectively performed coronary angiography after TAVR with different THVs in 137 consecutive patients, looking where the catheter crossed the valve frame. If coronary cannulation was achieved from below the RP, the distance between valve frame and aortic wall was measured by aortic angiography. CA after TAVR-in-TAVR was defined as feasible if the catheter passed above the RP, as theoretically feasible if passed under the RP with valve-to-aorta distance >2 mm, and as unfeasible if passed under the RP with valve-to-aorta distance ≤2 mm. Seventy-two patients (53%) received a Sapien 3 THV, 26 (19%) received an Evolut Pro/R THV, and 39 (28%) received an Acurate Neo THV. CA after TAVR-in-TAVR was considered feasible in 40.9% (68.1%, 19.2%, and 5.1%, respectively; $P<0.001$), theoretically feasible in 27.7% (8.3%, 42.3%, and 53.8%, respectively; $P<0.001$), and unfeasible in 31.4% (23.6%, 38.5%, and 41.1%, respectively; $P=0.116$). Independent predictors of impaired CA after TAVR-in-TAVR were female sex (odds ratio [OR], 3.99; 95% CI, 1.07–14.86; $P=0.040$), sinotubular junction diameter (OR, 0.62; 95% CI, 0.48–0.80; $P<0.001$), and implantation of a supra-annular THV (OR, 6.61; 95% CI, 1.98–22.03; $P=0.002$).

CONCLUSIONS: CA after TAVR-in-TAVR might be unfeasible in >30% of patients currently treated with TAVR. Patients with a small sinotubular junction and those who received a supra-annular THV are at highest risk of potential CA impairment with TAVR-in-TAVR.

Key Words: coronary access ■ durability ■ structural valve degeneration ■ TAVR-in-TAVR ■ transcatheter aortic valve replacement ■ valve-in-valve

See Editorial by Mukherjee and Lange

As transcatheter aortic valve replacement (TAVR) indication is moving toward younger patients with longer life expectancy,^{1–5} transcatheter heart valve (THV) degeneration will be increasingly common.

In this setting, TAVR-in-TAVR seems an appealing alternative to conventional surgery, although data are scant. Concerns have been raised about the risk of acute coronary obstruction and the possibility of reaccessing the

Correspondence to: Giuseppe Tarantini, MD, PhD, Department of Cardiac, Thoracic, Vascular Sciences and Public Health, University of Padova, Via Giustiniani 2, 35128 Padova, Italy. E-mail: giuseppe.tarantini.1@gmail.com

Supplementary Materials for this article are available at <https://www.ahajournals.org/doi/suppl/10.1161/JAHA.120.016446>

*Dr Nai Fovino and Dr Scotti contributed equally to this work and are co-first authors.

For Sources of Funding and Disclosures, see page 10.

© 2020 The Authors. Published on behalf of the American Heart Association, Inc., by Wiley. This is an open access article under the terms of the Creative Commons Attribution-NonCommercial-NoDerivs License, which permits use and distribution in any medium, provided the original work is properly cited, the use is non-commercial and no modifications or adaptations are made.

JAHA is available at: www.ahajournals.org/journal/jaha

CLINICAL PERSPECTIVE

What Is New?

- This study is the first to address the issue of potential unfeasibility of coronary access after transcatheter aortic valve replacement (TAVR)-in-TAVR in consecutive patients undergoing coronary angiography after TAVR.
- According to our coronary angiography-based algorithm, redo TAVR might be unfeasible in 1 of every 3 patients currently undergoing TAVR, based on the potential risk of coronary access impairment.
- Implantation of a supra-annular transcatheter heart valve, female sex, and small sinotubular junction dimensions are independent predictors of possible coronary access impairment after TAVR-in-TAVR.

What Are the Clinical Implications?

- The results of this study are important for patient counseling and prosthesis selection for patients with longer life expectancy.
- Recognition of anatomic features potentially impairing coronary access after redo TAVR, such as a narrow sinotubular junction, might guide the choice of prosthesis toward intra-annular, lower frame transcatheter heart valves.

Nonstandard Abbreviations and Acronyms

| | |
|-------------|--|
| CA | coronary access |
| CCH | coronary cannulation height |
| ID | implantation depth |
| LCA | left coronary artery |
| RP | risk plane |
| RCA | right coronary artery |
| STJ | sino-tubular junction |
| TAVR | transcatheter aortic valve replacement |
| THV | transcatheter heart valve |
| VTA | valve-to-aorta distance |

coronaries once the second prosthesis is in place.^{6–9} In fact, when the second THV is implanted, the leaflets of the first prosthesis are displaced vertically, creating a cylindrical cage that will impair coronary cannulation and possibly coronary flow. Accordingly, it is possible to identify a risk plane (RP) under which the first valve frame cannot be crossed after TAVR-in-TAVR.

In this study, we prospectively performed coronary angiography after TAVR with different types of devices, aiming to evaluate the risk of possible coronary access (CA) impairment after the implantation of a second THV.

METHODS

Study Population

The data, analytic methods, and study materials will be available to other researchers for purposes of reproducing the results or replicating the procedure on reasonable request.

Patients undergoing TAVR for severe symptomatic aortic stenosis at our center from November 2018 to August 2019 were considered for this study. Selective cannulation of both the right coronary artery (RCA) and the left coronary artery (LCA) was attempted directly after THV implantation. Patients treated for surgical aortic bioprostheses degeneration (ie, valve-in-valve) and those without device success defined according to VARC-2 (Valve Academic Research Consortium) criteria¹⁰ were excluded. Indications for TAVR, approach, and prosthesis choice were based on the heart team's decision. All patients underwent coronary angiography and multidetector computed tomography evaluation before TAVR. The study protocol was approved by the cardiovascular section in-house Ethics Committee on Human Research of the Padua Province. All participants gave their informed consent for both for TAVR and coronary angiography.

RP of Different THVs

THVs used were the intra-annular Sapien 3 and Ultra (Edwards Lifesciences), the supra-annular Evolut R and Pro (Medtronic), and the Acurate Neo (Boston Scientific). The RP was defined, according to manufacturer's instruction, as the level under which the stent frame of the first THV would be covered after its leaflets were displaced vertically with the implantation of a second TAVR device (Figure 1A).^{11,12}

Intra-annular balloon-expandable Edwards Sapien 3 and Ultra have a low frame height (15.5–22.5 mm, according to valve size) and an upper row of open cells, where commissural posts are located. Accordingly, the RP is found ≈1 mm below the upper part of the prosthesis frame.

The frame of the supra-annular self-expanding Evolut R and Pro extends beyond the coronary ostia jailing the coronary sinuses and has a constrained central portion. CA is possible through the prosthesis frame cells. Importantly, the height of commissural posts, and thus of the RP, is 26 mm from the bottom part of the THV.

The supra-annular self-expanding Acurate Neo valve has a commissural post height (and thus an RP) of 28 to 31 mm according to valve size but carries an open cell architecture in the upper part of the frame that allows easier access to the coronary ostia.

CA After TAVR

Coronary angiography after TAVR was performed in all cases through the transfemoral approach. A first

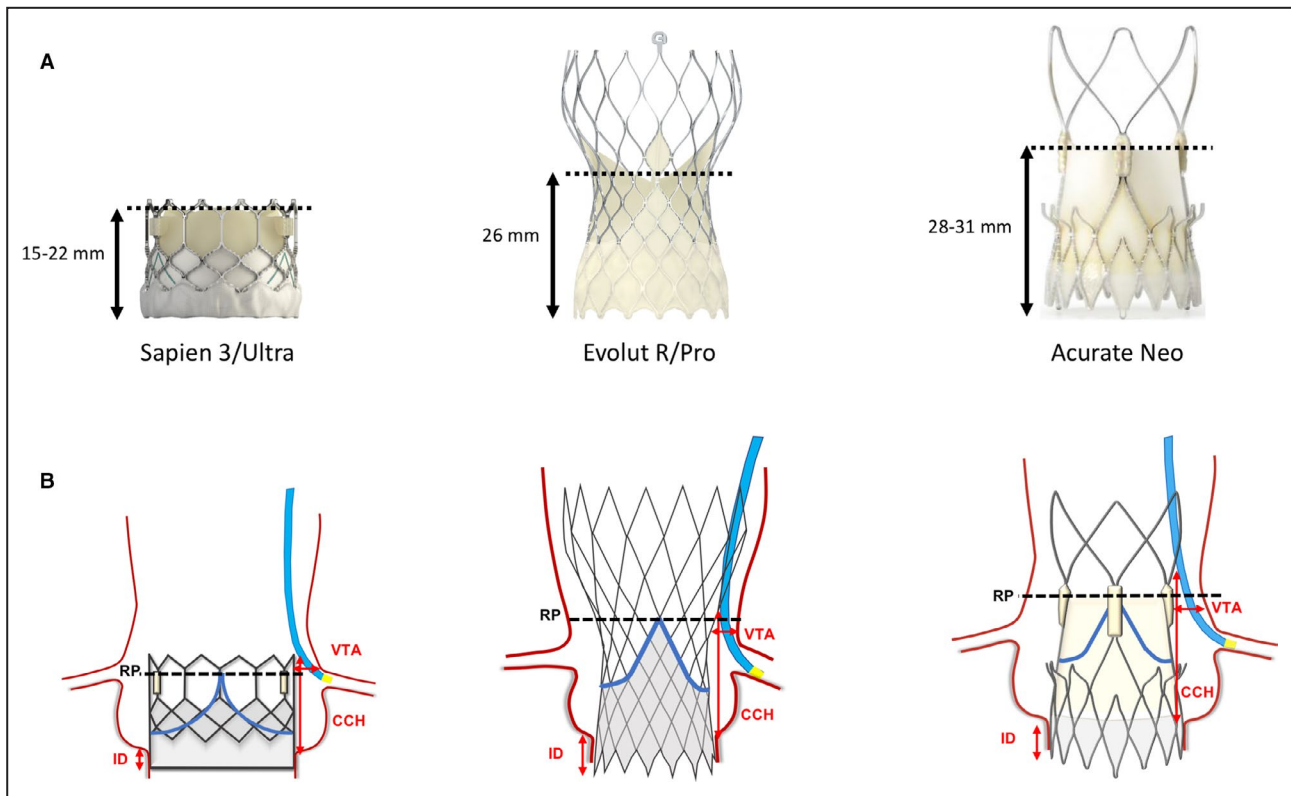


Figure 1. Risk-plane height and angiographic measurements to assess coronary access feasibility after TAVR-in-TAVR.

A, Risk plane (RP) level for Sapien 3/Ultra (Edwards Lifesciences), Evolut R/Pro (Medtronic), and Acurate Neo (Boston Scientific) transcatheter heart valves (THVs). **B**, Angiographically acquired measurements with the first THV in place. CCH indicates coronary cannulation height; ID, implantation depth; and VTA, valve-to-aorta distance.

attempt was made to cannulate the coronaries from above the RP with standard diagnostic catheters (Judkins Right and Left; Cordis). If cannulation from above the RP was unsuccessful, CA was attempted from below the RP (with the same catheter or with an Amplatz Left/Right diagnostic catheter or an extra backup guiding catheter if coronary cannulation with a standard diagnostic catheter was impossible). CA was defined as selective if successful intubation of the coronary ostium was achieved, as nonselective if the coronary artery could be displayed and adequately evaluated without full intubation, or as unfeasible if the coronary artery could not be displayed. All angiographic images were independently reviewed by 2 experienced interventional cardiologists (L.N.F. and G.T.).

Angiographic Measurements

Aorta, LCA, and RCA angiograms directly after TAVR were obtained and analyzed in multiple optimized views aiming for elimination of prosthesis frame parallax (Figure S1). Measurements acquired are summarized in Figure 1B. Coronary cannulation height (CCH) was measured as the distance between the aortic valve and the level at which the catheter crossed the

prosthesis frame. Valve-to-aorta (VTA) distance was measured as the minimum distance between the prosthesis frame and the aortic wall under the RP level. A VTA >2 mm was considered necessary for a 6-French catheter to theoretically navigate behind the frame struts and engage the coronary ostia.⁷

Feasibility of CA After TAVR-in-TAVR

Three possible scenarios are conceptualized in Figure 2 based on type of CA after index TAVR and VTA. CA after TAVR-in-TAVR was considered feasible when coronary cannulation after the first TAVR was possible from above the RP. When coronary cannulation was achieved below the RP, VTA was assessed. CA after TAVR-in-TAVR was considered theoretically feasible if VTA was >2 mm and unfeasible if VTA was \leq 2 mm. Feasibility of CA was initially evaluated on the basis of LCA cannulation. All feasible and theoretically feasible cases were then reviewed regarding RCA engagement.

Statistical Analysis

Baseline characteristics are described as mean \pm SD or median (interquartile range) for continuous variables and as percentages for discrete variables. Continuous

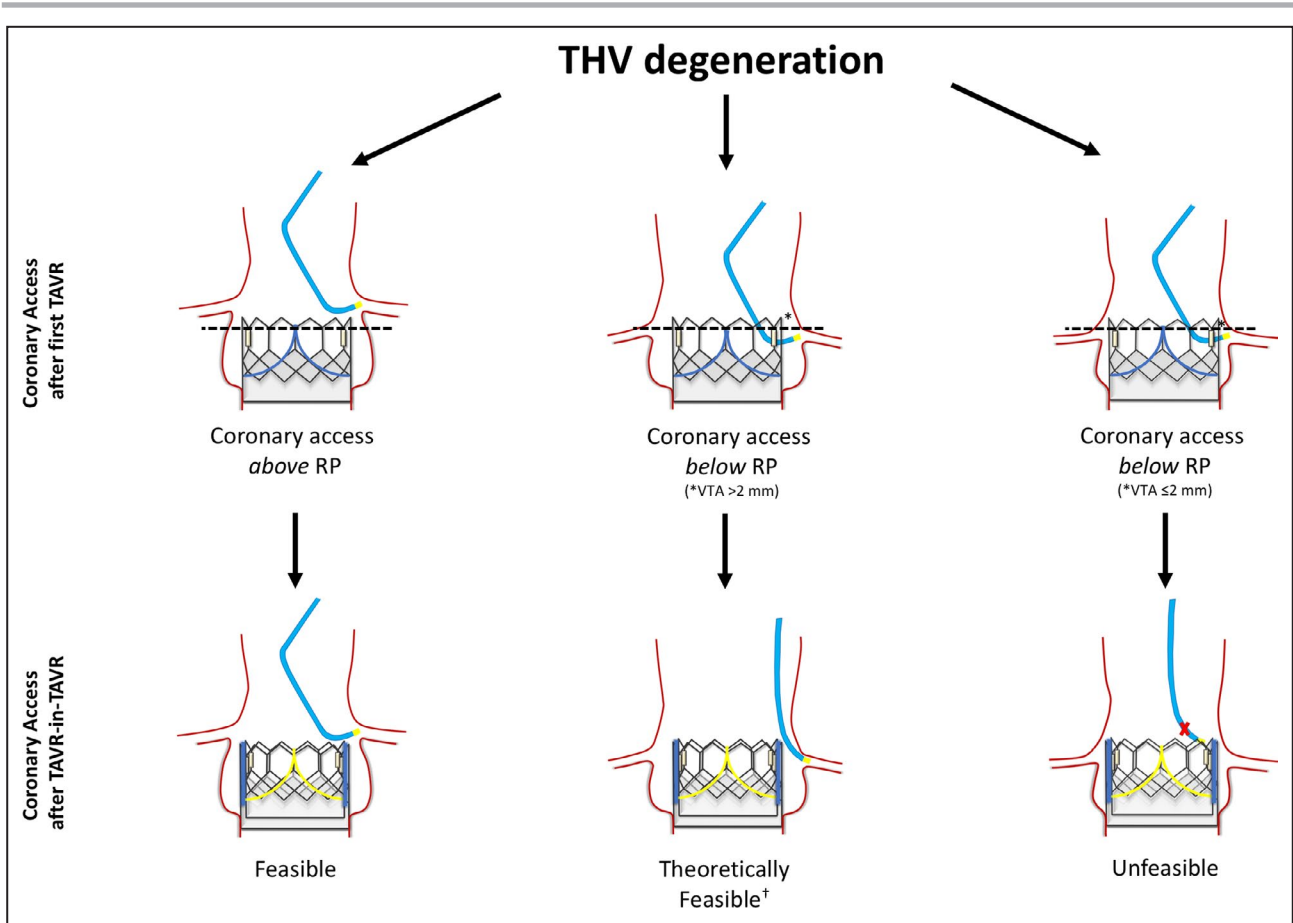


Figure 2. Proposed algorithm for assessment of coronary access (CA) feasibility after transcatheter aortic valve replacement (TAVR)-in-TAVR.

If coronary cannulation after index TAVR is achieved from above the risk plane (RP; dashed line), CA after TAVR-in-TAVR is considered feasible. If the catheter crosses the valve frame below the RP, engagement of coronary ostia is considered theoretically feasible in the presence of a valve-to-aorta distance (VTA) >2 mm (asterisk). On the contrary, in the presence of a VTA ≤2 mm, TAVR-in-TAVR will impede future CA and possibly cause acute coronary obstruction. †Coronary access challenging in case of TAVR-in-TAVR with 2 Evolut R/Pro transcatheter heart valves.

variables were compared with 1-way ANOVA and the Student unpaired *t* test (parametric test) or the Kruskal–Wallis test and Wilcoxon rank sum test (non-parametric test) for 3 or 2 groups, respectively. Normal distribution was evaluated with the Shapiro–Wilk test. Categorical variables (as frequencies or percentage) were compared with the χ^2 test or the Fisher exact test, as appropriate. Logistic regressions were used to estimate the independent effect of multiple independent variables on the risk of TAVR-in-TAVR unfeasibility. Only the covariates that were significantly associated with the risk of unfeasibility at univariate analysis ($P < 0.05$ for model inclusion and $P > 0.10$ for exclusion; Table S1) and those considered clinically relevant were included, and the convention of limiting the number of independent variables to 1 for every 10 events was followed.¹³ Hosmer and Lemeshow and C-statistic tests were used to assess the goodness of fit for logistic regression models and the predictive model discriminatory

power, respectively. The results of such analysis are presented as odds ratios (ORs) and 95% CIs. For all analyses, a 2-sided $P < 0.05$ was considered significant. Statistical analyses were performed using SPSS 24.0.0 (IBM Corp).

RESULTS

Baseline Characteristics

A total of 137 patients (48% female) with a mean age of 79.1 ± 7.0 years and mean logistic Euroscore II of 4.1 ± 3.0 were included in the study. Seventy-two (53%) received a Sapien 3 THV, 26 (19%) received an Evolut R/Pro THV, and 39 (28%) received an Acurate Neo THV. Baseline demographic characteristics were similar among valve groups (Table 1). Computed tomography-acquired aortic valve and root measurements are depicted in Table 1. Most parameters were comparable between groups. Patients receiving an intra-annular

Table 1. Baseline Characteristics and Procedural Data by THV

| Clinical Characteristics | Sapien 3/Ultra (n=72) | Evolut R/Pro (n=26) | Acurate Neo (n=39) | Total (N=137) | P Value |
|---|-----------------------|---------------------|--------------------|---------------|---------|
| Age, y | 77.9±7.9 | 80.4±6.4 | 80.3±5.1 | 79.1±7.0 | 0.148 |
| Female | 46 (33) | 35 (9) | 61.5 (24) | 48 (66) | 0.088 |
| Euroscore II | 4.5±3.6 | 3.8±2 | 3.5±2.2 | 4.1±3.0 | 0.214 |
| Hypertension | 86 (62) | 88 (23) | 87 (34) | 87 (119) | 0.951 |
| Dyslipidemia | 65 (47) | 80 (21) | 74 (29) | 71 (97) | 0.359 |
| Diabetes mellitus | 31 (22) | 31 (8) | 31 (12) | 31 (42) | 0.989 |
| COPD | 26.5 (19) | 8 (2) | 15 (6) | 20 (27) | 0.105 |
| Coronary artery disease | 62.5 (45) | 58 (15) | 59 (23) | 60.5 (83) | 0.894 |
| Previous PCI | 30.5 (22) | 31 (8) | 31 (12) | 31 (42) | 0.953 |
| Previous CABG | 15 (11) | 0 | 13 (5) | 12 (16) | 0.136 |
| Atrial fibrillation | 30 (21) | 27 (7) | 15 (6) | 25 (34) | 0.276 |
| Prior pacemaker | 10 (7) | 4 (1) | 5 (2) | 7 (10) | 0.256 |
| LVEF, % | 54.2±11.4 | 56.7±13.1 | 57.6±11.1 | 55.6±11.6 | 0.313 |
| CT baseline | | | | | |
| Annulus area | 450±84 | 401±117 | 395±62 | 425±84 | 0.005 |
| Annulus perimeter | 76.8±7.2 | 74.5±13.3 | 73.7±4.8 | 75.4±8.4 | 0.233 |
| STJ mean diameter | 28.2±3.3 | 28.9±5.2 | 26.9±2.8 | 27.9±3.7 | 0.087 |
| Left sinus height | 20.4±3.7 | 19.8±3.1 | 19.7±2.4 | 20.0±3.2 | 0.497 |
| Right sinus height | 20.9±4.0 | 21.3±5.9 | 19.5±3.4 | 20.5±4.3 | 0.215 |
| Noncoronary sinus height | 20.7±3.4 | 21.6±4.4 | 19.4±2.8 | 20.4±3.5 | 0.042 |
| LCA height | 14.6±3.3 | 12.7±3.2 | 14.1±2.1 | 14±2.9 | 0.033 |
| RCA height | 15.6±3.6 | 15.7±5.3 | 14.8±3.2 | 15.4±3.8 | 0.518 |
| Intercommissural distance (left) | 30.4±3.6 | 31.2±5.5 | 28.1±2.7 | 29.8±4 | 0.004 |
| Intercommissural distance (right) | 29.4±3.2 | 30±5.3 | 27.3±2.7 | 28.8±3.7 | 0.007 |
| Intercommissural distance (noncoronary) | 30.9±3.3 | 31±6.1 | 28.8±2.9 | 30.2±4 | 0.027 |
| Procedural data | | | | | |
| Transfemoral access | 76 (55) | 100 (26) | 97 (38) | 87 (119) | 0.001 |
| THV size, mm | | | | | |
| 23 | 19 (26) | 6 (8) | 5 (7) | 30 (41) | |
| 25 | ... | ... | 17 (23) | 17 (23) | |
| 26 | 24 (33) | 3 (4) | ... | 27 (37) | |
| 27 | ... | ... | 7 (9) | 7 (9) | |
| 29 | 9 (13) | 3 (4) | ... | 12 (17) | |
| 34 | ... | 7 (10) | ... | 7 (10) | |
| Oversizing, % [†] | 15.6±13 | 33±14.5 | 26.8±12.8 | 23.2±18.2 | <0.001 |
| Postdilatation | 6 (4) | 37.5 (10) | 33 (13) | 20 (27) | <0.001 |
| Implantation depth [‡] | 3.5±0.8 | 4.9±1.7 | 4.3±0.9 | 4.0±1.2 | <0.001 |
| RP | 14.6±2.1 | 22.2±2.7 | 24.7±2.2 | 19.1±5.1 | <0.001 |
| VTA above RCA [§] | 1.4±0.9 | 2.3±2.9 | 2.2±1.4 | 2.1±2 | 0.097 |
| VTA above LCA [§] | 1.3±1.1 | 2.6±3.1 | 2.6±1.7 | 2.2±2.1 | 0.057 |
| RCA cannulation height | 16.9±1.9 | 17.5±3.2 | 19.1±4.8 | 17.7±3.4 | 0.004 |
| LCA cannulation height | 15.5±1.9 | 16.9±2.9 | 16.8±2.8 | 16.2±2.5 | 0.011 |

Data are shown as mean±SD or n (%). CABG indicates coronary artery bypass grafting; COPD, chronic obstructive pulmonary disease; CT, computed tomography; LCA, left coronary artery; LVEF, left ventricular ejection fraction; PCI, percutaneous coronary intervention; RCA, right coronary artery; RP, risk plane; STJ, sinotubular junction; THV, transcatheter heart valve; and VTA, valve-to-aorta distance.

[†]Oversizing (%)=[(nominal prosthesis area/cross-sectional annular area)-1]×100.

[‡]Mean value between left and noncoronary cusp.

[§]For patients with theoretically feasible or unfeasible coronary access.

device had higher aortic valve area (425 ± 84 versus 401 ± 117 and 395 ± 62 mm², respectively; $P=0.005$), whereas participants treated with an Evolut R/Pro had a slightly lower LCA origin (14.6 ± 3.3 versus 12.7 ± 3.2 and 14.1 ± 2.1 mm, respectively; $P=0.033$). Notably, sinotubular junction (STJ) diameter was similar (28.2 ± 3.3 versus 28.9 ± 5.2 and 26.9 ± 2.8 mm, respectively; $P=0.087$) among THV groups.

Procedural Characteristics and Outcomes

In 87% of patients, TAVR was performed through the transfemoral approach. Mean implantation depth was 3.5 ± 0.8 mm for Sapien 3/Ultra, 4.9 ± 1.7 mm for Evolut R/Pro, and 4.3 ± 0.9 mm for Acurate Neo THV ($P<0.001$). Postdilation was more often performed with Evolut R/Pro and Acurate Neo (37.5% and 33.3%, respectively) compared with Sapien 3 (6%; $P<0.001$). No complication related to coronary cannulation was registered. According to inclusion criteria, intraprocedural mortality was 0%, and no patient experienced annular rupture, device embolization, or moderate or severe paravalvular leakage. Of note, during the enrollment period, no patient at our institution experienced acute coronary obstruction after TAVR. Twelve patients (8.7%) underwent new pacemaker implantation before discharge.

Coronary Cannulation After TAVR

Cannulation of RCA and LCA was feasible in all patients (selective in 88.3%). The RP distance from the aortic valve, as measured by fluoroscopy, was significantly lower in patients who received a Sapien 3 compared with an Evolut R/Pro or Acurate Neo THV (mean, 14.6 ± 2.1 versus 22.2 ± 2.7 and 24.7 ± 2.2 mm, respectively; $P<0.001$). Left and right CCHs were also lower for Sapien 3/Ultra compared with other THVs ($P=0.001$ and $P=0.004$, respectively). In more than two-thirds of patients with an intra-annular device, coronary engagement was achieved from above the RP, whereas this proportion was significantly lower in patients treated with an Evolut R/Pro or Acurate Neo (68.1% versus 19.2% and 5.1%, respectively; $P<0.001$). Among patients with coronary cannulation under the RP, mean VTA was 2.2 ± 2.1 mm for LCA and 2.1 ± 0.9 mm for RCA, with no difference between THV groups. Twelve participants (8.7%) also underwent computed tomography evaluation after TAVR (Figure S2). Visual inspection of Bland-Altman plots showed good agreement between computed tomography and angiography measurements of VTA and RP in this small subgroup of patients (Table S2).

Feasibility of CA After TAVR

According to our classification algorithm, CA after TAVR-in-TAVR was deemed unfeasible in 31.4% of our TAVR population (Figure 3). This unfavorable

situation tended to be more frequent among patients with Evolut R/Pro or Acurate Neo (38.5% and 41.1%, respectively) compared with Sapien 3 (23.6%; $P=0.116$). On the contrary, TAVR-in-TAVR was found to be more frequently feasible in patients with an intra-annular THV (68.1% versus 19.2% and 5.1%, respectively; $P<0.001$). In about 27.7% of patients, TAVR-in-TAVR was considered theoretically feasible, given the presence of a VTA >2 mm and CA achieved from below the RP. Notably, all feasible and theoretically feasible TAVR-in-TAVR procedures based on LCA cannulation were confirmed after assessment of RCA measurements. Compared with the rest of the study population, participants with predicted impaired CA after TAVR-in-TAVR had smaller annulus, narrower STJ, and lower sinuses. Notably, LCA and RCA ostium heights were not different among groups. Regarding procedural characteristics, patients with unfeasible TAVR-in-TAVR had higher rates of postdilation, lower RP, and lower CCH (Table 2).

Predictors of CA Unfeasibility After TAVR-in-TAVR

Multiple potential predictors were tested (sex, mean aortic gradient at echocardiography, coronary ostium and coronary sinus height, sinus and STJ diameter, annular and left ventricular outflow tract (LVOT) area, perimeter and diameter, prosthesis size and oversizing, supra-annular design, CCH). At multivariate analysis, female sex (OR, 3.99; 95% CI, 1.07–14.86; $P=0.040$), STJ diameter (OR, 0.62; 95% CI, 0.48–0.80; $P<0.001$), and implantation of supra-annular THV (OR, 6.61; 95% CI, 1.93–22.03; $P=0.002$) and left CCH (OR, 0.52; 95% CI, 0.37–0.74; $P<0.001$) were found to be independent predictors of impaired CA after TAVR-in-TAVR (C-statistic, 0.89; Hosmer and Lemeshow test, 0.6; Table 3).

DISCUSSION

The main findings of this study—the first to investigate potential unfeasibility of CA after TAVR-in-TAVR—are as follows. First, according to our novel coronary angiography-based algorithm, almost one-third of TAVR patients might be unsuitable for TAVR-in-TAVR. Second, patients treated with an intra-annular Sapien 3/Ultra THV are at lower risk of CA impairment after TAVR-in-TAVR compared with participants who received a supra-annular Evolut R/Pro and Acurate Neo. Third, female sex, presence of a small STJ, and implantation of a supra-annular device are independent predictors of possible impaired CA after TAVR-in-TAVR.

Given the positive results of recent low-risk trials,^{1,2} TAVR is being increasingly offered to younger patients

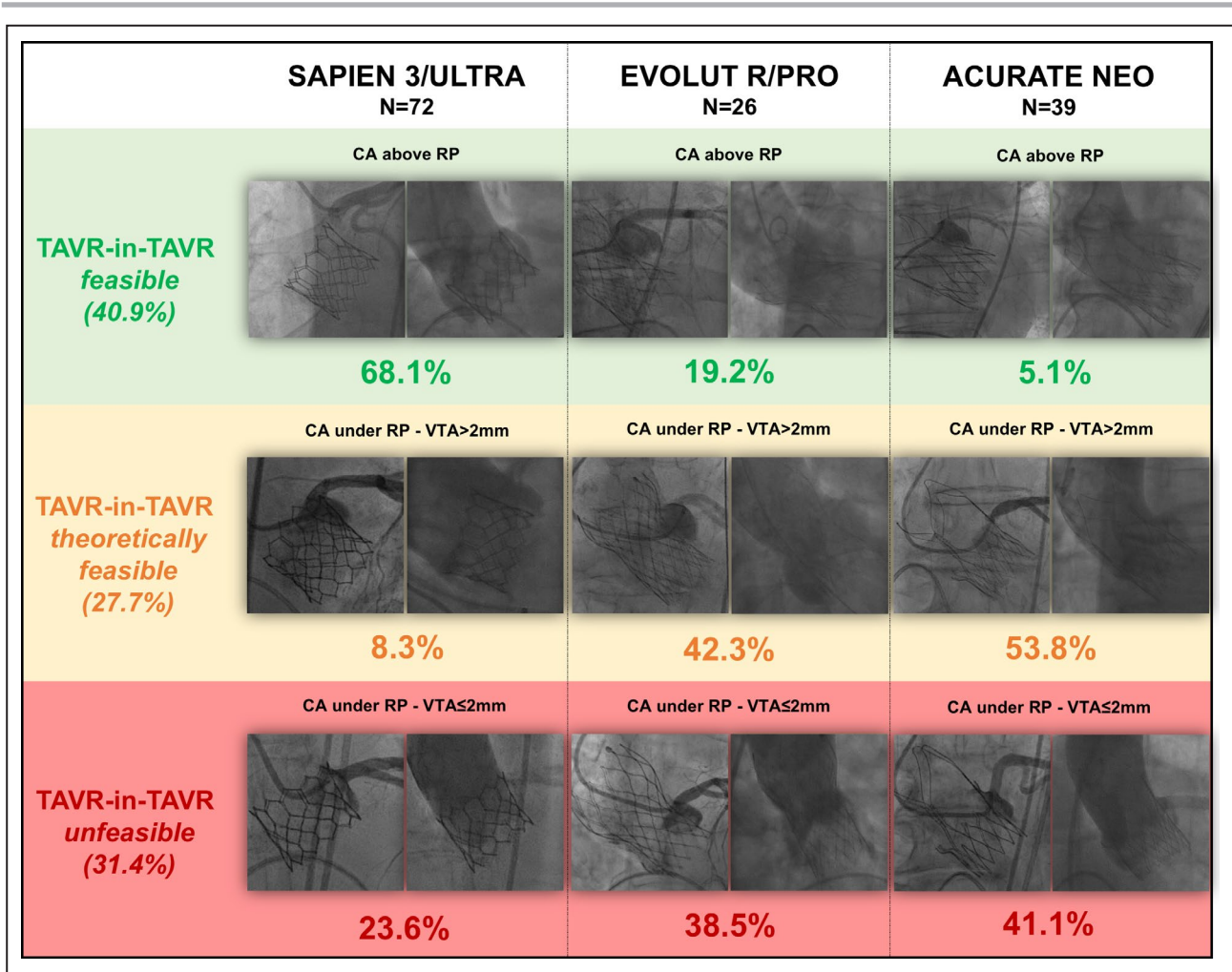


Figure 3. Incidence of predicted coronary access (CA) impairment after transcatheter aortic valve replacement (TAVR)-in-TAVR according to transcatheter heart valve (THV) type. RP indicates risk plane; and VTA, valve-to-aorta distance.

with the approach of undergoing redo TAVR if they outlive their THVs. However, data on TAVR-in-TAVR are restricted to single-case reports.¹⁴ Possible high risk of coronary obstruction and impossibility of reaccessing the coronary ostia after the leaflets of the first THV are displaced vertically by the implantation of the second device have been suggested.⁶ Notably, this risk is independent from the commissural alignment of the THV (eg, with or without a commissural tab facing the coronary ostium), because the tilted leaflet of the first device will create a cylindrical cage with the implantation of the second THV. To date, feasibility of CA after TAVR with different THVs has never been comprehensively addressed.

Feasibility of TAVR-in-TAVR

Our results, although theoretical and hypothesis generating, suggest that in 1 of every 3 participants, redo TAVR might cause impairment in CA. In this situation,

patients might experience the paradox of needing surgical aortic valve replacement after being treated with TAVR. A recent study based on aortic angiogram suggested that 21.3% of patients treated with Sapien 3 might be unsuitable for TAVR-in-TAVR.⁷ Interestingly, our data confirm these findings, with 23.6% of intra-annular devices at high risk of CA impairment after TAVR-in-TAVR based on the proposed algorithm. In the same report, Tang et al suggested a novel aortic root classification that is useful but not applicable to supra-annular prostheses.

Procedural Predictors of TAVR-in-TAVR Unfeasibility

TAVR-in-TAVR with intra-annular Sapien 3/Ultra will not interfere with future CA in more than two-thirds of patients, whereas this percentage is considerably lower (<20%) in patients with supra-annular devices. These results can be explained by the lower frame of

Table 2. Baseline Characteristics and Procedural Data by CA Feasibility

| Clinical Characteristics | Feasible (n=56) | Theoretically Feasible (n=38) | Unfeasible (n=43) | Total (N=137) | P Value |
|--|-----------------|-------------------------------|-------------------|---------------|---------|
| Age, y | 78.6±7.6 | 80.4±5.0 | 78.6±7.8 | 79.1±7.0 | 0.424 |
| Female | 41 (23) | 42 (16) | 63 (27) | 48 (66) | 0.068 |
| Euroscore II | 4.4±3.8 | 3.4±1.6 | 4.3±2.7 | 4.1±3.0 | 0.276 |
| Hypertension | 89 (50) | 89.5 (34) | 81 (35) | 87 (119) | 0.435 |
| Dyslipidemia | 61 (34) | 76 (29) | 79 (34) | 71 (97) | 0.129 |
| Diabetes mellitus | 34 (19) | 34 (13) | 23 (10) | 31 (42) | 0.560 |
| COPD | 21 (12) | 18 (7) | 19 (8) | 20 (27) | 0.897 |
| Coronary artery disease | 59 (33) | 66 (25) | 58 (25) | 60.5 (83) | 0.822 |
| Previous PCI | 25 (14) | 30 (11) | 39.5 (17) | 31 (42) | 0.343 |
| Previous CABG | 10 (6) | 10.5 (4) | 14 (6) | 12 (16) | 0.773 |
| Previous stroke | 12 (7) | 8 (3) | 14 (6) | 12 (16) | 0.746 |
| Atrial fibrillation | 36 (20) | 21 (8) | 14 (6) | 25 (34) | 0.073 |
| Prior pacemaker | 9 (5) | 10.5 (4) | 2 (1) | 7 (10) | 0.334 |
| LVEF (%) | 54.7±11.5 | 56.0±10.7 | 56.5±12.8 | 55.6±11.6 | 0.758 |
| CT baseline | | | | | |
| Annulus area | 448±75 | 426±77 | 390±91 | 425±84 | 0.013 |
| Annulus perimeter | 76.9±7.2 | 76.9±9.5 | 72.0±8.4 | 75.4±8.4 | 0.021 |
| STJ mean diameter | 28.7±3.2 | 29.4±4.1 | 25.5±2.3 | 27.9±3.7 | <0.001 |
| Left sinus height | 20.8±3.4 | 20.5±2.9 | 18.8±2.9 | 20.0±3.2 | 0.009 |
| Right sinus height | 21.3±3.8 | 21.3±4.6 | 18.9±4.0 | 20.5±4.3 | 0.020 |
| Noncoronary sinus height | 21.3±3.2 | 20.8±3.7 | 19.1±3.3 | 20.4±3.5 | 0.016 |
| LCA height | 14.73±3.1 | 13.9±2.5 | 13.3±3.0 | 14.0±2.9 | 0.080 |
| RCA height | 15.5±3.6 | 15.7±4.4 | 14.8±3.6 | 15.4±3.8 | 0.539 |
| Intercommisural distance (left) | 30.6±3.7 | 30.2±4.8 | 28.5±3.1 | 29.8±4 | 0.049 |
| Intercommisural distance (right) | 29.6±3.1 | 29.5±4.7 | 27.2±2.9 | 28.8±3.7 | 0.005 |
| Intercommisural distance (noncoronary) | 30.8±3.3 | 31±4.5 | 28.7±4.1 | 30.2±4 | 0.025 |
| Procedural data | | | | | |
| Transfemoral access | 77 (43) | 92 (35) | 95 (41) | 87 (119) | 0.013 |
| THV size, mm | | | | | |
| 23 | 13 (18) | 4 (6) | 12 (17) | 30 (41) | |
| 25 | ... | 9 (13) | 7 (10) | 17 (23) | |
| 26 | 19 (26) | 4 (5) | 4 (6) | 27 (37) | |
| 27 | 1 (2) | 3 (4) | 2 (3) | 7 (9) | |
| 29 | 5 (7) | 4 (5) | 4 (5) | 12 (17) | |
| 34 | 2 (3) | 4 (5) | 1 (2) | 7 (10) | |
| Oversizing, % [†] | 15.8±15.4 | 27.9±18.7 | 29.9±18.1 | 23.2±18.2 | 0.001 |
| Supra-annular THV | 11 (6) | 84 (32) | 60.5 (26) | 47 (64) | <0.001 |
| Postdilatation | 9 (5) | 29 (11) | 25.5 (11) | 20 (27) | 0.029 |
| Implantation depth [‡] | 3.9±1.3 | 4.2±0.9 | 4.0±1.3 | 4.0±1.2 | 0.357 |
| RP | 15.4±3.6 | 23.3±3.7 | 20.2±4.6 | 19.1±5.1 | <0.001 |
| RCA VTA [§] | ... | 3.6±0.8 | 0.8±0.7 | 2.1±0.9 | <0.001 |
| LCA VTA [§] | ... | 3.8±2.2 | 0.9±0.6 | 2.2±2.1 | <0.001 |
| RCA cannulation height | 17.9±2.6 | 19.5±4.3 | 15.9±2.3 | 17.7±3.4 | <0.001 |
| LCA cannulation height | 17.0±2.9 | 16.6±2.0 | 14.8±1.7 | 16.2±2.5 | <0.001 |

Data are shown as mean±SD or n (%). CA indicates coronary access; CABG, coronary artery bypass grafting; COPD, chronic obstructive pulmonary artery disease; CT, computed tomography; LCA, left coronary artery; LVEF, left ventricular ejection fraction; PCI, percutaneous coronary intervention; RCA, right coronary artery; RP, risk plane; STJ, sinotubular junction; THV, transcatheter heart valve; and VTA, valve-to-aorta distance.

[†]Oversizing (%)=[(nominal prosthesis area/cross-sectional annular area)-1]×100.

[‡]Mean value between left and noncoronary cusp.

[§]For patients with theoretically feasible or unfeasible CA.

Table 3. Multivariate Analysis of CA Impairment After TAVR-in-TAVR

| Predictor Variable | Predictor Variable in Unfeasible vs Feasible | OR (95% CI) | P Value | C-Statistic | H-L Test |
|---|--|-------------------|---------|-------------|----------|
| Female sex, % | 41 vs 22.5 | 3.99 (1.07–14.86) | 0.040 | 0.89 | 0.6 |
| Supra-annular design, % | 41 vs 23 | 6.61 (1.98–22.03) | 0.002 | | |
| STJ diameter, mean±SD | 25.5±2.3 vs 29±3.6 | 0.62 (0.48–0.80) | <0.001 | | |
| Left coronary cannulation height, mean±SD | 14.8±1.7 vs 16.8±2.6 | 0.52 (0.37–0.74) | <0.001 | | |

CA indicates coronary access; H-L test, Hosmer–Lemeshow test; OR, odds ratio; STJ, sinotubular junction; and TAVR, transcatheter aortic valve replacement.

intra-annular THVs, which have a design more similar to surgical bioprostheses. On the contrary, supra-annular THVs invariably extend above the coronary ostia, and coronary cannulation after index TAVR is achieved under the RP with 80.8% of Evolut R/Pro and 94.9% of Acurate Neo devices. Nevertheless, in a consistent proportion of patients with a large STJ (VTA >2 mm), redo TAVR is theoretically feasible, given the possibility for a coronary catheter to navigate between the valve frame and the aortic wall after the leaflets have been vertically displaced (Video S1). However, CA in this situation will be challenging, and operators will likely need differently shaped catheters or even the help of coronary guidewires or microcatheters to achieve coronary cannulation. Moreover, because CA in the theoretically feasible group in our study was achieved from below the RP, we cannot exclude that CA will eventually be unfeasible in some of these patients. This outcome might be more likely if the coronary ostia are low or if TAVR-in-TAVR is performed with 2 Evolut R/Pro THVs. In fact, given the impossibility of orienting the THV,¹⁵ it is possible that the 2 frames above the RP would not perfectly align, leaving insufficient room for a coronary catheter to cross the 2 overlapping stent layers. This issue might be mitigated by the open cell design of the Acurate Neo THV. If a supra-annular valve were implanted first and then TAVR-in-TAVR were performed with a Sapien 3/Ultra THV, the leaflet of the original valve might not be displaced in a completely vertical position, making CA potentially easier as long as a commissural post does not lie in front of the coronary ostium. Notably, novel leaflet-splitting techniques such as BASILICA may be less effective in preventing coronary obstruction with TAVR-in-TAVR compared with TAVR in surgical aortic valves, since the neocommissure of the first prosthesis might not be aligned to those of the native aortic valve and potentially lying in front of a coronary ostium.

In our study, a mean implantation depth of 4.0±1.2 mm resulted in a pacemaker implantation rate of 8.7%, comparable to other recent TAVR series.^{1,2} It could be speculated that a strategy of lower THV implantation would increase feasibility of CA after redo TAVR by lowering the RP. However, this would likely happen at the cost of higher rates of pacemaker implantation^{16–18}—an undesirable complication, particularly in younger patients.^{19,20}

Anatomic Predictors of TAVR-in-TAVR Unfeasibility

The major anatomic predictor of potential TAVR-in-TAVR unfeasibility is the presence of a narrow STJ. As the tightest part of the aortic root, the STJ is often the level at which the prosthesis frame is in closest proximity to the aortic wall and represents the bottleneck where the catheter is not able to further navigate toward the coronary ostium. In contrast, coronary sinus and coronary ostium height do not seem to predict CA impairment after TAVR-in-TAVR, possibly because the RP of correctly implanted supra-annular devices is almost always above the coronary sinuses, even in the presence of a very high STJ. Notably, the smaller mean STJ of patients receiving the Acurate Neo valve might have reduced the percentage of theoretically feasible CA with this valve in our cohort.

The results of this study should be considered hypothesis generating, and the proposed algorithm needs to be validated in clinical practice by collecting redo TAVR procedures performed in nonselected cohorts of patients. However, based on these findings, patients with longer life expectancy might be considered for implantation of a lower frame, intra-annular THV to preserve CA in case TAVR-in-TAVR is needed in the future. Recognition of anatomic features potentially impairing CA after redo TAVR, such as a narrow STJ, is important for correct counseling in younger patients proposed for TAVR. Choosing the first THV while considering future TAVR-in-TAVR highlights how far we have progressed in the field of transcatheter treatment of aortic stenosis. Particularly when small valves are required in younger patients, the potential advantages of better hemodynamics and lower patient-prosthesis mismatch rates with a supra-annular design need to be balanced with the risk of CA unfeasibility after TAVR-in-TAVR.

Limitations

The main limitation of the current study is the lack of routine computed tomography evaluation after the index TAVR. In fact, although coronary angiography and aortography were acquired in dedicated optimized fluoroscopic views to minimize valve frame parallax,

VTA could have been underestimated.⁷ However, in the small subgroup of patients who underwent computed tomography after TAVR, the 2 measurements showed good agreement. Nevertheless, validation of our findings with routine integration of coronary angiography and 3-dimensional computed tomography reconstruction needs to be the focus of further research. Moreover, we cannot exclude that in some cases with VTA >2 mm but coronary cannulation from below the RP (ie, theoretically feasible TAVR-in-TAVR), CA could have been achieved from above the RP with the use of differently shaped coronary catheters or the help of a guidewire or microcatheter. Notably, angiography and percutaneous coronary intervention are often feasible (but more challenging) even when selective cannulation is not possible. At the same time, we cannot exclude that in some of these patients, CA might eventually be unfeasible, even if VTA is >2 mm. The greater percentage of small aortic annuli among patients who received the Acurate Neo valve may represent a potential confounder, although small valvular annular dimensions were not independent predictors of TAVR-in-TAVR unfeasibility. In this regard, it is known that supra-annular devices are preferred in small aortic anatomies because of their better hemodynamic performance,²¹ thus our data reflect real-world clinical practice. Our results should not be extended to other devices, such as intra-annular Portico (Abbott) and Lotus (Boston Scientific) THVs,²² which were not investigated. Moreover, they should not be generalized to patients with bicuspid aortic valve stenosis, for which THV implantation is usually higher.^{12,23} Finally, this study was conducted in a single high-volume TAVR center without core-laboratory validation of angiographic findings.

CONCLUSIONS

CA after TAVR-in-TAVR might be unfeasible in approximately a third of patients currently treated by TAVR. Participants who received a supra-annular THV were at higher risk of CA impairment compared with those implanted with an intra-annular device. Female sex and small STJ dimensions are also independent predictors of impaired CA after TAVR-in-TAVR. Our findings are important for correct patient counseling and prosthesis selection in patients with longer life expectancy. These results have to be considered hypothesis generating and need to be confirmed by larger studies with routine integration of computed tomography evaluation and, most importantly, by collection of a larger number of redo TAVR procedures in nonselected patients.

ARTICLE INFORMATION

Received March 3, 2020; accepted April 28, 2020.

Affiliations

From the Department of Cardiac, Thoracic, Vascular Sciences and Public Health, University of Padua Medical School, Padua, Italy.

Sources of Funding

None. This study was endorsed by the Italian Society of Interventional Cardiology (GISE).

Disclosures

Tarantini reports honoraria for lectures/consulting from Medtronic, Edwards Lifesciences, Boston Scientific, GADA, Abbott. The remaining authors have no disclosures to report.

Supplementary Materials

Tables S1–S2

Figures S1–S2

Video S1

REFERENCES

- Mack MJ, Leon MB, Thourani VH, Makkar R, Kodali SK, Russo M, Kapadia SR, Malaisrie SC, Cohen DJ, Pibarot P, et al. Transcatheter aortic-valve replacement with a balloon-expandable valve in low-risk patients. *N Engl J Med*. 2019;18:1695–1705.
- Popma JJ, Deeb GM, Yakubov SJ, Mumtaz M, Gada H, O'Hair D, Bajwa T, Heiser JC, Merhi W, Kleiman NS, et al. Transcatheter aortic-valve replacement with a self-expanding valve in low-risk patients. *N Engl J Med*. 2019;18:1706–1715.
- Ueshima D, Fovino LN, D'Amico G, Brener SJ, Esposito G, Tarantini G. Transcatheter versus surgical aortic valve replacement in low- and intermediate-risk patients: an updated systematic review and meta-analysis. *Cardiovasc Interv Ther*. 2019;34:216–225.
- Tarantini G, Nai Fovino L, D'Errigo P, Rosato S, Barbanti M, Tamburino C, Ranucci M, Santoro G, Badoni G, Seccareccia F; OBSERVANT Research Group. Factors influencing the choice between transcatheter and surgical treatment of severe aortic stenosis in patients younger than 80 years: results from the OBSERVANT study. *Catheter Cardiovasc Interv*. 2019;34:216–225.
- Tarantini G, Nai Fovino L, Gersh BJ. Transcatheter aortic valve implantation in lower-risk patients: what is the perspective? *Eur Heart J*. 2018;39:658–666.
- Buzzatti N, Romano V, De Backer O, Soendergaard L, Rosseel L, Maurovich-Horvat P, Karady J, Merkely B, Ruggeri S, Prendergast B, et al. Coronary access after repeated transcatheter aortic valve implantation: a glimpse into the future. *JACC Cardiovasc Imaging*. 2019;13:508–515.
- Tang GHL, Zaid S, Gupta E, Ahmad H, Khan A, Kovacic JC, Lansman SL, Dangas GD, Sharma SK, Kini A. Feasibility of repeat TAVR after SAPIEN 3 TAVR: a novel classification scheme and pilot angiographic study. *JACC Cardiovasc Interv*. 2019;12:1290–1292.
- Nai Fovino L, Scotti A, Massussi M, Fabris T, Cardaioli F, Rodinò G, Matsuda Y, Frigo F, Fraccaro C, Tarantini G. Incidence and feasibility of coronary access after transcatheter aortic valve replacement. *Catheter Cardiovasc Interv*. 2020; [Epub ahead of print]
- Tarantini G, Fabris T, Nai Fovino L. TAVR-in-TAVR and coronary access: the importance of pre-procedural planning. *EuroIntervention*. 2020; EJ-D-19-01094.
- Kappetein AP, Head SJ, Généreux P, Piazza N, van Mieghem NM, Blackstone EH, Brott TG, Cohen DJ, Cutlip DE, van Es GA, et al. Updated standardized endpoint definitions for transcatheter aortic valve implantation: the Valve Academic Research Consortium-2 consensus document. *J Am Coll Cardiol*. 2012;60:1438–1454.
- Yudi MB, Sharma SK, Tang GHL, Kini A. Coronary angiography and percutaneous coronary intervention after transcatheter aortic valve replacement. *J Am Coll Cardiol*. 2018;71:1360–1378.
- Tarantini G, Fabris T, Cardaioli F, Nai Fovino L. Coronary access after transcatheter aortic valve replacement in patients with bicuspid aortic valve: lights and shades. *JACC Cardiovasc Interv*. 2019;12:1190–1191.
- Harrell FE, Lee KL, Mark DB. Multivariable prognostic models: issues in developing models, evaluating assumptions and adequacy, and measuring and reducing errors. *Stat Med*. 1996;15:361–387.

14. Murdoch DJ, Webb JG, Ye J, Sathanathan J, Hensey M, Wood DA, Cheung A, Leipsic J, Blanke P, Lauck S. Transcatheter aortic-valve replacement—10 years later. *N Engl J Med*. 2019;380:1773–1774.
15. Tang GHL, Zaid S, Gupta E, Ahmad H, Patel N, Khan M, Khan A, Kovacic JC, Lansman SL, Dangas GD, et al. Impact of initial evolut transcatheter aortic valve replacement deployment orientation on final valve orientation and coronary reaccess. *Circ Cardiovasc Interv*. 2019;12:e008044.
16. Jilaihawi H, Zhao Z, Du R, Staniloae C, Saric M, Neuburger PJ, Querijero M, Vainrib A, Hisamoto K, Ibrahim H, et al. Minimizing permanent pacemaker following repositionable self-expanding transcatheter aortic valve replacement. *JACC Cardiovasc Interv*. 2019;12:1796–1807.
17. Tarantini G, Mojoli M, Purita P, Napodano M, D'Onofrio A, Frigo A, Covolo E, Facchin M, Isabella G, Gerosa G, et al. Unravelling the (arte) fact of increased pacemaker rate with the Edwards SAPIEN 3 valve. *EuroIntervention*. 2015;11:343–350.
18. Fovino LN, Saladini G, Mormino GP, Saladini F, Razzolini R, Evangelista L. Risk stratification and prognostic assessment by myocardial perfusion-gated SPECT in patients with left bundle-branch block and low-intermediate cardiac risk. *Ann Nucl Med*. 2012;26:559–570.
19. Ueshima D, Nai Fovino L, Mojoli M, Napodano M, Fraccaro C, Tarantini G. The interplay between permanent pacemaker implantation and mortality in patients treated by transcatheter aortic valve implantation: a systematic review and meta-analysis. *Catheter Cardiovasc Interv*. 2018;92:E159–E167.
20. Nadeem F, Tsushima T, Ladas TP, Thomas RB, Patel SM, Saric P, Patel T, Lipinski J, Li J, Costa MA, et al. Impact of right ventricular pacing in patients who underwent implantation of permanent pacemaker after transcatheter aortic valve implantation. *Am J Cardiol*. 2018;122:1712–1717.
21. Regazzoli D, Chiarito M, Cannata F, Pagnesi M, Miura M, Ziviello F, Picci A, Reifart J, De Marco F, Bedogni F, et al. Transcatheter self-expandable valve implantation for aortic stenosis in small aortic annuli: the TAVI-SMALL Registry. *JACC Cardiovasc Interv*. 2020;13:196–206.
22. Nai Fovino L, Badawy MRA, Fraccaro C, D'Onofrio A, Purita PAM, Frigo AC, Tellaroli P, Mauro A, Tusa M, Napodano M, et al. Transfemoral aortic valve implantation with new-generation devices: the repositionable Lotus vs. the balloon-expandable Edwards Sapien 3 valve. *J Cardiovasc Med (Hagerstown)*. 2018;19:655–663.
23. Ueshima D, Nai Fovino L, Brener SJ, Fabris T, Scotti A, Barioli A, Giacoppo D, Pavei A, Fraccaro C, Napodano M, et al. Transcatheter aortic valve replacement for bicuspid aortic valve stenosis with first- and new-generation bioprostheses: a systematic review and meta-analysis. *Int J Cardiol*. 2019;298:76–82.

SUPPLEMENTAL MATERIAL

Table S1. Baseline characteristics and procedural data per CA feasibility.

| <i>Clinical Characteristics</i> | Feasible or Theoretically Feasible (94) | Unfeasible (43) | Total (137) | <i>p-value</i> |
|---|--|------------------------|--------------------|------------------|
| Age (years) | 79.3±6.7 | 78.6±7.8 | 79.1±7.0 | 0.563 |
| Female | 41.5% (39) | 63% (27) | 48% (66) | 0.021 |
| Euroscore II | 4.0±3.2 | 4.3±2.7 | 4.1±3.0 | 0.549 |
| Hypertension | 89% (84) | 81% (35) | 87% (119) | 0.198 |
| Dyslipidemia | 67% (63) | 79% (34) | 71% (97) | 0.174 |
| Diabetes Mellitus | 34% (32) | 23% (10) | 31% (42) | 0.283 |
| COPD | 20% (19) | 19% (8) | 20% (27) | 0.952 |
| Coronary artery disease | 62% (58) | 58% (25) | 60.5% (83) | 0.697 |
| Previous PCI | 27% (25) | 39.5% (17) | 31% (42) | 0.166 |
| Previous CABG | 11% (10) | 14% (6) | 12% (16) | 0.496 |
| Previous Stroke | 11% (10) | 14% (6) | 12% (16) | 0.525 |
| Atrial Fibrillation | 30% (28) | 14% (6) | 25% (34) | 0.078 |
| Prior pacemaker | 9.5% (9) | 2% (1) | 7% (10) | 0.172 |
| LV-EF (%) | 55.7±11.5 | 56.5±12.8 | 55.6±11.6 | 0.583 |
| <i>CT baseline</i> | | | | |
| Annulus Area | 440±76 | 390±91 | 425±84 | 0.006 |
| Annulus perimeter | 76.9±8.1 | 72.0±8.4 | 75.4±8.4 | 0.005 |
| STJ mean diameter | 28.9±3.6 | 25.5±2.3 | 27.9±3.7 | <0.001 |
| Left sinus height | 20.7±3.2 | 18.8±2.9 | 20.0±3.2 | 0.002 |
| Right sinus height | 21.3±4.2 | 18.9±4.0 | 20.5±4.3 | 0.005 |
| Non coronary sinus height | 21.1±3.4 | 19.1±3.3 | 20.4±3.5 | 0.005 |
| LCA height | 14.4±2.9 | 13.3±3.0 | 14.0±2.9 | 0.055 |
| RCA height | 15.6±3.9 | 14.8±3.6 | 15.4±3.8 | 0.268 |
| Intercommisural distance (left) | 30.4±4.2 | 28.5±3.1 | 29.8±4 | 0.016 |
| Intercommisural distance (right) | 29.6±3.8 | 27.2±2.9 | 28.8±3.7 | 0.001 |
| Intercommisural distance (non coronary) | 30.9±3.8 | 28.7±4.1 | 30.2±4 | 0.007 |
| <i>Procedural Data</i> | | | | |
| Transfemoral access | 83% (78) | 95% (41) | 87% (119) | 0.047 |
| THV size | | | | |
| 23 mm | 18% (24) | 12% (17) | 30% (41) | |
| 25 mm | 10% (13) | 7% (10) | 17% (23) | |
| 26 mm | 23% (31) | 4% (6) | 27% (37) | |
| 27 mm | 4% (6) | 2% (3) | 7% (9) | |
| 29 mm | 9% (12) | 4% (5) | 12% (17) | |
| 34 mm | 6% (8) | 1% (2) | 7% (10) | |
| Oversizing (%) ° | 20.4±17.7 | 29.9±18.1 | 23.2±18.2 | 0.015 |
| Supra-annular THV | 40% (38) | 60.5% (26) | 47% (64) | 0.029 |

| | | | | |
|---------------------------------|----------|------------|----------|------------------|
| Post-dilatation | 17% (16) | 25.5% (11) | 20% (27) | 0.332 |
| Implantation depth [†] | 4.0±1.2 | 4.0±1.3 | 4.0±1.2 | 0.931 |
| Risk Plane | 18.5±5.3 | 20.2±4.6 | 19.1±5.1 | <0.001 |
| RCA VTA* | 3.6±0.8 | 0.8±0.7 | 2.1±0.9 | <0.001 |
| LCA VTA* | 3.8±2.2 | 0.9±0.6 | 2.2±2.1 | <0.001 |
| RCA cannulation height | 18.6±3.5 | 15.9±2.3 | 17.7±3.4 | <0.001 |
| LCA cannulation height | 16.8±2.6 | 14.8±1.7 | 16.2±2.5 | <0.001 |

[†] mean value between left and noncoronary cusp; * for patients with theoretically feasible or unfeasible CA

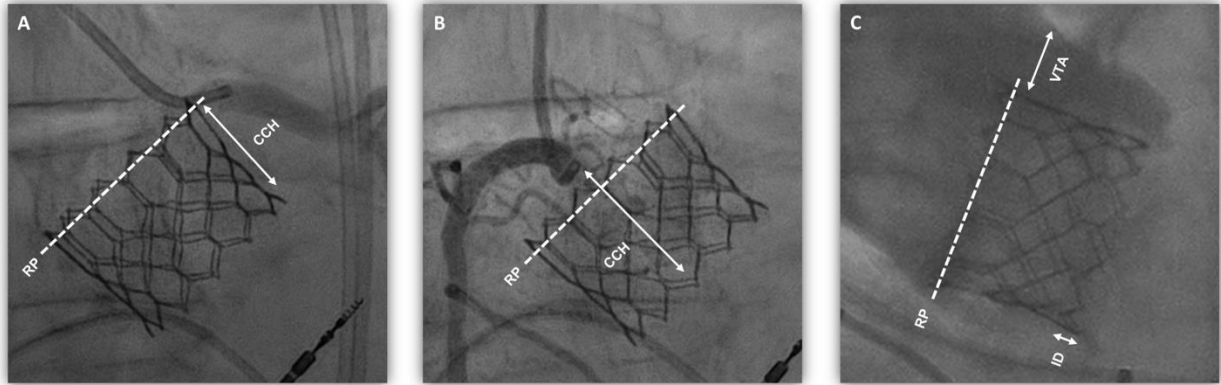
[°] Oversizing (%) = [(nominal prosthesis area/cross-sectional annular area) – 1] x 100

COPD = chronic obstructive pulmonary artery disease; PCI = percutaneous coronary intervention; CABG = coronary artery bypass grafting; LV-EF = left ventricular ejection fraction; CT= computed tomography; STJ = sinotubular junction; LCA = left coronary artery; RCA = right coronary artery; THV = transcatheter heart valve; VTA = valve-to-aorta distance

Table S2. Computed tomography and angiographic measurement of VTA and RP in patients undergoing CT after TAVR.

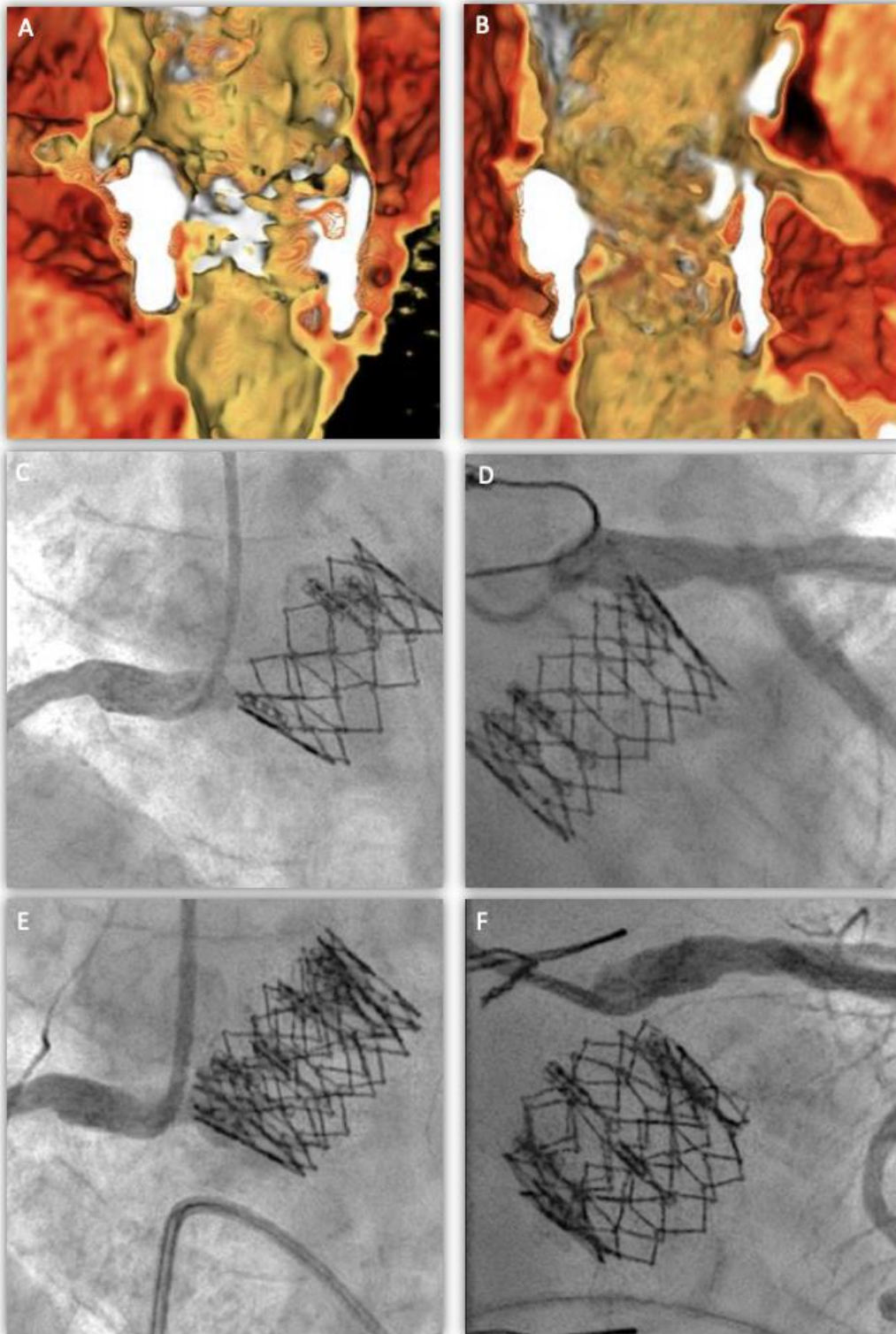| Patient | Risk plane (mm) | | VTA above RCA (mm) | | VTA above LCA (mm) | |
|-----------|-----------------|--------------------|--------------------|--------------------|--------------------|--------------------|
| | <i>CT</i> | <i>Angiography</i> | <i>CT</i> | <i>Angiography</i> | <i>CT</i> | <i>Angiography</i> |
| 1 | 14.3 | 14.5 | 3.2 | 2.9 | 2.8 | 3.1 |
| 2 | 15.5 | 15.6 | 1.3 | 1.4 | 1.5 | 1.3 |
| 3 | 13.6 | 13.9 | 0.7 | 1.0 | 1.3 | 0.9 |
| 4 | 12.9 | 12.7 | 2.9 | 3.3 | 3.1 | 2.8 |
| 5 | 19.0 | 18.6 | 2.7 | 2.6 | 2.5 | 2.4 |
| 6 | 19.2 | 19.5 | 4.7 | 5.3 | 4.5 | 4.8 |
| 7 | 21.1 | 22.4 | 1.9 | 1.4 | 1.8 | 1.6 |
| 8 | 22.3 | 22.9 | 1.4 | 1.7 | 0.7 | 1.1 |
| 9 | 20.6 | 20.5 | 3.3 | 2.8 | 3.9 | 3.6 |
| 10 | 25.9 | 26.4 | 2.0 | 2.2 | 1.2 | 1.0 |
| 11 | 23.9 | 25.7 | 3.0 | 3.1 | 2.9 | 2.8 |
| 12 | 20.4 | 22.1 | 1.1 | 1.1 | 0.4 | 0.7 |

Figure S1. Dedicated angiographic views for LCA, RCA and aortogram measurements, optimized to eliminate valve frame parallax.



For example, LCA angiograms were acquired with the coronary take-off perpendicular to the operator (e.g. with the left main on the right side in LAO view). Similar views were obtained for all types of THV. LCA=left coronary artery; RCA=right coronary artery; CCH=coronary cannulation height; RP=risk plane; VTA=valve-to-aorta distance; ID=implantation depth.

Figure S2. Computed tomography and coronary angiography of a patient with predicted feasible coronary access after TAVR-in-TAVR.



According to pre-procedural CT the coronary ostia are located above the risk plane of the balloon-expandable prosthesis (A-B). Coronary cannulation is achieved from above the risk plane (C-D). After TAVR-in-TAVR with a second balloon-expandable prosthesis, coronary cannulation is still easily achieved from above the risk plane (E-F).

Supplemental Video Legend:

Video S1. Left coronary artery cannulation from outside the valve frame in a patient with

VTA >2 mm after Acurate Neo implantation. Best viewed with Windows Media Player.