

Case Reports & Case Series

Real-time neuropsychological testing during endovascular occlusion of a fusiform aneurysm in the left middle cerebral artery[☆]Barbara Tomasino^{a,*}, Tamara Ius^b, Benedetto Petralia^c, Vladimir Gavrilovic^c, Miran Skrap^b^a Scientific Institute, IRCCS E. Medea, San Vito al Tagliamento, Pordenone, Italy^b Unità Operativa di Neurochirurgia, Azienda Sanitaria Universitaria Integrata S. Maria della Misericordia, Udine, Italy^c Unità Operativa di Neuroradiologia, Azienda Sanitaria Universitaria Integrata S. Maria della Misericordia, Udine, Italy

ARTICLE INFO

Keywords:

Temporary occlusion testing
 Aneurysm treatment outcome
 Functional recovery
 Inferior frontal gyrus
 fMRI
 Plasticity
 Speech articulation

ABSTRACT

Real-time neuropsychological testing (RTNT) was used to test whether permanent endovascular occlusion of the insular branch of the left middle cerebral artery (MCA) helped avoid cognitive and neurological complications following the procedure. This patient suffered from a fusiform aneurysm along the insular branch of the MCA in the territory supplied in the left inferior frontal gyrus, around Broca's area. Pre-intervention neuropsychological testing was normal.

During *temporary* occlusion lasting 25 min, the patient continuously performed at ceiling on the RTNT neuropsychological and language tasks. Thus, *permanent* occlusion followed. In addition, fMRI was used to investigate changes induced by the procedure. In the language domain, rearrangements in activation in Broca's area and in the left insula were detected by silent and overt production tasks. In the motor domain, decreased activation in the sensorimotor cortex during right-hand movement control was reported along with decreased right-hand sensibility. Post-intervention neuropsychological testing was normal.

Results showed that RTNT can be used reliably during temporary occlusion in the specific case of a quite small branch of the MCA to provide continuous feedback on the patient's cognitive and language status and is predictive of post-intervention functioning. In addition, the study enabled us to detect changes in functional organization triggered by temporary occlusion of a branch of the left middle cerebral artery.

1. Introduction

It is held that 40% of intracerebral aneurysms involve the middle cerebral artery (MCA). This artery supplies a portion of the frontal lobe and the lateral surface of the temporal and parietal lobes, including the primary motor and sensory areas of face, throat, hand and arm, as well as speech areas in the dominant hemisphere. It follows that damage to the parietal branch may seriously impact the language and motor domains. It has also been shown that even an unruptured intracranial aneurysm can cause neuropsychological impairments after treatment and even before treatment, because anxiety for the risk of a rupture impairs cognitive resources [1]. In their review of the literature, the authors found that patients with aneurysm presented deficit of verbal and visual memory even before treatment, whereas other functions were spared, e.g., verbal fluency, cognitive flexibility, working memory, language, visuospatial ability and psychomotor ability [1–4]. However, neuropsychological consequences of a middle cerebral artery

aneurysm and its treatment are poorly described [3,5].

We describe a case of a fusiform aneurysm of one of the three branches of the left MCA supplying the insula close to the Broca's area. Endovascular treatment with complete occlusion of the aneurysm was performed.

To avoid occlusion-related risks, we performed real-time neuropsychological testing (RTNT), which is routinely used during awake surgery for glioma resection [6], during the temporary occlusion of this insular branch in order to test whether the occlusion caused cognitive and neurologic complications and permanent occlusion could be performed. In the past, a similar concept was used during the Wada test [7] only to evaluate the risk of postoperative deficit and to identify the lateralization of language representation by infusion of sodium amobarbital in the carotid artery.

[☆] Declaration of interest: none.

* Corresponding author at: IRCCS "E. Medea", Polo Regionale del Friuli Venezia Giulia, Via della Bontà, 7, San Vito al Tagliamento, PN 33078, Italy.

E-mail address: btomasino@ud.inf.it (B. Tomasino).

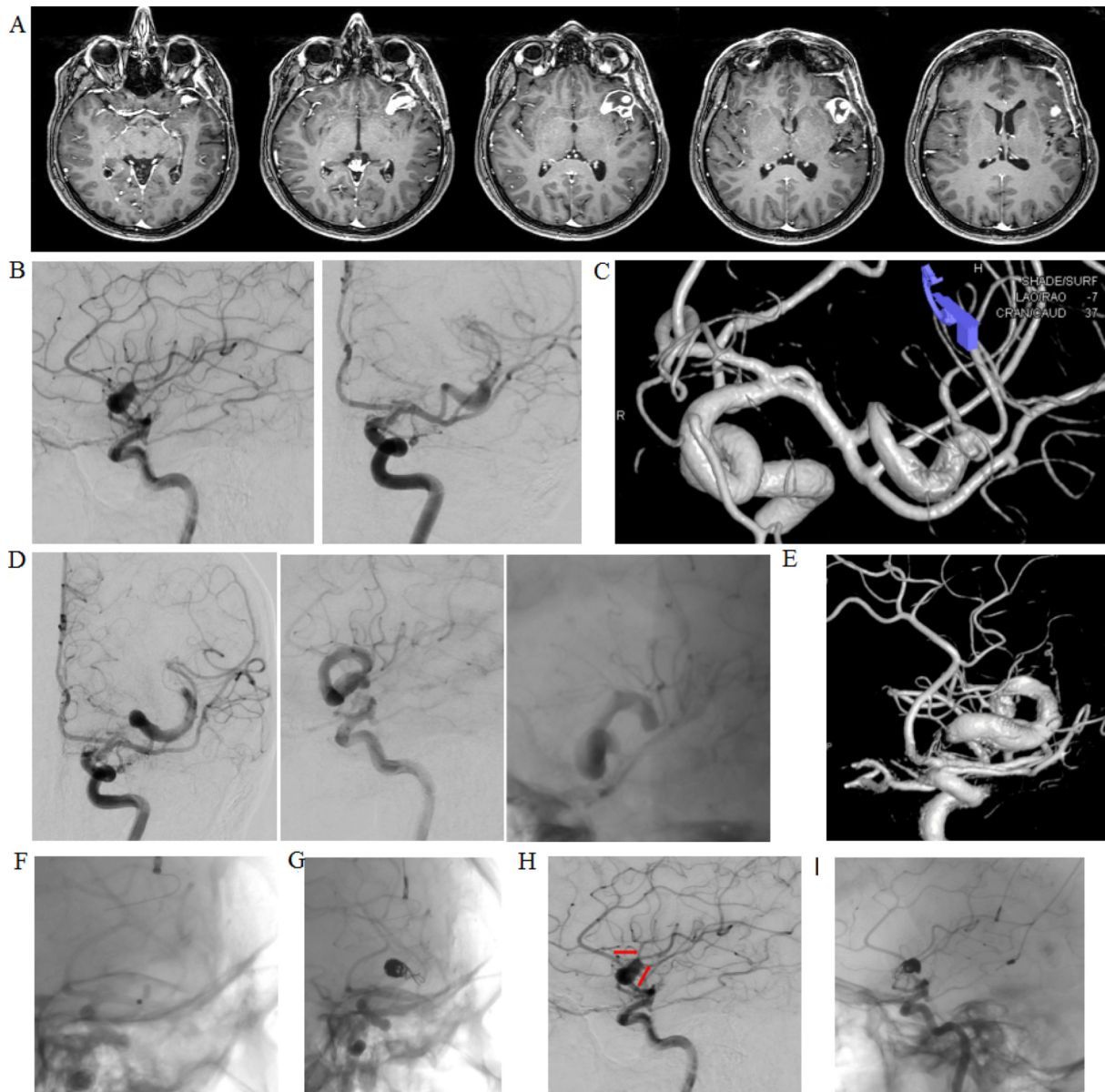


Fig. 1. (a) T1-weighted MRI axial slices. (b) First angiography showing the fusiform aneurysm in the insular branch of the left middle cerebral artery. (c) 3D reconstruction of the fusiform aneurysm showing two emerging vessels. (d) One-year follow-up angiography. The aneurysm is significantly longer. (e) 3D reconstruction shows that the perfusion is clearly slower. (f) A balloon is positioned in the aneurysmal branch of the MCA. Neuropsychological tests were performed during occlusion lasting 25 min. (g) Endovascular occlusion of the branch and exclusion of the fusiform aneurysm. (h) Pre-occlusion. (i) Post-occlusion. Red arrows indicate the two vessels emerging from the aneurysm. (For interpretation of the references to colour in this figure legend, the reader is referred to the web version of this article.)

2. Case report

Our patient is a 46-year-old woman with a fusiform aneurysm in the insular branch of the middle cerebral artery (MCA). She is a 100% right-handed [8] monolingual native speaker of Italian. She has an educational level of 8 years and works as a chef's assistant. She has pharmacologically treated arterial hypertension. She was hospitalized owing to an episode of dysarthria with deviated mouth followed by acute headache. The CT scan did not reveal any hemorrhage and the cerebral angiography detected an aneurysm. The patient received prophylactic dosing of enoxaparin until the intervention, which was not urgent, as there was not hemorrhage.

A cerebral angiography revealed the presence of a $12 \times 6\text{mm}$ fusiform aneurysm localized on the insular branch of the MCA, while two other branches were running along the sac. The angiogram also showed

two minor vessels emerging from the distal part of the aneurysm (see Fig. 1). Embolization by coiling or stenting was not feasible. A pterional craniotomy was performed. The fusiform aspect of the aneurysm with two emerging vessels and two branches of the MCA running besides was confirmed intra-operatively. As clipping as a procedure was not safe to modify the sac, only aneurysm wrapping was performed in order to strengthen the aneurysm walls.

One year later a follow-up cerebral angiography (see Fig. 1) revealed an enlargement of the fusiform aneurysm with slowing of perfusion inside the sac and in the two efferent vessels. Normal perfusion was found in the bigger branch of the MCA. Given the reduced perfusion on the angiogram, we assumed that these small vessels were not functionally important and complete occlusion of the aneurysm and the two vessels was proposed. The possibility of the flow diversion stent or a bypass been also considered, but excluded because of the two

Table 1

Pre- and post-occlusion neuropsychological evaluation performed one week prior to and after intervention.

	1 week pre-intervention	1 week after-intervention	Cut-off
Spatial Intelligence [11]	32/36	–	18
Short-term memory [14]	5	5	3
Working memory [14]	4	3	3
Ideomotor apraxia [13]	72/72	72/72	53
Oral apraxia [12]	20/20	20/20	16
Verbal comprehension [15]	35/36	35/36	29
Verbal fluency [17]	57	64	20
Word repetition [16]	45/45	45/45	45
Pseudoword repetition [16]	36/36	36/36	36
Sentence repetition and syntagm repetition [16]	14/14 and 5/6	14/14 and 5/6	14 and 6
Word reading [16]	92/92	92/92	89
Pseudoword reading [16]	43/45	43/45	42
Sentence reading [16]	6/6	6/6	6
Word writing [16]	46/46	46/46	43
Pseudoword writing [16]	25/25	25/25	22
Naming nouns [16]	30/30	29/30	27
Naming verbs [16]	28/28	28/28	25
Auditory lexical decision [16]	80/80	78/80	77
Visual lexical decision [16]	78/80	79/80	77
Phonemic discrimination [16]	60/60	60/60	57
Auditory grammaticality judgment tasks [16]	48/48	48/48	45
Visual grammaticality judgment tasks [16]	45/45	45/45	42
Auditory nouns and verbs comprehension tasks [16]	40/40 and 20/20	40/40 and 20/20	39 and 20
Visual nouns and verbs comprehension tasks [16]	40/40 and 20/20	40/40 and 20/20	39 and 20
Auditory comprehension tasks [16]	59/60	59/60	57
Visual sentence comprehension tasks [16]	45/45	45/45	42

emerging vessels. In addition if we were using the bypass, we would have used only one of the two emerging vessels. Thus, surgery appeared the safest procedure. The patient gave her informed consent to participate in the study. The study was approved by the local Ethics Committee.

The patient's language and motor representations were investigated by fMRI performed 6 days prior to artery occlusion. The fMRI tasks, which were used during RTNT, too, were described in previous studies of our group [9,10]. A Philips Achieva 3-T (Best, Netherlands) whole-body scanner was used to acquire both anatomical and functional images using a SENSE-Head-8 channel head coil.

One week prior intervention the patient performed neuropsychological assessment. The patient scored normally on a general non-verbal intelligence test [11], oral [12] and ideomotor apraxia [13], verbal short-term [14] and working memory task [14], the Token Test [15], on the sub-scales of the Batteria per l'analisi dei deficit afasici [16] and phonological fluency [17] (see Table 1).

2.1. Real time neuropsychological testing (RTNT) during occlusion by endovascular technique

We decided to perform an angiogram with test occlusion (Balt B1 non-detachable balloon, Fig. 1) of the involved branch combined with administration of neuropsychological tests appropriate for this specific brain area. The procedure lasted 25 min (see also Table 2).

During temporary occlusion we administered the same battery of tasks as used in real-time neuropsychological testing (RTNT) [6] for the left inferior frontal gyrus. The patient was asked to perform in addition to the neurophysiological monitoring, few motor tasks and a series of cognitive tests. The RTNT task sequence (i.e., run) includes tasks that are continuously administered in alternated order to gain a better

Table 2

Real-time neuropsychological testing (RTNT) during temporary occlusion, immediately post-permanent occlusion, 24 h post-permanent occlusion.

Run	Time	Task	Score
RTNT during temporary occlusion			
1	00:00	Finger tapping	+
1	00:50	Sensory check hand	+
1	01:40	Motor check feet	+
1	02:30	Sensory motor task for the feet	+
1	03:10	Naming N	10/10
1	03:40	Reading W	10/10
1	04:15	Repetition W	10/10
1	05:10	Reading PW	8/10
1	06:06	STM	4
1	06:50	Naming V	10/10
2	07:50	Finger tapping	+
2	08:40	Sensory check hand	+
2	09:40	Motor check feet	+
2	10:10	Sensory motor task for the feet	+
2	10:40	Naming N	9/10
2	11:24	Reading W	10/10
2	11:40	Repetition W	10/10
2	12:00	Pause	
2	14:50	Reading PW	10/10
2	15:40	STM	4
2	16:35	Naming V	10/10
3	17:40	Naming N	10/10
3	18:25	Reading W	10/10
3	19:45	Repetition W	10/10
3	20:07	Reading PW	8/10
3	21:09	STM	5
3	23:00	Naming V	10/10
4	24:34	Naming N	10/10
RTNT immediate post-permanent occlusion			
1	00:32	Naming N	10/10
1	00:56	Reading W	10/10
1	01:20	Repetition W	10/10
1	01:54	Reading PW	7/10
1	02:39	STM	4
1	03:10	Naming V	10/10
2	04:02	Reading PW	10/10
RTNT post-intervention (1 day after)			
1	00:29	Naming N	9/10
1	00:40	Reading W	10/10
1	01:15	Repetition W	10/10
1	01:46	Reading PW	9/10
1	02:32	STM	4
1	03:06	Naming V	10/10
2	04:00	Naming N	9/10
2	04:15	Reading W	10/10
2	04:23	Repetition W	10/10
2	04:31	Reading PW	10/10
2	04:41	STM	4
2	04:53	Naming V	10/10
3	05:10	Naming N	10/10
3	05:22	Reading W	10/10
3	05:30	Repetition W	10/10
3	05:41	Reading PW	9/10
3	05:50	STM	5
3	06:05	Naming V	10/10

W = words, PW = pseudowords; N = nouns; V = verbs; STM = short-term memory.

feedback and avoid the risk of mismatching the test with the proper function of the involved brain area. Once a run is complete, and if the patient's performance is within the normal range, a second run is started which follows the same sequence, yet with different items (see Table 2). The RTNT excluded the presence of aphasic symptoms or other neuropsychological deficits (see Table 2) during test occlusion. At the motor and sensory check (i.e., finger tapping task, reporting whether perceiving normally the sensations when we touched the fingers of the hands, and extension movements of the feet) she always performed normally. The tasks lasted 25 min. During the balloon test occlusion

Table 3

fMRI activations. For each region of activation, the coordinates in MNI space are provided with reference to the maximally activated voxel within an area of activation, as indicated by the highest Z-value ($P_{0.05}$, corrected for multiple comparisons at the cluster level, height threshold $P_{0.001}$, uncorrected). L/R = left/right hemisphere.

Region	Side	MNI			Z	Cluster size Vox
		x	y	z		
Object naming: PRE-POST						
Middle frontal gyrus	L	-48	20	42	4.69	72
IFG (pars opercularis)	L	-50	14	14	4.52	127
Object naming: POST-PRE						
-	-	-	-	-	-	-
W reading: PRE-POST						
MTG	R	66	-10	-16	5.82	297
W reading: POST-PRE						
Middle orbital gyrus	R	20	44	-18	5.74	79
Insula	L	-44	-2	-2	5.31	181
Middle frontal gyrus	L	-46	10	36	4.92	225
PW reading: PRE-POST						
MTG	R	46	-50	-2	4.91	131
PW reading: POST-PRE						
Middle orbital gyrus	R	20	44	-18	6.71	95
Insula	L	-44	-4	0	5.77	94
MTG	L	-62	-26	2	4.69	97
R hand movement: PRE-POST						
SMA	L	-6	-2	70	6.61	99
Postcentral gyrus (Area 1)	L	-54	-16	46	4.78	86
Postcentral gyrus (Area 3b)	L	-42	-20	50	3.97	
Cerebellum	R	20	-58	-18	4.63	81
R hand movement: POST- PRE						
-	-	-	-	-	-	-
Tongue movements: PRE-POST						
STG	L	-60	-36	22	5.44	215
IFG (pars opercularis)	R	56	10	6	5.01	180
precentral gyrus	R	52	-4	46	4.98	91
SMA	R	6	-2	50	4.89	65
MTG	R	52	-60	2	4.84	102
SMG	R	60	-34	46	4.82	154
STG	R	60	-34	18	4.79	108
SMG	R	64	-22	18	4.59	145
MTG	R	48	-36	-2	4.22	52
Inferior parietal lobule	L	-50	-28	38	4.20	103
SMA	R	0	14	44	4.17	74
Tongue movements: POST-PRE						
MTG	R	48	-62	14	4.58	96

blood pressure was controlled and maintained at the level of 120/80 mmHg, corresponding to the patient's normal pressure level (no hypertensive peaks occurred during the procedure).

As the patient's performance on RTNT was normal even at the last run of tests just before the end of test occlusion, the segment of the middle cerebral artery was occluded permanently. The patient underwent occlusion by embolization of the aneurysm and the two minor emerging vessels (Target 360° 10 × 30, 9 × 30, 6 × 10, 4 × 6, 4 × 10, 3 × 6 e Microsfere 4 × 8). The post-operative angiogram showed the complete occlusion of the aneurysm and the two branches (Fig. 1). We verified that there was a collateral filling.

We repeated the RTNT at the end of the occlusion, and the day after. After occlusion, motor and sensory tasks were performed normally. The patient complained that she had headache and felt sleepy. Her speech was feeble and slow. The neurophysiologist reported a slight decrease of motor evoked potentials. The patient performed 100% on all RTNT tasks (see Table 2). Yet, her voice was feeble.

2.2. Immediate post-operative course

One day after surgery, the patient performed normally on all tasks of the RTNT (see Table 2).

2.3. Post intervention neuropsychological testing (1 week after)

One week after intervention, the patient performed the same neuropsychological assessment she underwent before treatment. The patient reported a worsening in tongue and right arm sensory perception, sensory loss and that her cognitive abilities were unchanged. The patient's subjective report was accompanied by a normal neurological evaluation. The language and neuropsychological evaluation was comparable to the pre-intervention evaluation and excluded the presence of aphasic symptoms or other neuropsychological deficits (see Table 1).

2.4. Follow-up cerebral angiography and MRI

The MRI post occlusion, done one day after, excluded the presence of hemorrhage. Diffusion MRI was acquired (SE, FLAIR, DWI and DTI) reported the absence of signal alteration in DWI, no ADC restriction, a regular post contrast perfusion.

The follow-up cerebral angiography performed 7 month after, reported that the fusiform aneurysmatic sac appeared occluded, that the patency of the remaining examined branches was regular.

2.5. fMRI results

Pre- vs. post-occlusion comparison showed the changes in fMRI maps (Fig. 2).

3. Discussion

To our knowledge, this was the first time that selective neuropsychological testing was administered during an endovascular procedure to evaluate the feasibility of selective vessel occlusion. In the past, the Wada test [18] also known as the intracarotid sodium amobarbital procedure – consisting in a sodium amobarbital infusion in the carotid artery was used to identify the language-dominant hemisphere.

Intra-operative real-time neuropsychological testing (RTNT), which is routinely used during awake surgery for glioma resection [6] was implemented here with the aim to provide feedback to the interventional radiologist during the test occlusion of one branch of the left middle cerebral artery to evaluate the possibility of permanent occlusion.

RTNT showed that the patient's performance was always at ceiling throughout the test occlusion. At one week after the procedure, the patient provided 95.55% of correct responses.

fMRI data showed a reshaping related to a re-distribution of the blood flow after intervention for both language domain and motor representations. Regarding language representation, our findings are not only relevant for their clinical value but they also offered the chance – from a research perspective – to observe a significant change in the activation pattern of a very localized area. The pre- vs. post- occlusion fMRI comparison showed a decreased activation in the pars opercularis of the left inferior frontal gyrus for the task not involving overt articulation. Inner speech required by silent object naming likely is subserved by the areas devoted to preparation rather than those recruited by articulation [19]. By contrast, the task that required overt articulation, involved an increased activation in the post- vs. pre-occlusion that was localized in the left insula. This shows that, in our patient the occlusion of the insular branch of the left middle cerebral artery caused a decreased activation of the region around Broca's area and an increase in activation in the left insula, as evidenced by covert and overt articulatory tasks, respectively. This change was not related to behavioral impairments, as the patient's language performance was normal.

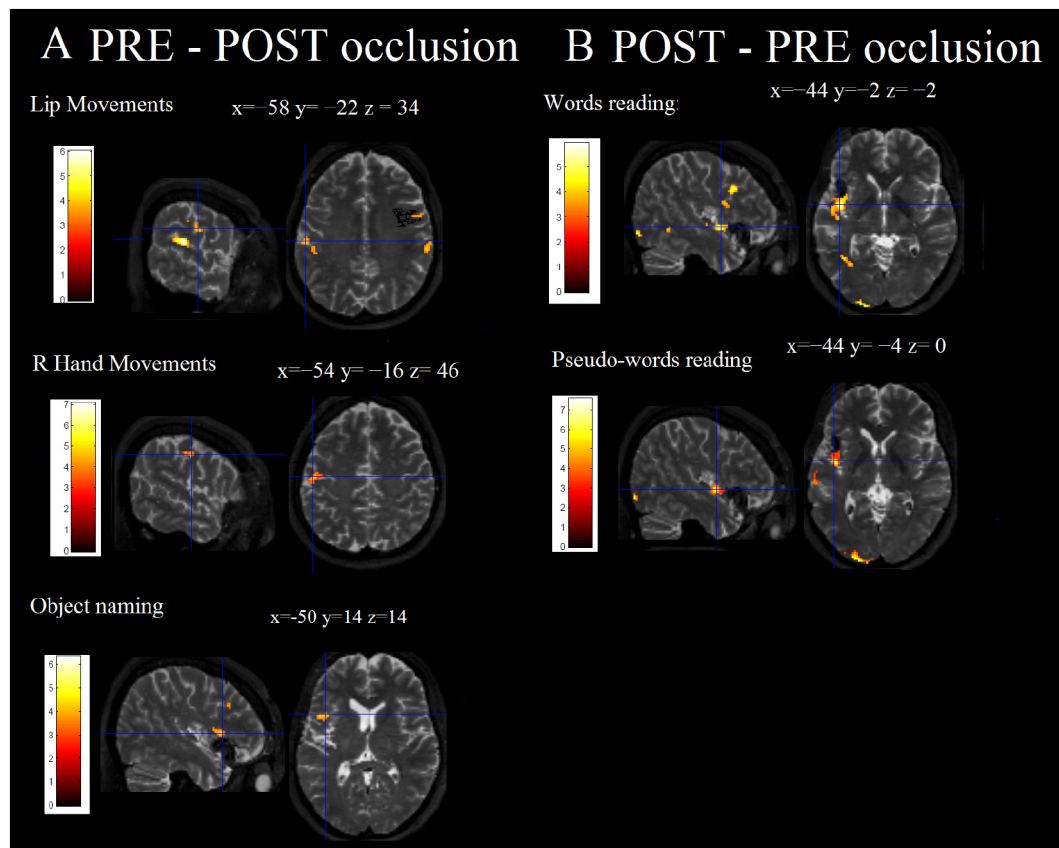


Fig. 2. The *silent* object naming task differentially activated the pars opercularis of the left inferior frontal gyrus, a cluster located just above the occlusion, and parts of the left middle frontal gyrus. No supra-threshold cluster survived in the post- vs. pre-occlusion comparison. Pre- vs. post-occlusion *articulation* tasks such as reading aloud words and pseudowords activated the right middle temporal gyrus, the right middle orbital gyrus, and, the left insula in the post- vs. pre-occlusion. At pre- vs. post-occlusion comparison, tongue movements differentially activated the left STG and the left inferior parietal lobule, in addition to a series of clusters in the right hemisphere (inferior frontal gyrus, precentral gyrus, supplementary motor area, middle and superior temporal gyrus and supramarginal gyrus). At post- vs. pre-occlusion comparison, the tongue movements' task differentially activated the right MTG. At pre- vs. post-occlusion comparison, right hand movements differentially activated the left supplementary motor area, the left postcentral gyrus (Areas 1 and 3b) and the right cerebellum and no supra-threshold cluster survived at post- vs. pre-occlusion comparison (Table 3).

As far as motor maps are concerned, in the first week post-occlusion, the patient reported a worsened tongue perception. The pre- vs. post-intervention task involved a greater activation of the right precentral gyrus at the level of the tongue representation and other motor-related areas of the right hemisphere. We speculate that these changes in activation might be related to a re-shaping of sensorimotor representations of the tongue after occlusion.

With regard to hand movements pre- vs. post-occlusion, right-hand movements differentially activated the left supplementary motor area, the left postcentral gyrus (Areas 1 and 3b) and the right cerebellum. The middle cerebral artery also supplies portions of the primary motor and sensory areas. During control of the right-hand movements, activation in the sensory motor cortex decreased owing to occlusion. Accordingly, in the first week post-occlusion, the patient reported a worsening in right-arm sensory perception.

In a research perspective, these fMRI findings are very interesting. Yet, the clinical picture post-performance remained almost unchanged, except for a minimal decrease in pseudoword reading performance which did not affect the patient's quality of life and was already present in the pre-occlusion testing.

4. Conclusion

To sum up, we confirm the reliability and effectiveness of RTNT even in a very limited and circumscribed area. A focused neuropsychological evaluation may be considered to effectively evaluate

the risk of vascular occlusion for a small branch of the MCA whose coordinates are not comparable with data we are used to when the test occlusion is made on ACI or MCA, if no other treatment is possible. RTNT is a complementary method that could allow to minimize the risk of ischemic injury in real time.

Conflict of interest statement

All authors disclose any potential sources of conflict of interest.

Acknowledgments

We wish to thank Dario Marin for neuropsychological data collection. We also acknowledge the support by the technical staff of the Medical imaging.

References

- [1] M.J. Bonares, A.L. de Oliveira Manoel, R.L. Macdonald, T.A. Schweizer, Behavioral profile of unruptured intracranial aneurysms: a systematic review, *Ann. Clin. Transl. Neurol.* 1 (2014) 220–232.
- [2] A. Fukunaga, K. Uchida, J. Hashimoto, T. Kawase, Neuropsychological evaluation and cerebral blood flow study of 30 patients with unruptured cerebral aneurysms before and after surgery, *Surg. Neurol.* 51 (1999) 132–138.
- [3] T. Haug, et al., Surgical repair of unruptured and ruptured middle cerebral artery aneurysms: impact on cognitive functioning and health-related quality of life, *Neurosurgery* 64 (2009) 412–420.
- [4] K. Towgood, J.A. Ogden, E. Mee, Psychosocial effects of harboring an untreated

- unruptured intracranial aneurysm, *Neurosurgery* 57 (2005) 858–864.
- [5] A.C. Vieira, et al., Performance of language tasks in patients with ruptured aneurysm of the left hemisphere worsens in the post-surgical evaluation, *Arq. Neuropsiquiatr.* 74 (2016) 638–643.
- [6] M. Skrap, D. Marin, T. Ius, F. Fabbro, B. Tomasino, Brain mapping: a novel intraoperative neuropsychological approach, *J. Neurosurg.* 5 (1–11) (2016).
- [7] J. Wada, T. Rasmussen, Intracarotid injection of sodium amytal for the lateralization of cerebral speech dominance, *J. Neurosurg.* 17 (1960) 266–282.
- [8] R.C. Oldfield, The assessment and analysis of handedness: the Edinburgh inventory, *Neuropsychologia* 9 (1971) 97–113.
- [9] B. Tomasino, et al., Foreign accent syndrome: a multimodal mapping study, *Cortex* 49 (2013) 18–39.
- [10] B. Tomasino, et al., A multimodal mapping study of conduction aphasia with impaired repetition and spared reading aloud, *Neuropsychologia* 70 (2015) 214–226.
- [11] A. Basso, E. Capitani, M. Laiacona, Raven's coloured progressive matrices: normative values on 305 adult normal controls, *Funct. Neurol.* 2 (1987) 189–194.
- [12] E. De Renzi, A. Piezuro, L.A. Vignolo, Oral apraxia and aphasia, *Cortex* 2 (1966) 50–73.
- [13] E. De Renzi, F. Motti, P. Nichelli, Imitating gestures. A quantitative approach to ideomotor apraxia, *Arch. Neurol.* 37 (1980) 6–10.
- [14] A. Orsini, et al., Verbal and spatial immediate memory span: normative data from 1355 adults and 1112 children, *Ital. J. Neurol. Sci.* 8 (539–548) (1987).
- [15] E. De Renzi, P. Faglioni, Normative data and screening power of a shortened version of the Token test, *Cortex* 14 (1978) 41–49.
- [16] G. Miceli, A. Laudanna, C. Burani, R. Capasso, Batteria per l'analisi Dei Deficit Afasici: BADA [BADA: A Battery for the Assessment of Aphasic Disorders.], CEPSAG, Roma, 1994.
- [17] G. Novelli, et al., Tre test clinici di ricerca e produzione lessicale. Taratura su soggetti normali, *Arch. Psicol. Neurol. Psichiatr.* 47 (1996) 477–505.
- [18] K.J. Meador, D.W. Loring, The Wada test. Controversies, concerns, and insights, *Neurology* 52 (1999) 1535–1536.
- [19] A. Flinker, et al., Redefining the role of Broca's area in speech, *Proc. Natl. Acad. Sci. U. S. A.* 112 (2015) 2871–2875.