

## HOW WE TEACH | *Classroom and Laboratory Research Projects*

# Evaluation of chest ultrasound integrated teaching of respiratory system physiology to medical students

 Matteo Paganini, Michela Bondi, and Alessandro Rubini

Department of Biomedical Sciences, Section Physiology, University of Padova, Padova, Italy

Submitted 1 May 2017; accepted in final form 29 August 2017

**Paganini M, Bondi M, Rubini A.** Evaluation of chest ultrasound integrated teaching of respiratory system physiology to medical students. *Adv Physiol Educ* 41: 514–517, 2017; doi:10.1152/advan.00062.2017.—Ultrasound imaging is a widely used diagnostic technique, whose integration in medical education is constantly growing. The aim of this study was to evaluate chest ultrasound usefulness in teaching respiratory system physiology, students' perception of chest ultrasound integration into a traditional lecture in human physiology, and short-term concept retention. A lecture about respiratory physiology was integrated with ultrasound and delivered to third-year medical students. It included basic concepts of ultrasound imaging and the physiology of four anatomic sectors of the body of a male volunteer, shown with a portable ultrasound device (pleural sliding, diaphragmatic movement, inferior vena cava diameter variations, cardiac movements). Students' perceptions of the integrated lecture were assessed, and attendance recorded. After 4 mo, four multiple-choice questions about respiratory physiology were administered during the normal human physiology examinations, and the results of students who attended the lesson and those of who did not were compared. One hundred thirty-four students attended the lecture. Most of them showed encouragement for the study of the subject and considered the ultrasound integrated lecture more interesting than a traditional one and pertinent to the syllabus. Exposed students achieved a better score at the examination and committed less errors than did nonexposed students. The chest ultrasound integrated lecture was appreciated by students. A possible association between the exposure to the lecture and short-term concept retention is shown by better performances of the exposed cohort at the examination. A systematic introduction of ultrasound into physiology traditional teaching will be promoted by the Ultrasound-Based Medical Education movement.

human physiology; teaching; respiratory system; chest ultrasound

ULTRASOUND IMAGING is a well-known diagnostic technique. High-definition and increasingly smaller devices have enabled the birth of the so-called “bedside ultrasound,” which means moving the ultrasound machine to patients' beds instead of moving the patients themselves, especially if they are critical and clinicians need information within minutes.

In educational terms, ultrasound is likewise becoming increasingly pivotal. It has become part of the routine in the clinical teaching curriculum (e.g.: internal medicine, cardiology, obstetrics and gynecology) for years, but, for the most part, lectures are limited to slides or videos on which the professor makes comments. Only a limited number of medical

schools offer practical ultrasound laboratories and demonstrations in the form of an integrated ultrasound curriculum (1, 2, 7, 9, 10, 12).

Less diffused, but fast growing, is the integration of ultrasound in the preclinical subjects setting, where this technique is shown to meet the professors' teaching needs, especially in anatomy (4, 11, 12, 16–19), and it is well appreciated by students. Also in physiology, some experiences are described concerning the heart (3, 5, 8) or the cardiovascular system and reflexes (15).

In the field of respiratory system physiology, as we suggested in a previous and first experience (14), ultrasound can allow the professor to show in vivo macroscopic dynamic changes of the respiratory apparatus, with the possibility of integrating in real time the lecture and answering students' questions, not only with words, but also by showing what is happening inside the human body.

The present study aimed to evaluate the medical student's perception of integrating ultrasound technique into traditional teaching about respiratory physiology and to assess short-term concept retention after the ultrasound integrated lecture (UIL).

## MATERIALS AND METHODS

In September 2015, before the lecture, 20 questions about respiratory system physiology were written by a physiology department faculty member and reviewed by two other members, all blinded to the contents of the lecture. Each answer had four possible choices and only one predefined correct answer, and all were pertinent to physiology's syllabus and specific learning objectives.

In November 2015, third-year medical students of the University of Padova (Italy) attended an ultrasound-based didactic lecture, as part of their normal human physiology course, at the end of the respiratory physiology module. None of the students had previously been exposed to ultrasound didactic sessions, as this technique is traditionally presented after the students have completed their preclinical studies, during their fourth academic year. All students had previously passed the Human Anatomy exam, taken during the second academic year.

The attendance of students was recorded as a routine university procedure: in fact, to gain access to the final exam, students must attend at least the 80% of the lectures, so they are allowed to be absent randomly from 20% of the syllabus' lectures. Furthermore, the exact date of the lecture was not told to the students. In these two ways, a potential selection bias was avoided of students more engaged in the educational process.

The lecture was delivered by an expert sonographer physician (M.P.), supported by the professor (A.R.) of Human Physiology, who stimulated interaction with students and questions from them as in a standard lecture. It lasted almost 45 min and was divided into three parts, covering almost all of the learning objectives of the respiratory physiology module. The instructional strategy and in-class activities

Address for reprint requests and other correspondence: M. Paganini, Dept. of Biomedical Sciences, University of Padova, Via Marzolo 3, Padova 35128, Italy (e-mail: paganini.mtt@gmail.com).

were similar for both the UIL and a normal lecture, with the exception of including *in vivo* ultrasound activities and showing ultrasound videos and images during the UIL.

The first part, which lasted ~15 min, consisted of an introduction to specialized terms, such as hyperechoic, hypoechoic, anechoic, acoustic bioimpedance, acoustic interface, and probe spatial orientation. Details concerning image formation and technical aspects of ultrasound physics were not discussed because these are covered during the radiology course. After these introductory comments, some key features of ultrasound were discussed: its capacity to show, dynamically and *in vivo*, anatomy, physiology, and pathology of patients; and advantages and disadvantages of ultrasound with respect to other imaging modalities, in particular, with a standard chest radiograph. The students were provided with this basic information to follow the rest of the session.

In the second part, which lasted ~20 min, a male student volunteer underwent real-time ultrasound scanning that was performed and explained by the sonographer using a portable Xario 100 ultrasound device (Toshiba Medical System, Shimoishigami, Japan) with a convex (3.5 MHz), a linear (10 MHz), and a sector probe (2.5 MHz). The sonographic images, covering four anatomic sectors, were projected onto a large lecture screen, easily seen by all of the students attending the session. The sonographer was assisted by the professor of physiology who provided commentary and reiterated physiology concepts previously covered during his lectures.

First, the students were shown movements of the visceral and parietal pleura during the respiratory cycle (pleural sliding), with the linear probe in lengthwise and in crosswise projection on the anterior chest wall.

Second, the diaphragm was visualized in long-axis and oblique views with the linear probe on the lateral chest wall, and its excursion was shown during normal breathing (curtain sign) and after maximal inspiration and maximal expiration.

Third, the intra-abdominal portion of the inferior vena cava was displayed with the sector probe in long axis along the epigastric region. Its diameter reduction during normal and maximal inspiration, and the absence of diameter reduction during a Valsalva maneuver, were displayed in B-mode, Doppler, and color Doppler mode.

Similar scans were provided regarding the internal jugular vein and its diameter variations with the respiratory cycle, with the use of a linear probe in the lateral neck region.

In the third and last part, which lasted ~10 min, short videos about main pathologies detectable with chest ultrasound were projected with commentaries referring to physiology abnormalities and alterations. In particular, the students were shown ultrasound reports of cardiogenic pulmonary edema and acute respiratory distress syndrome (B-line artifacts), pneumonia (pleural abnormality and irregularity), and pneumothorax (no pleural sliding).

At the end of the demonstration, the students were asked to complete an optional and anonymous questionnaire evaluating the lecture. The questionnaire was composed of 2 open questions and 10 items, 7 positive and 3 negative, that were to be rated using a 5-point Likert scale (1 = totally disagree; 2 = disagree; 3 = uncertain;

4 = agree; 5 = totally agree). See Tables 1–3. The internal consistency of the questionnaire was measured by Cronbach's  $\alpha$ .

Data were coded on a master sheet using a Microsoft Office Excel spreadsheet (version 2003, Microsoft, Redmond, WA), used also for basic calculations. Data entry was double-checked by a second investigator.

Four months after the lecture, at the end of a normal physiology exam session, 4 multiple-choice questions were randomly selected among the initial group of 20 and administered to the students attending that session, to be completed in 15 min. The students' identity was tracked. Questions are listed in Fig. 1 legend.

After this session, we divided the examination questionnaires on the basis of the attendance to the UIL: students who attended the lecture acted as the "exposed cohort," and those who did not acted as the "nonexposed cohort." Selection bias was avoided.

Differences between the two cohorts' responses on the four experimental questions were compared using a one-way, between-subjects Mann-Whitney *U*-test. The examination questionnaire was considered "passed" with at least three correct answers out of four.

Statistical software Prism 6 (GraphPad Software, La Jolla, CA) was used to analyze the results. The students were informed about the lecture beforehand and about the optional examination, and verbal consent was obtained. The study was approved by the local ethics committee.

## RESULTS

One hundred and thirty-four students attended the lecture. All of them answered the questionnaire. Double-checked data were 100% concordant.

The means of the positive items were between 4.10 (*item 2*: ultrasound was useful for the better understanding of anatomy than a usual lecture) and 4.61 (*item 6*: tendency to recommend the ultrasound integrated lecture to a colleague). In particular, this last item was rated 4 and 5 by the students, resulting in the lowest standard deviation (0.49). However, the means of the remaining five positive items were all >4 (Table 1).

About the percentage of agreement among students, they all expressed an opinion of "agree" or "totally agree" with *item 6* (100%). More than three-fourths of all participants (87.31%) expressed a good opinion about *item 2*. The percentage of students agreeing or totally agreeing with the remaining positive items were all >90% (Table 1).

In reference to the three negative items, the first (*item 1*: ultrasound visual interpretation was difficult) obtained the highest mean and SD (2.51 and 0.96, respectively) and the lowest percentage (57.46%) of students voting "disagree" or "totally disagree." The two remaining items' results were quite concordant, with means tending to 1.3 and a disagreeing percentage >98% or a little more (Table 2).

Table 1. Positive items

Item No.	Positive Items	Minimum Score	Maximum Score	Mean	SD	%Agree
1	Lecture pertaining to physiology syllabus	3	5	4.46	0.58	97.01
2	Better understanding of anatomy than a usual lecture	2	5	4.10	0.64	87.31
3	Better understanding of physiology than a usual lecture	2	5	4.19	0.64	90.30
4	Enhanced motivation to study physiology than a usual lecture	2	5	4.41	0.66	91.79
5	More interesting than a usual lecture	3	5	4.58	0.51	99.25
6	Tendency to recommend it to a colleague	4	5	4.61	0.49	100
7	Probability of a future role in medical school education	3	5	4.54	0.61	94.03

Items were rated using a 5-point Likert scale (1 = totally disagree; 2 = disagree; 3 = uncertain; 4 = agree; 5 = totally agree). Values are minimum and maximum scores, mean and SD, and percentage of students who "agree" and "totally agree."

Table 2. Negative items

Item No.	Negative Items	Minimum Score	Maximum Score	Mean	SD	%Disagree
1	Difficult visual interpretation	1	4	2.51	0.96	57.46
2	Boredom	1	3	1.36	0.51	98.51
3	Waste of time	1	2	1.28	0.45	100

Items were rated using a 5-point Likert scale (1 = totally disagree; 2 = disagree; 3 = uncertain; 4 = agree; 5 = totally agree). Values are minimum and maximum scores, mean and SD, and percentage of students who “disagree” and “totally disagree.”

Cronbach’s  $\alpha$  resulted in a value of 0.74 (good internal consistency).

Regarding the first open question, “What did you like most about using the ultrasound in the lecture?”, students enjoyed the in vivo displaying capacity of physiology and appreciated anatomic relations, the potentiality of ultrasound technique, and technical aspects of the ultrasound machine (Table 3).

Regarding the second open question, “How could ultrasound be helpful in your future medical school education?”, ~53% of students answered with key words relating to the diagnostic potential in future clinical subjects, and ~16% referred to practical applications of the studied subjects; some of them cited a possible use in a particular specialty (Table 3).

One hundred and twenty-five students underwent the final exam: 57 of them had previously attended the UIL, and 68 had not.

Exposed students attained a mean of 3.89 correct responses (SD 0.40; minimum 0; maximum 4), and nonexposed students had a mean of 3.41 correct responses (SD 0.67; minimum 0; maximum 4). If compared, exposed students globally achieved significantly better results than nonexposed students ( $U$  1,152;  $P < 0.05$ ).

Figure 1 compares the percentage of wrong answers between the two cohorts. Nonexposed students committed more errors (in percentage) in every questions than did exposed students, and, in question 4, the percentage of wrong answers between the two cohorts appears to be significantly different (Fig. 1). Furthermore, 5.6% of nonexposed students did not pass the exam vs. 1.6% of exposed students.

**DISCUSSION**

After an initial positive experience (14), we decided to plan this research, which is the first to evaluate chest ultrasound,

Table 3. Open-question answers

Open Questions	%Response
What did you like most about using the ultrasound in the lecture?	
The exhibition of physiology	39.55
The exhibition of anatomy	38.06
Performing and ultrasound technique, ultrasound apparatus	38.81
Diagnostic role	2.23
How could ultrasound be helpful in your future medical school education?	
Pathology diagnoses in clinical subjects	52.98
Practical application of studied subjects	15.67
Specialties (obstetrics/gynecology = 1; cardiology = 2; oncology = 2; other = 3)	5.97

Open questions and answers are shown. The percentage of students who answered with the related key words is shown.

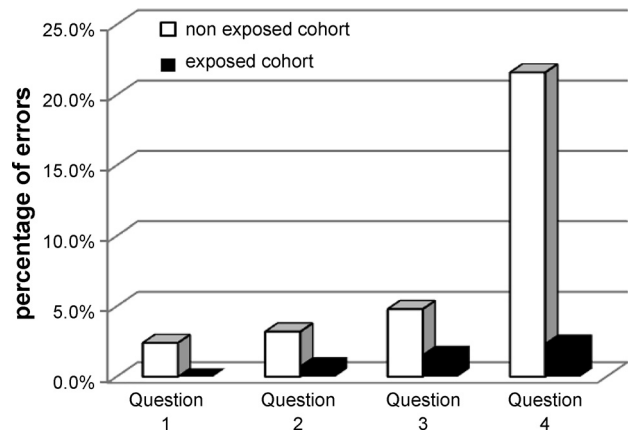


Fig. 1. Percentage of errors on the final exam for the exposed cohort (EX) and nonexposed cohort (NEX) is shown for questions 1–4. Question 1: “Between the parietal and the visceral pleura ....” Correct answer: “There is negative pressure.” Results: EX, 0.0%; NEX, 2.4% ( $U = 1,852, P = 0.67$ ). Question 2: “During normal inspiration, describe the movement of diaphragm.” Correct answer: “It contracts and lowers.” Results: EX, 0.8%; NEX, 3.2% ( $U = 1,858, P = 0.69$ ). Question 3: “Functional residual capacity is the sum of ....” Correct answer: “Expiratory reserve volume and residual volume.” Results: EX, 1.6%; NEX, 4.8% ( $U = 1,835, P = 0.61$ ). Question 4: “During a Valsalva maneuver, what happens to the external jugular vein?” Correct answer: “The diameter increases, with reduction of venous return.” Results: EX, 2.4%; NEX, 21.6% ( $U = 1,270, P = 0.0009$ ).

into traditional physiology teaching of the respiratory system, and several features distinguished it.

Thanks to the versatility of new portable devices (like ours), the use of ultrasound in an educational context is nowadays feasible and simple. For example, in our experience, the professor could switch rapidly from the projection of slides to echographic images and vice versa, but it could be employed in various didactic contexts: now during traditional frontal lessons in the classroom or practical laboratories, but in the future also during oral or written exams.

The administered questionnaire, which has a good internal consistency, showed high rates of satisfaction. We asked the students not only to express an opinion about the lecture itself, but also to compare this experience with a classical lecture. Since the aim of every physiology professor is to motivate students to study the subject, ultrasound could clearly be an added value to the lecture that stimulates attention, curiosity, and interest. In fact, nearly all participants thought that the UIL was more interesting than a normal lecture, and >98% did not find it boring and did not think it was a waste of time. About 91% of students said they gained more motivation to study physiology by attending this UIL compared with a normal lecture, and all of them would recommend it to a colleague.

About 87% of the students declared they had a better understanding of anatomy, and ~90% of physiology, after the UIL compared with a normal lecture. The basics of ultrasound technique explained in the first part of the UIL proved to be sufficient, allowing the students to understand the description the images projected, and improving their comprehension and confidence with anatomy and physiology, because they correlated what they had studied before with what they saw on the screen. We did not investigate whether students correctly interpreted ultrasound images, because this was not among the aims of this study, and we know that ultrasound interpretation

is an important task of the fourth year's radiology course in the present Italian medical school system.

About 57% of the students said that the images were not difficult to interpret (Table 2), whereas others affirmed they were uncertain (22%) or encountered some difficulties (21%). This variability probably derives from students' lack of experience in the ultrasound field at the third year of medical school, but that is why images were explained by the sonographer or the professor. Nevertheless, several researchers suggest that the use of ultrasound in subsequent times could help students become acquainted and confident with this technique (2, 10, 12). This is another interesting point that could be assessed after the integration of an ultrasound curriculum into medical school programs.

Only a few previous papers have shown a possible association between ultrasound-based seminars and performance at exams, even with several limitations. Lim et al. (13) suggested that limited exposition of medical students to the ultrasound technique could improve their performances, and also Bell et al. (3) reported similar results in cardiac physiology teaching. In our experience, all of the questions reviewed by the expert board were pertinent to the syllabus and to the UIL, and 90% of students said that they found the UIL pertinent to the syllabus. Therefore, both the exposed and nonexposed students should have known the correct answers, as a part of a normal physiology examination.

Nonexposed students committed more errors in each question, and only in *question 4* did the exposed students score significantly better than the nonexposed students. Therefore, it is not possible to distinguish a clear association between the exposure to UIL and short-term retention.

Among methodological limitations, we report the small sample size, the small number of questions administered, and the fact that the lecture was performed in just one medical school, so results are not representative. We did not compare the knowledge level administering the same questions before and after the UIL to avoid learning bias. Nevertheless, the evaluation of ultrasound as a teaching tool in other systems and long-term concept retention could be interesting.

**Conclusions.** The results we obtained suggest that ultrasound could be a useful didactic tool in the field of respiratory physiology: students appreciated it very much, and further studies are certainly needed to assess short- and long-term concept retention.

This is another example of the new intellectual movement that we called UBMed, Ultrasound-Based Medical Education, created in 2013 to promote a better integration of ultrasound into preclinical and clinical subjects so that students can become familiar, as soon as possible, with this new technique. In fact, we believe that seeing in vivo and in real time what is explained by the professor with the help of ultrasound could have a positive impact on students' university and professional career.

#### DISCLOSURES

No conflicts of interest, financial or otherwise, are declared by the authors.

#### AUTHOR CONTRIBUTIONS

M.P. and A.R. conceived and designed research; M.P. and A.R. performed experiments; M.P. and M.B. analyzed data; M.P. and M.B. interpreted results of experiments; M.P. and M.B. prepared figures; M.P. and M.B. drafted

manuscript; M.P., M.B., and A.R. edited and revised manuscript; M.P., M.B., and A.R. approved final version of manuscript.

#### REFERENCES

1. Bahner DP, Goldman E, Way D, Royall NA, Liu YT. The state of ultrasound education in U.S. medical schools: results of a national survey. *Acad Med* 89: 1681–1686, 2014. doi:10.1097/ACM.0000000000000414.
2. Bahner DP, Adkins EJ, Hughes D, Barrie M, Boulger CT, Royall NA. Integrated medical school ultrasound: development of an ultrasound vertical curriculum. *Crit Ultrasound J* 5: 6, 2013. doi:10.1186/2036-7902-5-6.
3. Bell FE III, Wilson LB, Hoppmann RA. Using ultrasound to teach medical students cardiac physiology. *Adv Physiol Educ* 39: 392–396, 2015. doi:10.1152/advan.00123.2015.
4. Brown B, Adhikari S, Marx J, Lander L, Todd GL. Introduction of ultrasound into gross anatomy curriculum: perceptions of medical students. *J Emerg Med* 43: 1098–1102, 2012. doi:10.1016/j.jemermed.2012.01.041.
5. Brunner M, Moeslinger T, Spieckermann PG. Echocardiography for teaching cardiac physiology in practical student courses. *Am J Physiol* 268: S2–S9, 1995.
6. Connolly K, Beier L, Langdorf MI, Anderson CL, Fox JC. Ultrafast: a novel approach to ultrasound in medical education leads to improvement in written and clinical examinations. *West J Emerg Med* 16: 143–148, 2015. doi:10.5811/westjem.2014.11.23746.
7. Tuca C, Scheiermann P, Hempel D, Via G, Seibel A, Barth M, Hirche TO, Walcher F, Breitzkreutz R. Assessment of a new e-learning system on thorax, trachea, and lung ultrasound. *Emerg Med Int* 2013: 145361, 2013. doi:10.1155/2013/145361.
8. Hammoudi N, Arangalage D, Boubrit L, Renaud MC, Isnard R, Collet JP, Cohen A, Duguet A. Ultrasound-based teaching of cardiac anatomy and physiology to undergraduate medical students. *Arch Cardiovasc Dis* 106: 487–491, 2013. doi:10.1016/j.acvd.2013.06.002.
9. Heiberg J, Hansen LS, Wemmelund K, Sørensen AH, Ilkjaer C, Cloete E, Nolte D, Roodt F, Dyer R, Swanevelder J, Sloth E. Point-of-care clinical ultrasound for medical students. *Ultrasound Int Open* 01: E58–E66, 2015. doi:10.1055/s-0035-1565173.
10. Hoppmann RA, Rao VV, Poston MB, Howe DB, Hunt PS, Fowler SD, Poulman LE, Wells JR, Richeson NA, Catalana PV, Thomas LK, Britt Wilson L, Cook T, Riffle S, Neuffer FH, McCallum JB, Keisler BD, Brown RS, Gregg AR, Sims KM, Powell CK, Garber MD, Morrison JE, Owens WB, Carnevale KA, Jennings WR, Fletcher S. An integrated ultrasound curriculum (iUSC) for medical students: 4-year experience. *Crit Ultrasound J* 3: 1–12, 2011. doi:10.1007/s13089-011-0052-9.
11. Ivanusic J, Cowie B, Barrington M. Undergraduate student perceptions of the use of ultrasonography in the study of "living anatomy". *Anat Sci Educ* 3: 318–322, 2010. doi:10.1002/ase.180.
12. Kessler C, Bhandarkar S. Ultrasound training for medical students and internal medicine residents--a needs assessment. *J Clin Ultrasound* 38: 401–408, 2010. doi:10.1002/jcu.20719.
13. Lim JS, Lee S, Do HH, Oh KH. Can limited education of lung ultrasound be conducted to medical students properly? A pilot study. *BioMed Res Int* 2017: 8147075, 2017. doi:10.1155/2017/8147075.
14. Paganini M, Rubini A. Chest ultrasound integrated teaching of respiratory system physiology to medical students: a first experience. *Adv Physiol Educ* 39: 129–130, 2015. doi:10.1152/advan.00084.2014.
15. Paganini M, Rubini A. Ultrasound-based lectures on cardiovascular physiology and reflexes for medical students. *Adv Physiol Educ* 40: 243–247, 2016. doi:10.1152/advan.00010.2016.
16. Rao S, van Holsbeeck L, Musial JL, Parker A, Bouffard JA, Bridge P, Jackson M, Dulchavsky SA. A pilot study of comprehensive ultrasound education at the Wayne State University School of Medicine: a pioneer year review. *J Ultrasound Med* 27: 745–749, 2008. doi:10.7863/jum.2008.27.5.745.
17. Swamy M, Searle RF. Anatomy teaching with portable ultrasound to medical students. *BMC Med Educ* 12: 99, 2012. doi:10.1186/1472-6920-12-99.
18. Tshibwabwa ET, Groves HM. Integration of ultrasound in the education programme in anatomy. *Med Educ* 39: 1148, 2005. doi:10.1111/j.1365-2929.2005.02288.x.
19. Wittich CM, Montgomery SC, Neben MA, Palmer BA, Callahan MJ, Seward JB, Pawlina W, Bruce CJ. Teaching cardiovascular anatomy to medical students by using a handheld ultrasound device [3]. *JAMA* 288: 1062–1063, 2002. doi:10.1001/jama.288.9.1062.