The Journal of International Advanced Otology

J Int Adv Otol 2025; 21: 1-3 • DOI: 10.5152/iao.2025.241771

Original Article

Transmeatal Section of the Array in Cochlear Implant Explantation and Reimplantation: How I Do It

Stefano Concheri, Elisabetta Zanoletti, Sebastiano Franchella

Department of Neuroscience, Section of Otorhinolaryngology, University of Padova, Padova, Italy

ORCID IDs of the authors: S.C. 0009-0001-0143-3751, E.Z. 0000-0001-5562-5292, S.F. 0000-0001-5562-5292

Cite this article as: Concheri S, Zanoletti E, Franchella S. Transmeatal section of the array in cochlear implant explantation and reimplantation: how I do it. *J Int Adv Otol.* 2025, 21(3), 1771, doi: 10.5152/iao.2025.241771.

BACKGROUND: Cochlear implant explantation and reimplantation (ERI) are rarely required, but the widespread use of implants has made it a procedure that every otologic surgical center must address. Although generally described as safe, ERI presents specific surgical challenges, particularly concerning the replacement of the array.

METHODS: The transmeatal section of the array as the initial step of cochlear implant ERI is proposed and described.

RESULTS: A brief case series did not report any specific complications.

CONCLUSION: The transmeatal section of the array allows for the early and safe removal of the cable portion within the mastoid, enabling the surgeon to address scar tissue and new bone formation without the hindrance of the cable and preventing the premature removal of the array in the cochlea.

KEYWORDS: Cochlear implantation, otologic surgical procedures, reimplantation

TECHNIQUE DESCRIPTION

Device failures and complications following cochlear implantation (CI) are rare.[1] However, the increasing use of this device has made cases requiring explantation and either simultaneous or sequential reimplantation (ERI) more relevant.[1-3] Despite ERI being generally considered safe and successful,[2] it presents certain challenges for surgeons, requiring a meticulous approach to address technical intricacies.[4,5] In this context, a simple technical refinement is proposed to streamline and facilitate the overall procedure: transmeatal transection of the array as the initial step of the ERI process.

When the patient is under general anesthesia and prepared for the procedure, an ear speculum is inserted into the external auditory canal and a tympano-meatal flap is elevated through a purely transmeatal approach. A small flap and narrow access are adequate for the procedure. Next, the microscopic focus points on the promontory area and the array emerging from the round window are identified (see Figure 1A) and carefully sectioned distally, in proximity to the posterior tympanotomy (see Figures 1B and 2). The tympano-meatal flap is then repositioned and the external auditory canal packed. Subsequently, the retroauricular ERI procedure is routinely carried out. The previous CI cable is identified beneath the myofascial flap within the mastoid cavity and, being already transected through the transmeatal approach, can be easily removed, possibly along with the receiver/stimulator. After array removal, the revision of the cavity is performed to expose and free the area of the posterior tympanotomy. The distal part of the cable is identified and still left in situ, the new processor is positioned in the previous lodgement and the new array set to be inserted. The old array is removed just before the new one is ready to be inserted (see Figure 3), which can be done easily and before any blood, bone dust, or scar present might make the step more difficult. Closure of the cochleostomy and posterior tympanotomy, as well as the retroauricular soft tissue repositioning, are performed conventionally.

In this center, over a period of 24 months from the beginning of 2022 to December 31, 2023, 237 CIs have been placed, of which 15 were ERIs. The transmeatal transection of the array as described herein was performed in the last 8 ERIs. No intraoperative complications were reported. All patients were routinely discharged on the first postoperative day. Follow-up did not reveal any specific

Corresponding author: Stefano Concheri, e-mail: stefano.concheri@unipd.it or stefano.concheri@gmail.com
Received: October 18, 2024 • **Revision Requested:** October 26, 2024 • **Last Revision Received:** February 7, 2025 • **Accepted:** February 21, 2025 • **Publication Date:** May 20, 2025
Available online at www.advancedotology.org

Content of this journal is licensed under a Creative Commons Attribution-NonCommercial 4.0 International License.

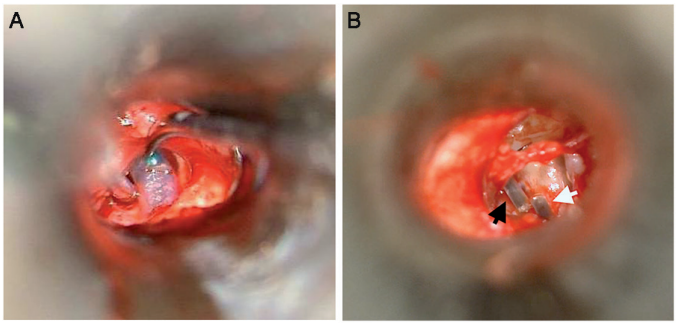

Figure 1. The cochlear implant cable identification after elevation of tympanomeatal flap (A) and the cable after transection (B) (left ear). Black arrow: the distal part of the cable, with the array, going into the cochlea through the round window. White arrow: the proximal part of the cable, going into the mastoid through the posterior tympanotomy.

complications after discharge, and all patients regularly activated their CI after approximately 1 month (Comitato Etico Territoriale Area Centro - Est Veneto (CET - ACEV) approval number: 483n/AO/24; May 09, 2024; all patients provided informed consent before surgery).

DISCUSSION

Explantation and reimplantation are currently procedures that every CI center has to deal with, especially high-volume CI centers.[1] When indicated, ERI is a worthwhile procedure because the literature shows how the hearing outcomes of the new device appear to be comparable or even better than those of the removed CI.[6] Outcomes of the reimplanted device depend on the causes of the ERI[5] and the accuracy with which the new CI positioning has been performed.[7]

The ERI surgical procedure itself is generally deemed as "safe,"[3] and not related to specific complications.[7] However, the procedure poses certain challenges when compared to surgery in a never previously operated ear. Technical refinements are suggested to deal with these challenges. Cotè et al[9] identified cochlear fibrosis and new osteogenesis as the principal issues the surgeon encounters when performing ERI. Some of their cases required revision of the cochleostomy, removal of cochlear fibrosis, or drilling of the basal turn. Yeung et al[5] reported that their series required posterior tympanotomy revision due to facial recess bony regrowth in 21% of cases and cochleostomy revision in 34%. According to Alexiades et al,[10] significant scar tissue may be present around the array, facial recess, or cochleostomy. They suggested that cutting the cable "away from the electrode array" may facilitate the removal of the old CI and placement of the new one. Olgun et al[4] recommended caution around the early removal of the array, which could cause soft tissue to collapse near the cochleostomy. The latter might be already hidden by new bone formation and scars, which makes the electrode uncovering process and CI repositioning demanding. The intraoperative finding of post-surgical altered anatomy may pose additional difficulties in identifying clear-cut anatomical landmarks.

MAIN POINTS

- Cochlear implant explantation and reimplantation (ERI) are increasingly frequent procedures.
- Yet described as safe, the ERI procedure poses some surgical challenges.
- Premature removal of the array from the cochlea needs to be carefully avoided.
- To start the surgery with a transmeatal transection of the cochlear implant cable prevents premature removal of the array, resulting in a surgical procedure that may be quicker and easier to perform.
- The first experience seems promising and does not reveal any specific complications.

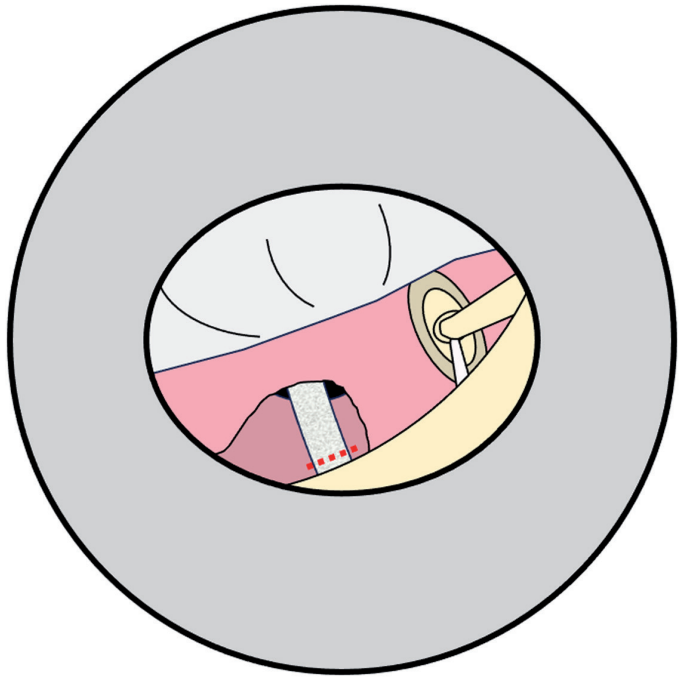

Figure 2. Illustration depicting the transmeatal view of the cochlear implant cable after elevation of the tympanomeatal flap. The dashed red line indicates the designated transection point.

In this paper, the focus is on the crucial aspect of avoiding the early explantation of the array until the new one is ready for insertion, after every unfavorable condition has been identified and solved. This facilitates a prompt, easy, and effective positioning of the new array even through the small opening of the cochleostomy, where the fibrous tissue formed nearby may enhance the difficulties and lead to the necessity for cochleostomy revision or further basal turn drilling. A careful and gradual dissection of the array from the soft tissue scar in the mastoid and precise drilling of the newly-formed bone in the cavities is often required in the ERI procedure, with the aim of avoiding traction on the array and preventing its inadvertent removal before the appropriate time. It is suggested to precede the procedure with the transmeatal cable section as a simple but useful technical refinement. This offers the advantage of allowing for the early and safe removal of the cable portion in the mastoid, enabling the surgeon to address scar tissue and new bone formation without

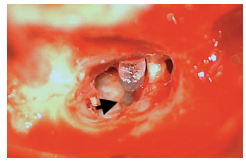

Figure 3. The distal part of the cochlear implant, identified through the posterior tympanotomy after revision of the mastoid cavity (left ear). Black arrow: the round window.

the hindrance of the cable and without the risk of early removal of the array. Alternatively, after the transmeatal cable section, the operator may choose to leave in place the cable in the mastoid, to guide the surgeon toward posterior tympanotomy, again without the risk of early removal of the array in the cochlea. This surgical tip can streamline the revision of the mastoid cavity and expedite access to the posterior tympanotomy. Here, the proximal part of the cable can be detected and preserved until the surgeon is ready for reimplantation.

The surgical tip that is proposed is intended to provide a benefit in both simultaneous and sequential ERI. In the latter case, it is essential that the previous explantation was limited to the receiver/stimulator, and the cable, cut near its emergence from the receiver/stimulator, was left in place. Alternatively, the transmeatal transection of the array can also be performed as part of the explantation surgery step in a sequential ERI.

To date, this tip has been applied in the last 8 cases managed in this clinic. It was observed that the time spent on the transmeatal phase is more than offset by the time saved in the retroauricular phase, enhancing the efficacy and safety of the re-insertion procedure. Despite the consequential risk, albeit rare and limited, of sequelae linked to the addition of a preliminary transmeatal approach, such as tympanic membrane perforation or wound infections, no specific complications were experienced in this series. The low numerosity did not allow for a statistical validation of the procedures. However, even with a wider series, measurable surgical benefits from the implementation of transmeatal transection of the array may be difficult to assess. Feedback from surgeons on this proposal is the only way to determine its usefulness.

CONCLUSION

Cochlear implantation ERI are safe and successful procedures, but they present certain technical challenges, particularly regarding the temporary safeguarding of the cable to be explanted. By implementing a transmeatal sectioning of the array before the standard procedure, the array can be separated in the mastoid and removed, while preserving the part in the cochlea. Pending surgeons' feedback, this simple, uneventful, and straightforward surgical tip may be considered as one option to enhance the safety and success of ERI procedures, which must inevitably be part of a CI surgeon's skill set.

Data Availability Statement: The data that support the findings of this study are available on request from the corresponding author.

Ethics Committee Approval: This study was approved by the Ethics Committee of Azienda Ospedale Università Padova, (Approval number: 483n/AO/24; Date May 09, 2024).

Informed Consent: /Written informed consent was obtained from the patientswho agreed to take part in the study.

Peer-review: Externally peer-reviewed.

Author Contributions: Concept – S.C., S.F.; Design – S.C.; Supervision – E.Z.; Resources – S.F.; Materials – S.F., S.C.; Data Collection and/or Processing – S.C.; Analysis and/or Interpretation – S.C., S.F., ; Literature Search – S.C., S.F.; Writing – S.C., S.F., E.Z.; Critical Review – E.Z., S.F.

Acknowledgments: The authors thank Ms. Alison Garside for reviewing the English language.

Declaration of Interests: The authors have no conflicts of interest to declare.

Funding: The authors declared that this study received no financial support.

REFERENCES

1. Liu H, Yao X, Kong W, et al. Cochlear reimplantation rate and cause: a 22-year, single-center experience, and a meta-analysis and systematic review. *Ear Hear*. 2023;44(1):43-52. [CrossRef]
2. Hermann R, Coudert A, Aubry K, et al. The French National Cochlear Implant Registry (EPIIC): cochlear explantation and reimplantation. *Eur Ann Otorhinolaryngol Head Neck Dis*. 2020;137(suppl 1):S45-S49. [CrossRef]
3. Sorrentino T, Côté M, Eter E, et al. Cochlear reimplantations: technical and surgical failures. *Acta Otolaryngol*. 2009;129(4):380-384. [CrossRef]
4. Olgun Y, Bayrak AF, Catli T, et al. Pediatric cochlear implant revision surgery and reimplantation: an analysis of 957 cases. *Int J Pediatr Otorhinolaryngol*. 2014;78(10):1642-1647. [CrossRef]
5. Yeung J, Griffin A, Newton S, Kenna M, Licameli GR. Revision cochlear implant surgery in children: surgical and audiological outcomes. *Laryngoscope*. 2018;128(11):2619-2624. [CrossRef]
6. Patnaik U, Sikka K, Agarwal S, Kumar R, Thakar A, Sharma SC. Cochlear re-implantation: lessons learnt and the way ahead. *Acta Otolaryngol*. 2016;136(6):564-567. [CrossRef]
7. Concheri S, Brotto D, Ariano M, et al. Intraoperative measurement of insertion speed in cochlear implant surgery: a preliminary experience with cochlear SmartNav. *Audiol Res*. 2024;14(2):227-238. [CrossRef]
8. Balkany TJ, Hodges AV, Gómez-Marín O, et al. Cochlear reimplantation. *Laryngoscope*. 1999;109(3):351-355. [CrossRef]
9. Côté M, Ferron P, Bergeron F, Bussières R. Cochlear reimplantation: causes of failure, outcomes, and audiologic performance. *Laryngoscope*. 2007;117(7):1225-1235. [CrossRef]
10. Alexiades G, Roland JT, Fishman AJ, Shapiro W, Waltzman SB, Cohen NL. Cochlear reimplantation: surgical techniques and functional results. *Laryngoscope*. 2001;111(9):1608-1613. [CrossRef]