

Medullary thyroid carcinoma

Maria Rosa Pelizzo, Esmeralda Isabella Mazza, Caterina Mian & Isabella Merante Boschin

To cite this article: Maria Rosa Pelizzo, Esmeralda Isabella Mazza, Caterina Mian & Isabella Merante Boschin (2023) Medullary thyroid carcinoma, Expert Review of Anticancer Therapy, 23:9, 943-957, DOI: [10.1080/14737140.2023.2247566](https://doi.org/10.1080/14737140.2023.2247566)

To link to this article: <https://doi.org/10.1080/14737140.2023.2247566>



© 2023 The Author(s). Published by Informa UK Limited, trading as Taylor & Francis Group.



Published online: 30 Aug 2023.



Submit your article to this journal [↗](#)



Article views: 478



View related articles [↗](#)



View Crossmark data [↗](#)

Medullary thyroid carcinoma

Maria Rosa Pelizzo, Esmeralda Isabella Mazza, Caterina Mian and Isabella Merante Boschin

Department of Surgical, Oncological and Gastroenterological Sciences, University of Padova, Padova, Italy

ABSTRACT

Introduction: Medullary thyroid carcinoma (MTC) constitutes approximately 5–10% of all thyroid cancers. Although the tumor forms in the thyroid, it doesn't originate from thyroid cells, but from the C cells or parafollicular cells which produce and release a hormone called calcitonin (CT). Starting from the second half of the 1900s, MTC was progressively studied and defined.

Areas covered: This study aims to analyze the history, clinical presentation and biological behavior of MTC, bio-humoral and instrumental diagnosis, molecular profiling, genetic screening, preoperative staging and instrumental procedures, indispensable in expert and dedicated hands, such as high-resolution ultrasonography, CT-scan, MRI and PET/TC. We examine recommended and controversial surgical indications and procedures, prophylactic early surgery and multiple endocrine neoplasia surgery. Also, we discuss pathological anatomy classification and targeted therapies. The role of serum CT is valued both as undisputed and constant preoperative diagnostic marker, obscuring cytology and as early postoperative marker that predicts disease persistence.

Expert opinion: With a complete preoperative study, unnecessary or useless, late and extended interventions can be reduced in favor of tailored surgery that also considers quality of life. Finally, great progress has been made in targeted therapy, with favorable impact on survival.

ARTICLE HISTORY

Received 28 March 2023
Accepted 9 August 2023

KEYWORDS

Medullary thyroid cancer; calcitonin; RET; MEN; thyroidectomy; cervical lymph node metastases; targeted therapy

1. Introduction

MTC accounts for 5–10% of thyroid carcinomas and 0.4–1.4% of all thyroid nodules. It is located in the thyroid but it originates from C cells or parafollicular cells that secrete calcitonin (CT); C cells are dispersed in the stroma of the thyroid between thyroid follicles, predominantly at the upper poles of the thyroid [1–3].

The term *medullary*, used for tumors of intermediate malignancy, was intended by Hazard in 1959 to mitigate the undifferentiated pathological appearance of an unusual solid thyroid carcinoma [4]. This type of tumor was first identified half a century earlier based on its intracellular amyloid component by Jacquet, who described a form of thyroid tumor *rich in amyloid and with lymph node metastases* in 1906, and by Stoffel, who reported a case of thyroid tumor *with non-papillary and non-follicular amyloid* in 1910 [5,6].

Hazard, Hawk and Crile, who first described it, named it *Medullary Thyroid Carcinoma* in 1959, reporting 21 cases of this new solid, non-follicular thyroid tumor, with amyloid substance in the stroma and a high incidence of central lymph node metastases [4].

Other reports noted a high frequency of lymph node and distant metastases. In particular, Horn, in 1951, reported 7 cases of thyroid tumor with a distinctive morphological variant; Brandeburg, in 1954, reported a case of *metastasizing amyloid goiter*; and Laskovsky, who in 1957 reported 5 cases

of thyroid tumor he defined as *carcinoma hyalinicum thyroideae* [7–9].

Williams, in 1966 clarified the origin of MTC from the parafollicular neuroendocrine cells of the thyroid, which were discovered by Baber in the late eighteenth century and described as *parenchymal cells* of neural crest origin [10–12]. Williams hypothesized that this could explain the differences observed between MTC and papillary and follicular thyroid carcinoma [11].

Pearce demonstrated the embryological origin of C cells from the fourth branchial pouches and, through immunofluorescence, he documented the presence of a peptide capable of lowering *calcium tone* that was initially called *calci-tonin*, attributing its secretion to the parathyroid glands [13,14]. It was later renamed *thyro-calcitonin* to emphasize thyroid origin [15,16].

In 1968, Melvin observed a high concentration of the hypocalcemic factor compared to normal thyroid tissue, in the biopsy liver metastasis in a MTC with associated bilateral pheochromocytoma (PHEO) [17]; it was observed that high levels were also present in the plasma. Others reported that CT levels, in patients with MTC, were elevated both in plasma and in tumor tissue compared to normal thyroid tissue and that, upon removal of the tumor, CT levels returned to normal level [18,19]. Based on these studies and the contributions of other authors, MTC was defined as a neuroendocrine tumor of parafollicular origin secreting CT [20–22].

Article highlights

- Medullary thyroid cancer (MTC) originates from parafollicular cells which produce and release calcitonin (CT) and, less consistently, carcinoembryonic antigen (CEA).
- About 70% of patients with sporadic MTC who present clinically as a palpable thyroid nodule, already have cervical lymph node metastases and 10% have distant metastases.
- Hereditary MTC occurs in 20–25% of cases and it is caused by a genetic mutation of the RE arranged during Transfection (RET) proto-oncogene. It includes a kind of familial MTC and a syndrome characterized by multiple endocrine neoplasms (MEN). Family screening, based on RET mutation, is aimed at early or prophylactic pre-clinical surgery, with different timings in relation to the mutation present.
- Total thyroidectomy with central compartment lymph node dissection is considered the standard treatment. The indication and extension of lateral cervical lymph node dissection is controversial, but guided by CT values.
- New targeted therapies with tyrosine kinase inhibitors (TKI) have emerged for MTC with significant tumor burden and disease progression. Studies are ongoing on selective RET inhibitors, immunotherapeutic drugs and Peptide Receptor Radionuclide Therapy (PRRT) with radiolabeled somatostatin analogues.
- In future perspectives, the recent advent of genetic editing and gene modulation plays an important role.

CT, which was discovered in an another context by Copp in 1962, used in the treatment of bone metabolism and pain, almost by chance and independently, since then it assumed the role of a sensitive tumor marker [14].

1.1. Clinical presentation and biological behavior

MTC is the third most common thyroid carcinoma, after papillary and follicular carcinoma, but rarer. It includes a predominant sporadic variety and a hereditary one. MTC originates from C-cells and does not share the metabolic characteristics of follicular thyroid cells, such as the ability to fix iodine-131. Instead, MTC cells express CT and, less consistently, carcinoembryonic antigen (CEA) [23].

MTC presents in sporadic form in 75–80% of cases, with an incidence peak between the fourth and sixth decades of life [24], generally as a unifocal tumor (75–90%) with early lymph node involvement (central compartment between 11% and 86%, and lateral cervical compartment between 11% and 93%) [23,25–28].

The common clinical onset is a thyroid nodule, without other specific symptoms. However, in some cases, hoarseness due to recurrent laryngeal nerve paralysis, persistent diarrhea and/or skin flushing may occur, indicating advanced or already metastatic disease [25,29,30].

Central and lateral cervical lymph node metastases are reported with variable frequency, affecting respectively up to 11–14% of T1 patients (AJCC TNM classification) and up to 86–93% of T4 patients [26,31,32]; it is also reported that about 70% of patients with sporadic MTC who present clinically as a palpable thyroid nodule, already have cervical lymph node metastases and 10% have distant metastases [27,33]. Liver, bone, and lung are preferred sites of hematogenous metastases, of which bone metastases are the most unfavorable [34].

The biological behavior of sporadic MTC is considered unpredictable: alongside a minority of MTC that, even if voluminous, but always intra-thyroid and without metastases, show a favorable course and can benefit from absolutely curative conservative treatments, there are cases with intermediate behavior, with stable residual disease after surgery, sometimes only biochemical, meaning with increased calcitonin levels; others are difficult to control, with progressive or multi-recurrent disease despite extensive and iterative surgery. The number of patients undergoing one or more reoperations for persistence/recurrence and the number of reoperations per patient reported in the literature are high [29,35,36]. It is commonly believed that surgical removal occasionally eradicates the tumor and, in many cases, despite further surgical interventions, patients continue to have elevated CT values after surgery. Duhet reported 80 reoperations in 25 patients with an average of 3.2 [37]. In another study including 136 patients operated on over 30 years, 77 (56.6%) had residual disease and 25 (18.4%) underwent reoperation; some of the 25 patients were reoperated multiple times, and a total of 33 reoperations were performed [38]. According to Machens and Dralle, reoperation for persistent MTC is beneficial for serum CT values less than or equal to 1000 pg/mL, in those patients who did not undergo adequate lymph node dissection during the first surgery. Reoperation for systematic lymph node dissection, performed by experienced hands, can allow biochemical cure rates ranging from 18% to 44%, with acceptable surgical morbidity [39,40].

It is unclear, in the absence of prospective studies, to what extent reoperations for locoregional tumor persistence or recurrence reduce the risk of subsequent disease recurrence or extend disease-free survival or prolong overall survival. In fact, as long as metastatic MTC is asymptomatic, 10-year survival rates are higher than 80%. Therefore, the need for a new operation must be deliberated in light of the circumstances of the case, particularly the individual patient's risk, the type and extent of previous surgeries and the characterization of the tumor recurrence [39].

Prognosis, in univariate analysis, is directly correlated with the patient's age at the time of diagnosis, male gender, local invasion of the tumor, cervical lymph node metastasis and distant metastasis [34,41,42]; however, in multivariate analysis, only the patient's age and disease stage at the time of diagnosis are independent prognostic factors [43–45].

The 10-year overall survival rate for patients with MTC at stages I, II, III, and IV, according to the staging of the AJCC, is respectively 100%, 93%, 71%, and 21%. Of the patients who underwent surgery, 43% is biochemical disease-free, meaning with normalization of calcitonin levels. Survival in patients with biochemical normalization is excellent: 98.9% at 5 years, 97.7% at 10 years; in patients with persistent biochemical disease (57%), survival is respectively 80.2% and 70.3% at 5 and 10 years [44]. In other studies, the 10-year survival for stages I, II, III, IV is respectively 100%, 100%, 66%, and 48%. The overall 10-year survival rate is 72% and 52% at 20 years [32,34,45].

Hereditary MTC (20–25% of cases) is multifocal, bilateral, associated with C-cell hyperplasia; it includes a kind of MTC defined as familial (FMTC) and a multi-endocrine kind, as a constant malignant component of multi-endocrine syndromes

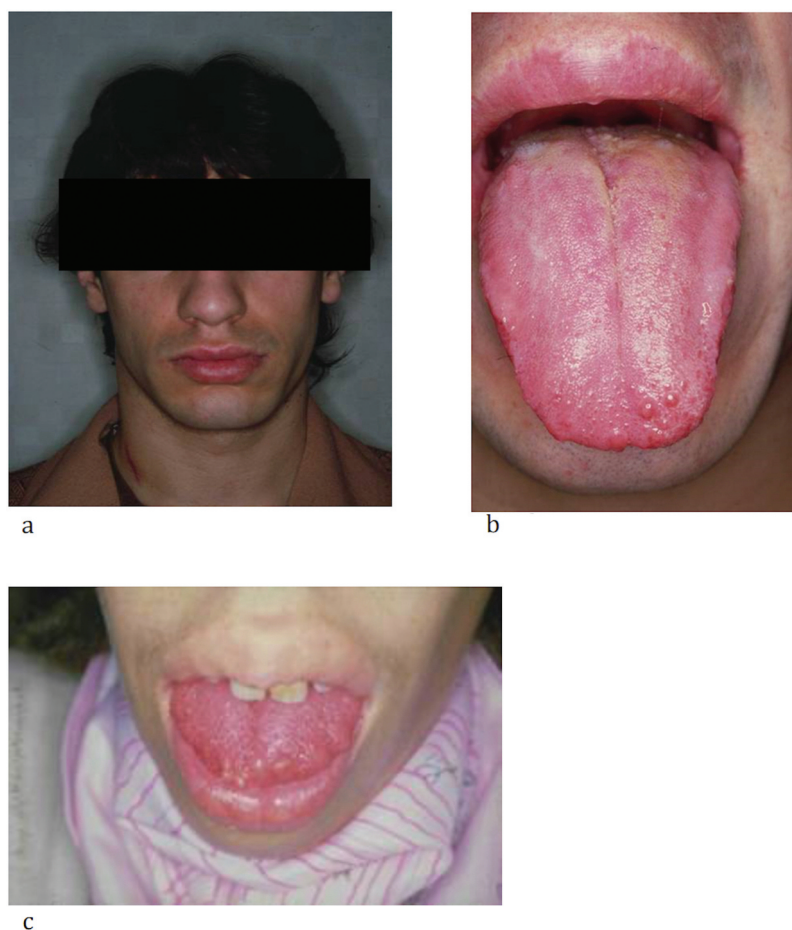


Figure 1. Marfanoid facies (a), mucous neuromas (b, c).

known as *multiple endocrine neoplasia* (MEN) with not necessarily synchronous clinical expression [46,47].

There is a MEN 2A syndrome or Sipple syndrome (60% of MEN) and a MEN 2B syndrome or Wagenmann-Froboese syndrome. MEN 2A is characterized by the association of MTC with an inconsistent occurrence of pheochromocytoma (PHEO), present in about 50% of cases and mild and late-onset primary hyperparathyroidism (pHPT), present in about 20% of cases; cutaneous lichen amyloidosis (CLA) and Hirschsprung's disease (HSCR) can be associated in 15–20% of cases. In MEN 2B, MTC is associated with PHEO in 50% of cases, mucosal neuromas, intestinal ganglioneuromatosis, corneal nerve hypertrophy and a distinctive marfanoid habitus [48] (Figure 1).

The clinical behavior of MTC varies among the three syndromes: it is aggressive and has an unfavorable prognosis in MEN 2B, intermediate in MEN 2A, and indolent in most patients with FMTC, also thanks to the contribution of molecular screening to early diagnosis. Some studies in the literature have reported no mortality in MEN 2A cases, even in the presence of disease persistence or recurrence [34,49].

The pathogenesis of hereditary MTC is caused by a genetic mutation with autosomal dominant transmission and variable penetrance of the REarranged during Transfection (RET) proto-oncogene. To date, over 100 mutations, duplications, insertions, or deletions in RET gene have been identified in

hereditary MTC, which are correlated with different phenotypes [50].

The RET proto-oncogene encodes for transmembrane receptor of the tyrosine kinase family [51,52]. Takahashi et al. identified and described the RET oncogene in 1985 [53]. Less than a decade later, it was found that all MEN2A, MEN2B and FMTCs have germline RET mutations and approximately 50% of sporadic MTCs have somatic RET mutations [54–60].




Furthermore, some research group identified that in 11–24% of sporadic MTC without somatic RET mutations, there are somatic mutations of HRAS, KRAS, or rarely NRAS [61–63]. RET is also an oncogene involved in other malignant and nonmalignant diseases [64–68].

The onset mode of hereditary MTC is generally similar to the clinical one of sporadic. It changes with molecular familial screening that allows for the simultaneous identification of relatives with already humoral or structural disease as well as asymptomatic carriers of the mutation in the preclinical phase, with favorable therapeutic and prognostic outcomes [34].

For the prognosis of MTC, the key factor is the earliness of diagnosis, which can be aided by two allies: a constant serum marker, CT, and a molecular genetic marker, RET mutation.

Another serum tumor marker, associated with CT but less constant and predominantly gastrointestinal marker is (CEA). It has unfavorable impact and it is considered a sign of dedifferentiation and distant metastasis [25,33].

Table 1. RET e ATA risk [33].

RET receptor	Codon	Exon	ATA Risk
Extracellular domain 	533	8	MOD
	609	10	MOD
	611	10	MOD
	618	10	MOD
	620	10	MOD
	630	11	MOD
	631	11	MOD
Transmembrane domain 	634	11	H
	666	11	MOD
Intracellular domain 	768	13	MOD
	790	13	MOD
	804	14	MOD
	883	15	H
	891	15	MOD
	912	16	MOD
	918	16	HST

Note: RET, REarranged during Transfection protooncogene. ATA, American Thyroid Association. MOD, moderate. H, high. HST, highest.

Family screening is based on the genetic marker of the RET mutation, aimed at *early* surgery, which is reserved for subjects with the mutation and thyroid micro-nodularity on ultrasound and subjects with a positive basal or stimulated CT. Family screening can be also aimed at *prophylactic* pre-clinical surgery, in asymptomatic carriers of the mutation, meaning without ultrasound and bio-humoral evidence of disease [49].

The American Thyroid Association (ATA) has identified three categories of risk for developing MTC: *highest risk* (ATA-HST), *high risk* (ATA-H) and *moderate risk* (ATA-MOD) (Table 1) [60,69]. This classification, together with the serum CT levels, is essential for better planning of screening and therapeutic strategies.

1.2. Diagnosis

From a diagnostic point of view, CT plays the main role as a sensitive and constant marker, reliable both for preoperative diagnosis of MTC and early postoperative verification of surgical radicality, as well as for follow-up to detect persistence, progression or recurrence of biochemical disease [70–72].

CT, synthesized from the polypeptide precursor procalcitonin (proCT), represents the most sensitive marker for the recognition of MTC. The frequency of MTC not associated with hypercalcitoninemia is only 0.8% [73] [74]. However, it is not equally specific in those clinical contexts where the serum increase is moderate [75].

The CT negative MTC is rare and found in isolated case reports or small series: Gambardella et al. in 2019 summarized the literature up to 2019 and found 51 cases [76]. Recently, in 2022, Yue and Zhang, compared 24 CT-negative MTC vs 288 CT positive MTC: in accordance with others, they underline the possibility of defect in CT synthesis or secretion with aberrant forms of CT and precursor peptides [77,78]. According to other recent reports some CT negative small

MTCs represent an entirely different entity, such as an Ewing family tumor showing translocation of EWSR1-Fli1. The designation CEFTE has been suggested for these lesions (carcinoma of thyroid with Ewing family tumor elements). Some reported examples are apparently 'pure' Ewing/PNET: immunostain results reported show all examples have membrane staining for CD99 [79].

The measurement of CT is subject to several pre-analytical, analytical, and post-analytical issues. From a pre-analytical point of view, there are various physiological and pathological conditions, other than MTC that can be associated with modest increases in CT level, such as male gender, smoking, acute alcohol ingestion, the use of certain medications (proton pump inhibitors, beta-blockers and corticosteroids) and thyroid and non-thyroid diseases (including hypergastrinemia, hypercalcemia, neuroendocrine tumors, small and large cell lung tumors and renal insufficiency) [80].

From an analytical point of view, the new two site/two steps chemiluminescent immunoassay (CLIA) or immunoradiometric assay (IRMA) platforms are more specific for the measurement of the *mature* CT molecule, although they are not immune from possible interferences such as those related to the presence of heterophilic antibodies or macro-CT [81,82]. Finally, additional analytical limitations are related to the short half-life of CT, about 15–40 minutes, which varies considerably in relation to its concentration, its variability during the day, and its instability at room temperature, which requires rigorous maintenance of the cold chain before dosing [83,84].

Therefore, to reduce problems related to low specificity, especially in case of moderate increases in CT, confirmation by performing a stimulus test is required. However, even in this case, some critical issues should be underlined. For at least two decades, the stimulation test has been performed through the infusion of pentagastrin, a synthetic analogue of gastrin that is no longer used [85,86]. Currently, the stimulation test is performed in third-level centers through the rapid infusion of calcium gluconate (2.3 mg of elemental calcium/Kg of body weight infused at a rate of 5 mL/min for at least 3 minutes), with basal CT dosage and after 2, 5, and 10 minutes. The CT response to calcium stimulation is similar, if not even more intense than that after pentagastrin and allows to distinguish normal individuals and carriers of C-cell pathology [87,88]. Although this test is considered safe, very rare and even severe side effects have been reported in the literature, including a case of cardiac arrest, therefore, ECG monitoring is recommended during the entire test execution [89,90]. Despite standardization of this procedure, shared and reliable cutoffs for demonstrating the presence of MTC are still lacking in literature.

However, systematic dosage of CT in all patients with thyroid disease, due to the high prevalence of thyroid disease (10% of the adult population) and the rarity of MTC, is not widely shared [25,91,92].

The reliability of elevated marker values allows for neglecting and even avoid the cytological examination on fine-needle aspiration, which does not appear sufficiently sensitive for MTC, being associated with a positive or suspicious result rate of only 56.4% [93].

If the cytology result is inadequate (TIR I, according to the Bethesda classification) or indeterminate (TIRIII), cytological review is suggested, in light of the diagnostic contribution of CT, or intralesional CT assay on eluate may be preferred as reported in a pilot study by Boi et al., in 2007, with sensitivity and specificity compared to cytology of 100% vs 61.9% and 100% vs 80%, respectively [25,91,94]. Similarly, in 1968 Melvin, reported the case of a patient with MTC, bilateral PHEO and liver metastasis, with high hypocalcemic activity associated with high levels of CT on biopsy [17].

The short half-life of the molecule (between 15 and 40 minutes) allows for predicting the radicality of the surgery already on discharge; it's significant the value on the second postoperative day and validated at 1 month to allow the very high basal values to reduce and normalize [42].

It is now a constant practice, when high CT values are found, to associate the measurement of serum CEA. The thyroid is its extra-intestinal site of production easiest to document. On the other hand, occasional findings of elevated CEA levels should be investigated, before proceeding with invasive gastroenterological endoscopic and radiological studies, by also measuring serum CT levels. Elevated CEA levels are attributed not only a diagnostic role, already provided by the CT, but also a negative prognostic one, to be considered in the therapeutic strategy [25,33].

In the early postoperative phase, the measurement of CEA is not included, being a protein, it's postponed to 1 month, on the basis of the half-life [95].

Elevated levels of Carbohydrate Antigen 19-9 (CA 19-9) have also been observed in patients with advanced MTC and poor prognosis [25,33]. Furthermore, due to the neuroendocrine origin of MTC, it can express chromogranin, neuron-specific enolase (NSE), somatostatin, gastrin-releasing peptide (GRP) and vasoactive intestinal peptide (VIP). Other peptides produced by MTC contribute to the onset of some specific clinical manifestations, such as VIP, serotonin and prostaglandins which favor flushing and diarrhea, while adrenocorticotrophic hormone (ACTH) can cause ectopic Cushing's syndrome [25,33,96,97].

Rare cases of CT-negative MTC are described: a review in 2015 collected 18 cases of CT-negative MTC, reported in the literature from 1997 to 2014, accounting for 0.8%. The authors conclude by recommending, in case of suspicion of CT-negative MTC, measurement of pro-CT, stimulated CT, CEA and other neuroendocrine biomarkers such as chromogranin A, in addition to measuring CT on fine needle aspiration of the suspicious node [74,98].

1.3. Preoperative staging

The first surgical operation is considered the golden opportunity, for which the imprudent haste to operate must be replaced by cautious planning. It is essential, also for repercussion on basic research, to complete the bio-humoral, instrumental, genetic diagnosis, staging both the malignant component of MTC and the concomitant other MEN components in RET-mutated patients, of which PHEO represents the dangerous and potentially fatal component, if ignored.

The acquisition of high CT values, even before ultrasound and without cytological diagnosis or CT dosage on eluate,

justifies serum CEA measurement and, in MEN perspective, parathyroid hormone (PTH), calcium and urinary metanephines, waiting for molecular genetic analysis to indicate any positivity and risk class [33,34].

In the absence of a parameter that evaluates the secretory capacity of tumor cells, the serum CT level has been correlated to the diameter/volume of the primary focus, presence/absence of cervical, mediastinal and distant metastases, but without discriminating the respective contribution to the overall tumor burden. In 2010, Machens and Dralle published a study that showed how CT levels increased with the increase in volume of MTC, number and sites of lymph node metastases; CT values greater than 20 pg/mL, 50 pg/ml, 200 pg/ml, and 500 pg/ml were associated with lymph node metastases respectively in the homolateral central and laterocervical compartment, in the controlateral central, in the controlateral laterocervical and in the upper mediastinum [26].

From an instrumental point of view, high-resolution ultrasound (HRUS) of the neck represents the basic staging procedure: it is aimed at evaluating the structure and dimensions of the primary MTC, plurifocality prevailing in hereditary forms, extracapsular development and above all the site of lymph node metastasis [33].

Lymph node metastases, sometimes microscopic and difficult to document even by expert operators and adequate instruments, contribute to surgical failure. HRUS analysis uses morphological criteria of suspicion widely shared and standardized by the TIRADS system (Table 2) and it locates, on a map, the findings in the compartments of the neck, divided into central, unilateral and bilateral laterocervical, based on coded imaginary planes that separate them (Figure 2) [99,100].

Uncertain data, especially for the lateral cervical chains, can be integrated with intra-lesion CT sampling on eluate [98].

HRUS is also commonly extended to the liver, which is the target site. Before CT-scan, liver micro-metastases were previously documented with laparoscopy and even trans-femoral venous sampling [101].

CT sampling at the cervical jugular, supra and subhepatic cava vein, were used to intercept and localize sites of marker production, such as metastases or disease recurrence following negative or dubious morphological imaging [102]. In 1989, Ben Mrad et al. used this technique in 16 patients to locate the

Table 2. EU-TIRADS categories and risk of malignancy [100].

Category	Ultrasound features	Clinical risk	Risk of malignancy (%)
1	No nodules	Normal	None
2	Cyst, spongiform	Benign	0
3	Ovoid, smooth, isoechoic/hyperechoic	Low risk	2-4
4	No features of high suspicion Ovoid, smooth, mild hypoechoic	Intermediate risk	6-17
5	No features of high suspicion At least 1 of the following items: • Irregular shape • Irregular margin • Microcalcification • Marked hypoechoogenicity, solid	High risk	26-87

Note: EU-TIRADS, European Thyroid Imaging Reporting and Data System.

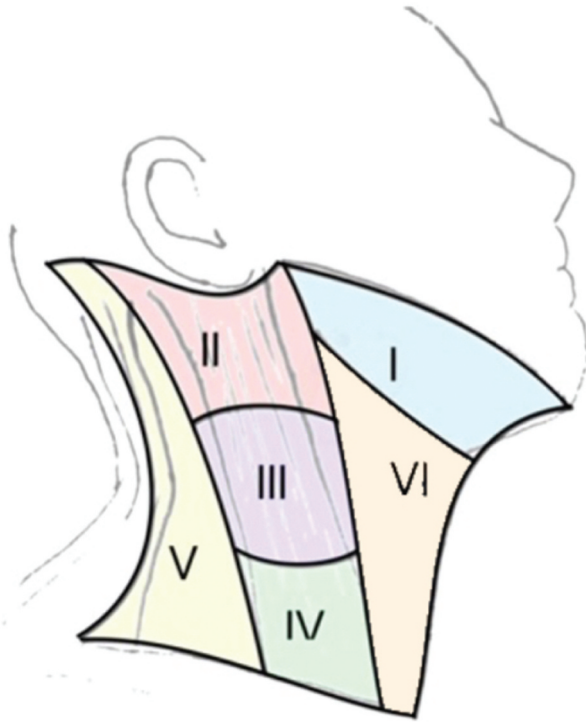


Figure 2. Cervical lymph node groups.

site of CT production and, after surgical treatment, to verify marker negativization [103].

HRUS also focuses on parathyroid involvement and, recently, in 2022 a pilot study reported it as a noninvasive alternative method to the current laryngoscope evaluation of vocal cord motility [103].

Except for rare cases of sub-centimetric intrathyroidal MTC and modest levels of CT, total body CT scan with contrast, including the chest, liver, adrenals, skeletal system is the next staging investigation [104].

The following step is integration with PET/CT: F-18 DOPA, Ga68-DOTA-labeled somatostatin analogs and F-18 FDG PET/CT for diagnostic and prognostic purposes, where DOPA positivity is a biologically favorable factor, but also significant for complementary or alternative radio-receptor-based treatment choices [105].

F-18-DOPA is an alternate PET agent that targets the L-type amino acid transporter, which is expressed in MTC: it is considered the most accurate to detect recurrent/metastatic MTC, particularly liver and cervical lymph node metastases.

F-18 DOPA PET is superior to F-18 FDG PET in the evaluation of metastases and recurrences of MTC, with a sensitivity of 72% vs. 52%. F-18 FDG accumulates in neoplastic cells as an energy reserve, reflecting their proliferative activity, but neuroendocrine tumors (NET), including MTC, often have a low F-18 FDG uptake.

Ga68-DOTA-labeled somatostatin analogs (DOTATATE, DOTATOC and DOTANOC) demonstrating increased somatostatin receptor (SSTR) expression of neuroendocrine tumor cells are relatively new PET tracers with higher sensitivity and specificity for MTC recurrence. Particularly Ga6-DOTATATE with high affinity for SSTR2, widely available for neuroendocrine imaging, may be used to evaluate for metastatic MTC [106]. A

recent study compared PET imaging with F-18 DOPA (FDOPA) and Ga-68 DOTATATE (TATE) on 46 MTC patients with elevated CT and/or CEA levels during follow-up who had both FDOPA and TATE PET/CT scans for re-staging purposes. FDOPA PET imaging was significantly superior in detecting liver and regional lymph node metastases, while TATE PET scan was significantly better in the skeletal metastases [107–109].

MRI has a high resolving power in the suspicion of infiltration of local structures such as trachea and esophagus, generally studied using endoscopic techniques, including video-laryngo-tracheoscopy, which also evaluates laryngeal motility [104]. Contrast-enhanced liver-specific MRI is complementary to CT-scan for identifying and better defining liver lesions and it is recommended for bone metastases. Bone scintigraphy is a cost-effective and reasonably sensitive alternative for detecting bone metastases [110].

The aim of staging is to base the extent of surgical intervention on the instrumental stage of the disease rather than the predictive value of CT.

The goal is to avoid unnecessarily extended surgery in patients without metastases, meaning overtreatment, believing that after a *central* approach, radicalizing the persistence/recurrence of nodal disease in a virgin lateral area, does not expose the patient to greater complications than primary surgery and does not affect prognosis. The other purpose of staging is to promote radical surgical intent at one time and prevent insidious re-interventions.

1.4. Surgery

Literature reports cases of MTC stably cured and followed with persistent normalization of CT after simple thyroid lobectomy, indicating the existence of a benign adenoma-like variant without the need for completion re-intervention [111,112].

In the past, for economic reasons, it was common practice to delay processing preoperative venous samples for calcitonin testing in patients undergoing thyroid surgery until the calcitonin testing kit was exhausted to be then processed all together: the positivity of the test, although discovered later, contributed to the not always easy histological diagnosis of MTC and persistent postoperative negativity prevented further surgery. A negative preoperative CT value excluded or cast doubt on the diagnosis of MTC, if it was made or suspected histologically [41,101].

The need for radicality and risk and benefit evaluation should drive the choice of surgical approach for each individual case with a tailored and safe surgical approach respectful of quality of life [113].

Total thyroidectomy with central compartment lymph node dissection, level VI (Figure 2) is considered the standard treatment with the aim of avoiding reoperation in the thyroid

bed, cause of the isolation and preservation of the laryngeal nerves and parathyroid glands in a second surgery would be more difficult and riskier [33].

In 2004 Rosato et al. published a retrospective observational multicenter study on 14,934 patients underwent thyroidectomy in Italy since 1995 to 2000: 9599 (64.3%) total thyroidectomies (TT) and 1911 (13%) with malignant pathology, MTC in 95 (5%).

Symptomatic hypocalcemia was seen in 14% after TT, transient in 11.8% and permanent in 2.2%; recurrent laryngeal nerve (RLN) lesions occurred in 4.3% after TT, 2.4% transient and 1.3% definitive; hemorrhage occurred in 1.6% in TT patients; wound infection occurred in 0.4% in TT patients [114]. The risks of central neck dissection (CND) are the same as a thyroidectomy: RLN injury, hypoparathyroidism, and hemorrhage. Although many argue that the risks of a CND are no higher than a total thyroidectomy, especially when an experienced surgeon performed surgery: there is debate about this. Despite the theoretical higher risk, most reports looking at RLN dysfunction or injury after CND have shown that the incidence of permanent nerve injury remains acceptably low at 1–3%. Transient and permanent hypoparathyroidism does appear to be higher when a CND is performed. Studies of transient hypoparathyroidism report this complication in 14–60% of the patients with CND with rates for permanent hypoparathyroidism ranging from 0% to 16% [115,116]. Sippel in a study published in 2009, on seventeen studies involving 1929 patients, concluded that numerous complications are possible after CND: transient hypocalcemia in 3.6% to 60.0% of cases, permanent hypocalcemia in 0.0% to 14.4% of patients, temporary RLN injury in 0.0 to 25.0% of cases, and permanent RLN injury in 0.0% to 11.5% of patients [116].

Lateral cervical metastases are frequent but reported in variable percentages (50–75%), particularly high in reports mainly from reference centers where later cases are referred [1,2,33,109]. In another study, lymph node metastases were reported in 54%, contributing to making the indication and extension of lateral cervical lymph node dissection controversial [101].

Extensive controversy exists on MTC without preoperative locoregional evidence of lymph node metastases and without distant metastases, if lymph node dissection of the lateral compartments (levels II to V) should be considered based on serum CT levels [50]. The ATA guidelines could not attain a consensus agreement on this topic but according to recommendation #25 of ATA guidelines the prophylactic lateral neck dissections may be considered based on serum calcitonin levels [33]. Some of the panelists didn't recommend routine prophylactic lateral neck dissections if there was no evidence of disease on preoperative neck US, nonetheless, according to some members the extent of the surgery and which levels of lymph nodes in the lateral compartments to resect, in mono or bilateral mode, is suggested by CT values [26]: for values between 20 and 200 pg/mL, central and homolateral lymphadenectomy is recommended; for CT between 200 and 500 pg/mL, even contralateral prophylactic dissection, possibly in two stages [33]. In this way, however, it is neglected that the value is influenced not only by cervical metastases, but also by the size of the primitive tumor, its secretory capacity, mediastinal and distant metastases and instrumental support is relegated to a secondary role. The levels of the emptying are also controversial, especially if they include levels II-V vs II-IV or rather all levels or only selective ones [27].

Patients with MTC limited to the neck and cervical lymph nodes should have a total thyroidectomy, dissection of the central compartment lymph nodes (level VI) and dissection of the involved lateral neck compartments (level II to V). When preoperative imaging is positive in the ipsilateral lateral neck compartment, contralateral neck

dissection should be considered if the basal serum CT level is greater than 200 pg/mL (recommendation #26 ATA guidelines) [33].

Alongside CT-guided dissection criteria, on one hand not always necessary (about 40%) and on the other, perhaps, not radical or useless for advanced stages, a strategy of rigorous preoperative staging has been establishing itself, in this era of tailored therapy, which does not neglect the quality of life [113].

Today, more than basal CT threshold levels to guide lymph node dissection, extreme high levels are taken into consideration, especially if associated with high levels of CEA, which seem more appropriate for indicating alternative strategies to the primary surgical option supported in the past, proposing targeted therapies even in neoadjuvant setting [117,118].

The complications of lymph node dissection, even in expert hands, are not negligible both quantitatively and qualitatively; some of these are highly disabling, such as injury to the spinal accessory nerve resulting in *winged scapula* and difficulty in rotating the head (25–50%). The nerve is at risk during dissection of the V level, which is a site rarely and late affected by MTC [119–121].

Other complications include cervical lymphorrhea, particularly severe if caused by injury to the thoracic duct during left-sided lateral cervical lymph node dissection, reported in 0.5–8% of cases [122]. There may also be oral fissure asymmetry (due to marginal branch of the facial nerve injury), deviation and atrophy of the tongue (hypoglossal nerve injury), up to dysarthria if bilateral injury, swallowing impairment (hypoglossal nerve loop injury), irritative cough, expiratory dyspnea, brady/tachycardia and paralysis of the laryngeal nerve (vagus nerve injury), paralysis of the hemidiaphragm (phrenic nerve injury), Claude Bernard Horner syndrome (miosis, ptosis, and enophthalmos) due to definitive damage to the cervical sympathetic, painful and fatigue radicular syndromes due to damage to the brachial plexus [119–121].

The persistence and recurrence of MTC are frequent, often grouped together under the term *recurrence*, while their respective meaning is indicators of the biological behavior of MTC.

Persistence implies a finding of postoperative hyper-CT correctly evaluated by stimulation test, unlike recurrence which assumes a rise after normalization of stimulated CT. Persistence is an indicator of non-radicality, either due to inadequate initial intervention or advanced stage, while recurrence indicates unpredictable biological aggressiveness.

Stable mildly postoperative CT values, associated with stable evidence of structural disease and negative 18FDG PET, can be monitored. Progressive increases require restaging and surgery if resectable disease, or complementary therapies. However, the eradication of advanced MTC remains a chimera that questions complex, interminable, reiterated interventions, as described by Tisell [123].

1.5. Early and prophylactic surgery

The main advantage of prophylactic surgery in MTC, before the C cells hyperplasia turn to carcinoma, is represented by certain and stable healing free from check up. Furthermore, this result is achieved with a less invasive operation without recourse to systematic lymph node dissection of the central

compartment, a procedure which, compared to simple total thyroidectomy, carries a greater risk for parathyroid glands and recurrent nerves. This is the second but no less important purpose of prophylactic surgery [49].

In fact, the problem of surgical timing, meaning when to operate asymptomatic carriers, arises from the concern that the damage, especially to the parathyroid gland in children, may be more severe and relatively more frequent, in the face of a pathology that has not yet appeared and, in any case, slowly evolving [124–126].

Even more uncertain is whether to intervene or not, when discovering an elderly carrier with no clinical evidence of disease, given the low overall mortality of MTC, except for MEN 2B, and the possibility that even a non-early but more extensive surgery may be stably curative.

The literature has identified a scale of aggressiveness of MTC related to the RET mutation, but many points are still unclear, particularly the variable biological behavior within the same family nucleus.

The extent of surgery, timing in prophylactic and early surgery are the direct consequence.

The main guidelines for the management of hereditary MTC recommend total thyroidectomy within the first year/first month of life, with possible central lymph node dissection, for MEN 2B and RET mutation of codon M918, which are considered to be at very high risk [33,46,127]. Total thyroidectomy is recommended within the first 5 years of life for MEN 2A and C634 codon mutation, which are considered to be at high risk and central compartment dissection is indicated if serum CT levels exceed 40 pg/ml or if there is evidence of affected lymph nodes [49]. For patients with familial MTC and RET mutations other than M918T and C634, which are considered to be at moderate risk, CT measurement and neck ultrasound are recommended from the age of five and total thyroidectomy is only performed in case of detectable CT (Table 1) [33].

In subjects with hereditary MTC, the screening protocol for PHEO begins at 11 years of age for ATA-H and ATA-HST and at 16 years of age for ATA-MOD. Imaging investigations are indicated in case of positive biochemical tests [33].

The expression of hyperparathyroidism in MEN 2a compared to MEN 1 is inconsistent, of little significance and delayed [25].

Bio-tumor screening for HPT, which includes total and ionized calcium, phosphorus and intact PTH measurement, is only recommended for MEN 2A, where the codon 634 mutation is the highest risk for IPT expression and it follows the timing of screening for PHEO [33].

The following instrumental investigations for localization use HRUS, [99mTc]MIBI scintigraphy and, in suspected ectopic localizations, 18F-Choline PET-CT. The planned parathyroidectomy is selective, limited to pathological parathyroids, with intraoperative ultrasound and rapid PTH measurement (rPTH-IO), avoiding total parathyroidectomy [128,129].

In the surgical timing for MEN 2, the association with PHEO must alert the surgeon and anesthesiologist to prepare the patient with alpha-blockers, even if normotensive, before proceeding to either synchronous treatment of MTC and PHEO at

once, in the same session, starting with adrenalectomy, especially if unilateral and completing with thyroidectomy or alternatively to postpone the MTC surgery, if metastatic or complex, to a subsequent session [130].

1.6. Pathology

Sporadic MTC typically presents as a circumscribed but not encapsulated nodule, it is single in 75–95% of cases; hereditary MTC is multifocal in 94% of cases [43,131,132].

Macroscopically, MTC is usually solid, yellowish or reddish in color; larger lesions may present hemorrhagic spot or necrosis. Foci with the largest diameter <1 cm are defined as micro-MTC.

The cells of MTC are polygonal with finely granular eosinophilic cytoplasm and central nucleus. The presence of amyloid is a distinctive feature of MTC and is composed of CT molecules. Histologically, numerous variants of MTC are known, the most common include the classic variant, which accounts for 48.9% and the amyloid-rich variant, which accounts for 38.3%. Other variants include the trabecular one, the amphicrine variant (containing mucin), angiosarcoma type, clear cell type, follicular type, capsular type, giant cell type, melanotic type (containing melanin), oncocyctic type (resembling a Hurthle cell adenoma), papillary type, pseudopapillary type, paraganglioma type, small cell type, squamous type, nest-like pattern with pigmented dendritic cells resembling sustentacular cells, and spindle cell type [133–148].

Immunohistochemical analysis of MTC involves positivity for CT, CEA, chromogranin A, cytokeratin (CK), particularly CK7,CK8 and NKX2-1/TTF-1 [50].

Several investigators have reported a considerable amount of CEA production by MTC, made evident by immunohistochemistry studies and by elevated CEA levels in plasma: just in 1987 Schroder and Klopper underlined CEA shares a number of epitopes with the non-specific cross reacting antigens (NCA) and the most polyclonal CEA antibodies cross react with NCA, this may explain the false positive results by using the polyclonal CEA instead of monoclonal for MTC immunohistochemistry. CEA immunoreactivity has been detected in MTC with an incidence ranging from 77% to 100%: this range is attributed to differences in specificity of the antibodies used. Subsequently, CEA has been recognized as an attractive target antigen for imaging and for the treatment of MTC using various radiolabeled anti-CEA monoclonal antibodies [149–151].

To detect neuro endocrine (NE) differentiation in thyroid tumors it is necessary to test at immunohistochemistry for NE markers, such as neuron-specific enolase (NSE), synaptophysin, CT and chromogranin: some carcinomas without the microscopic diagnosis of a NE tumor may show NE differentiation in immunohistochemistry, especially in non-NE organs with NE cells such as the lungs, digestive tract, prostate and thyroid [152]. In 1996 Kargi et al. analyzed histological samples of 40 thyroid carcinomas, consisting of 35 papillary, 2 follicular, 1 Hürthle-cell and 2 undifferentiated carcinomas and conducted immunohistochemical studies on the samples with NE markers: they reported positivity for three of the markers, namely,

NSE, CT, and synaptophysin, in six samples (five papillary and one Hürthle-cell carcinoma), but none demonstrated immunoreactivity for chromogranin [153]. Several investigators propose that some thyroid non NE tumors show positivity for thyroid NE tumor markers because they can present a follicular and C-cell differentiation with positive staining for both thyroglobulin and CT, and postulate that endodermally derived ultimobranchial stem cells may give rise to both C-cells and follicular cells [152,154]. In 2005 Munitz et al. presented the case of a Hürthle-cell carcinoma, an oxyphilic variant of follicular carcinoma, positive for NE markers such as CT and synaptophysin at immunohistochemistry and the authors underlined that, although a thyroid nodule and elevated CT levels usually indicate MTC, the possibility of other less common thyroid tumors such as Hürthle-cell carcinoma must be considered and other NE markers such as chromogranin must be evaluated [152].

The AJCC staging system has defined four stages of MTC, based on clinical and pathological features such as tumor size, presence/absence of extrathyroidal invasion, local and regional metastases and distant metastases (Tables 3, 4) [32].

In 2015, Lindsey et al. applied the concept of *dynamic restaging* of risk to predict disease recurrence in MTC. The authors highlighted that excellent response rates, with undetectable CT and CEA and negative imaging, are associated with a recurrence risk of 1–8% and mortality rates < 5%. As the TNM increases, there is a greater number of patients with incomplete biochemical response or structural disease which are correlated with higher recurrence and mortality rates [155].

In 2020, two research groups, one at the Memorial Sloan Kettering (New York) and one at the Sydney Royal North Shore Hospital (Sydney), introduced the concept of grading for MTC, based on the evaluation of the mitotic index, Ki-67 and the presence/absence of necrosis, similar to the grading system used for neuroendocrine tumors (NET). In 2021, starting from these study groups, an international consortium was created, which produced the International Medullary Thyroid Carcinoma Grading System (IMTCGS) that distinguishes two categories: low-grade MTC, with a mitotic index of < 5 mitoses/2

mm², Ki67 < 5%, no necrosis and high-grade MTC, with at least one of the characteristics among mitotic index of > 5 mitoses/2 mm², Ki67 > 5% or presence of necrosis [156–158].

1.7. Complementary therapies

External radiotherapy is no longer indicated, nowadays reserved for symptomatic bone or brain metastases, nor is classic cytotoxic chemotherapy, due to low response rates (15–20%) [33].

Starting from 2005, new targeted therapies with tyrosine kinase inhibitors (TKI) have emerged for MTC. Since the structure of RET kinase is similar to that one of type 2 vascular endothelial growth factor receptor (VEGFR2), it is susceptible to inhibition by anti-angiogenic drugs, such as anti-angiogenics multikinase, vandetanib and cabozantinib. Vandetanib inhibits VEGFR, RET, and epidermal growth factor receptor (EGFR) and cabozantinib inhibits VEGFR, RET, and c-MET [159,160].

Treatment with these drugs is indicated in patients with significant tumor burden and disease progression.

Other second-line multikinase inhibitors include sorafenib, sunitinib, pazopanib and lenvatinib [161].

Vandetanib and cabozantinib are Multitarget Kinase Inhibitors (MKIs) used as first line treatment for advanced MTC. These MKIs could also be used for RET-altered malignancies, but they have modest efficacy with weak anti-RET specific inhibition. Moreover, studies are ongoing on highly potent selective RET inhibitors such as selpercatinib (LOXO-282) and pralsetinib (BLU-667). Selpercatinib, a highly selective RET kinase inhibitor, has been approved on 8 May 2020 by the Food and Drug Administration (FDA). In a phase 1–2 trial the response rate for RET mutant MTC was 69% and 73% respectively in patients with and without previous MKI treatment [162,163]. In 2020 Jozaghi et al. reported the first case of neoadjuvant selpercatinib followed by surgery for a RET mutated MTC initially unresectable, metastatic with greater than 50% Response Evaluation Criteria in Solid Tumors (RECIST) response and a complete surgical resection followed by selpercatinib resumption. This approach of neoadjuvant RET-specific inhibitor followed by surgery for patients with locoregionally advanced MTC reduced the risk of locoregional complications, however clinical trials are required to establish safety, efficacy and long-term outcomes with this approach [164]. Various other investigational therapeutic modalities, including immunotherapy such as pembrolizumab, nivolumab and ipilimumab, which are gastrin analogues/cholecystokinin 2 agonists, tumor vaccines, radioimmunotherapy using radiolabeled anti-CEA monoclonal antibodies, and peptide receptor radionuclide therapy (PRRT) have been developed [159].

Peptide Receptor Radionuclide Therapy (PRRT) with radiolabeled somatostatin analogues (SSA) using 90 yttrium (90Y) and 177 lutetium (177Lu) is based on the rationale that MTC overexpresses type 2 somatostatin receptors (SSTR) [165].

PRRT shows efficacy in treating patients with MTC, with a favorable radiological response (stable disease, partial response or complete response) reported in 12.9% to 60% of cases, together with low toxicity [166–168]. Since MTC also specifically expresses cholecystokinin receptors (CCK2R), PRRT has been tested with this target and some randomized trials

Table 3. American Joint Committee on cancer staging [32].

Tumor (T)	Lymph node (N)	Methastasis (M)	Stage
T1	N0	M0	I
T2-T3	N0	M0	II
T1-T3	N1a	M0	III
T1-T3	N1b	M0	IVA
T4a	Any N	M0	IVA
T4b	Any N	M0	IVB
Any T	Any N	M1	IVC

Table 4. American Joint Committee on cancer staging [32].

Tumor (T)	Lymph node (N)	Methastasis (M)	Stage
T1	N0	M0	I
T2-T3	N0	M0	II
T1-T3	N1a	M0	III
T1-T3	N1b	M0	IVA
T4a	Any N	M0	IVA
T4b	Any N	M0	IVB
Any T	Any N	M1	IVC

are ongoing. PRRT could therefore represent an option in the treatment of advanced/progressive/metastatic disease [169].

Adoptive T cell immunotherapy using chimeric antigen receptor (CAR)-modified T cells (CAR Ts) is proposed as a new approach in the treatment of cancer: the glial-derived neurotrophic factor (GDNF) family receptor alpha 4 (GFR α 4) has been proposed as a putative antigen target for CAR-based therapy of MTC. Bhoj et al. in 2021 demonstrated the feasibility of targeting GFR α 4 by CAR T eliminating tumors derived from the MTC TT cell line in an immunodeficient mouse xenograft model of MTC: their data supported this antigen as a promising target for adoptive T cell immunotherapy and other antibody-based therapies for MTC [170].

In future perspectives, the recent advent of genetic editing and gene modulation plays an important role. The clustered regularly interspaced short palindromic repeats associated (CRISPR)-CRISPR associated (Cas) method has modified the way of manipulating the genome and facilitated the study of tumor cell biology both in vitro and in vivo. The CRISPR-Cas method has favored a rapid expansion in the understanding of molecular mechanisms of cell signaling, also in thyroid carcinoma [171].

2. Conclusions

MTC is a rare tumor with a variable and unpredictable evolution. Alongside a minority of cases of MTC, even voluminous but always intrathyroidal, without metastases and with a favorable course that can benefit from conservative treatments, there are others with progressive aggressiveness, often with stable disease and others with rapid progression, out of surgical control, requiring multiple operations. The stage remains the discriminating prognostic factor and, therefore, the timing of diagnosis, to which two allies have contributed to an earlier diagnosis: a serum marker, CT, which is associated less constantly with CEA and a molecular marker, RET, which can identify asymptomatic carriers of the genetic mutation in the patient's family and, based on the mutation risk level, define the timing of surgery, initiating prophylactic or early surgery.

It is imperative and relatively simple to diagnose MTC. This is followed by molecular genetic analysis and the possible correlation with MEN, while in parallel, total-body instrumental staging is performed.

The primary preoperative objective is to exclude distant metastases and localize cervical lymph node metastases by levels, which is entrusted to a dedicated and competent team of radiologists and nuclear medicine physicians, enabling increasingly personalized and safe surgery.

3. Expert opinion

This review has examined the history of CMT, which runs parallels to that of calcitonin. The molecular profile of MTC is analyzed, distinguishing the sporadic and hereditary form. In the hereditary type, the surgical timing is defined based on the risk category linked to the present mutation.

This review has explored the history of CMT, which runs parallel to that of CT. The molecular study was analyzed,

fundamental in framing the CMT by distinguishing the sporadic from the hereditary and in the latter defining the surgical timing, based on the risk category of the mutation present.

MTC (medullary thyroid carcinoma) is a rare tumor with variable and unpredictable evolution, often already metastatic at the time of diagnosis. Early diagnosis, thanks to serum markers (CT, CEA) and molecular markers (RET), allows to anticipate the stage of the disease and to offer a stable cure.

Considering surgical treatment guidelines, based solely on preoperative CT values, the contributions on preoperative staging procedures are modest and the relative evaluations are sporadic.

Clear and shared guidelines are essential in guiding the diagnostic and therapeutic pathway, but they must always be subjected to the critical and expert judgment of a multidisciplinary team that evaluates the patient in his individuality and constructs a personalized pathway that takes into consideration the quality of life.

Shared and reliable CT cutoffs for demonstrating the presence of MTC are still lacking in literature and each center, in clinical practice, should define its own *threshold* levels of calcitonin after stimulation test.

This work aims to emphasize the need for accurate staging, aimed at avoiding iterative, complex and sometimes less radical interventions, as well as unnecessary prophylactic compartmental interventions, not free from complications.

However, there is no indicator capable of distinguishing voluminous but benign MTC, always intrathyroidal and without metastasis, which could benefit from conservative surgery, from indolent MTC, even if metastasized, sometimes with stable residual biochemical disease after surgery and from an aggressive one.

Future research should focus on achieving this objective through serum, genetic, and immuno-histochemical studies.

Efforts should be focused on targeted therapies, including in neoadjuvant setting in advanced or unresectable disease and on genetic engineering to restore the wild-type gene structure, preventing tumor development in asymptomatic RET mutation carriers.

Based on literature and our experience, it is concluded that, still today, surgery remains the only therapeutic weapon for MTC and its effectiveness is related to the stage of the disease. However, data are variable and often contradictory, based on modest and difficult to compare case studies, due to the rarity of MTC.

The rarity of MTC is reflected in the lack of randomized studies that provide shared indications, based on a significant number of enrolled patients, for the surgical treatment of the primary and local or distant persistence/recurrence of the disease.

It is important to emphasize the importance of not proceeding with surgical intervention before studying the patient from a genetic perspective and before completing the entire diagnostic workup.

The fundamental objective is to diagnose MTC in the intrathyroidal phase, before lymph node metastasis and for hereditary forms to act in a phase that is not only early but even preclinical, when C cell hyperplasia has not yet turned into a tumor.

In the near future, we expect to see a development of more and more personalized treatments, from surgery to new

targeted pharmacological therapies, in support of a tailored multidisciplinary therapy, guided by an increasingly specific molecular and immunohistochemical profile of MTC.

Funding

This paper received no funding.

Declaration of interest

The authors have no relevant affiliations or financial involvement with any organization or entity with a financial interest in or financial conflict with the subject matter or materials discussed in the manuscript. This includes employment, consultancies, honoraria, stock ownership or options, expert testimony, grants or patents received or pending, or royalties.

Reviewer disclosures

Peer reviewers on this manuscript have no relevant financial or other relationships to disclose.

References

Papers of special note have been highlighted as either of interest (•) or of considerable interest (••) to readers.

- Long KL, Grubbs EG. Carcinoma of the thyroid gland and neoplasms of the parathyroid glands. In: editors, Barry M, and Feig W. The MD Anderson surgical oncology handbook. Sixth ed. Philadelphia (PA): Lippincott Williams and Wilkins; 2018. p. 463–491.
- Thomas RM, Hebra MA, Perrier ND. Well differentiated carcinoma of the thyroid and neoplasms of the parathyroid glands. In: Barry M, Feig W, editors. The MD Anderson surgical oncology handbook. 5th ed. Philadelphia (PA): Lippincott Williams and Wilkins; 2012. p. 550–574.
- Pacini F, Castagna MG, Brillì L, et al. Thyroid cancer: ESMO clinical practice guidelines for diagnosis, treatment and follow-up. *Ann Oncol.* 2012;23:110–119. doi: 10.1093/annonc/mds230
- Hazard J, Hawk W, Crile G. Medullary (solid) carcinoma of the thyroid—a clinicopathologic entity. *J Clin Endocrinol Metab.* 1959;19(1):152–161. doi: 10.1210/jcem-19-1-152
- of considerable interest
- Jaquet J. Ein Fall von metastasierenden Amyloid-tumoren (Lymphosarkom). *Virchows Arch Path Anat.* 1906;185(2):251–268. doi: 10.1007/BF01948712
- Stoffel E. Lokales Amyloid der Schilddrüse. *Virchows Arch Path Anat.* 1910;201(2):245–252. doi: 10.1007/BF01995500
- Brandenburg W. [Metastasizing amyloid goiter]. *Zentralbl Allg Pathol.* 1954;91(9–11):422–428.
- Laskowski J. Carcinoma hyalinicum thyroideae. *Nowotwory.* 1957;7:23–28.
- Horn R. Carcinoma of the thyroid: description of a distinctive morphological variant and report of seven cases. *Cancer.* 1951;4(4):697–707. doi: 10.1002/1097-0142(195107)4:4<697:AIID-CNCR2820040407>3.0.CO;2-8
- Williams E, Brown C, Doniach I. Pathological and clinical findings in a series of 67 cases of medullary carcinoma of the thyroid. *J Clin Pathol.* 1966;19(2):103–113. doi: 10.1136/jcp.19.2.103
- Williams E. Histogenesis of medullary carcinoma of the thyroid. *J Clin Pathol.* 1966;19(2):114–118. doi: 10.1136/jcp.19.2.114
- Cresswell Baber E. Contributions to the minute anatomy of the thyroid gland of the dog. London: Philos Trans R Soc Lond; 1876.
- Pearse A. The cytochemistry of the thyroid C cells and their relationship to calcitonin. *Proc R Soc Lond B Biol Sci.* 1966;164:557–569.

- Copp D, Cameron E, Cheney B. Evidence for calcitonin—A New hormone from the parathyroid that lowers blood calcium. *Endocrinology.* 1962;70(5):638–649. doi: 10.1210/endo-70-5-638.
- of interest
- Hirsch P, Voelkel E, Munson P. Thyrocalcitonin: Hypocalcemic hypophosphatemic principle of the thyroid gland. *Science.* 1979;146(1964):412–413. doi: 10.1126/science.146.3642.412
- Tashjian AJ, Melvin E. Medullary carcinoma of the thyroid gland. Studies of thyrocalcitonin in plasma and tumor extracts. *N Engl J Med.* 1968;279(6):279–283. doi: 10.1056/NEJM196808082790602
- Melvin K, Tashjian A. The syndrome of excessive thyrocalcitonin produced by medullary carcinoma of the thyroid. *Proc Natl Acad Sci, USA.* 1968;59(4):1216–1222. doi: 10.1073/pnas.59.4.1216
- Tubiana M, Milhaud G, Coutris G. Medullary carcinoma and thyrocalcitonin. *Br Med J.* 1968;4(5623):87–89. doi: 10.1136/bmj.4.5623.87
- Cunliffe WJ, Black MM, Hall R. A calcitonin-secreting thyroid carcinoma. *Lancet.* 1968;292(7559):63–66. doi: 10.1016/S0140-6736(68)90352-8
- Meyer JS, Abdel-Bari W. Granules and thyrocalcitonin-like activity in medullary carcinoma of the thyroid gland. *N Engl J Med.* 1968;278(10):523–529. doi: 10.1056/NEJM196803072781002
- Bussolati G, Pearse AG. Immunofluorescent localization of calcitonin in the “C” cells of pig and dog thyroid. *J Endocrinol.* 1967;37(2):205–209. doi: 10.1677/joe.0.0370205
- Ziegler R. Sporadic medullary thyroid carcinoma: clinical features and diagnosis. *Recent Results Cancer Res.* 1992;125:91–104.
- Wells SA, Haagensen DE, Linehan WM, et al. The detection of elevated plasma levels of carcinoembryonic antigen in patients with suspected or established medullary thyroid carcinoma. *Cancer.* 1978;42:1498–1503.
- Leboulleux S, Baudin E, Travagli JP, et al. Medullary thyroid carcinoma. *Clin Endocrinol (Oxf).* 2004;61(3):299–310. doi: 10.1111/j.1365-2265.2004.02037.x
- Viola D, Elisei R. Management of medullary thyroid cancer. *Endocrinol Metab Clin North Am.* 2019; 48:285–301.
- of considerable interest
- Machens A, Dralle H. Biomarker-based risk stratification for previously untreated medullary thyroid cancer. *J Clin Endocrinol Metab.* 2010;95(6):2655–2663. doi: 10.1210/jc.2009-2368.
- of interest
- Moley JF. Medullary thyroid carcinoma: management of lymph node metastases. *J National Compr Cancer Network.* 2010;8(5):549–556. doi: 10.6004/jnccn.2010.0042
- Kloos RT, Eng C, Evans DB, et al. Medullary thyroid cancer: management guidelines of the American thyroid Association. *Thyroid: Offic J Am Thyroid Association.* 2009;19:565–612. doi: 10.1089/thy.2008.0403
- Roman S, Lin R, Sosa JA. Prognosis of medullary thyroid carcinoma. *Cancer.* 2006;107(9):2134–2142. doi: 10.1002/cncr.22244
- Raue F, Frank-Raue K. Epidemiology and clinical presentation of medullary thyroid carcinoma. *Recent Results Cancer Res.* 2015;204:61–90.
- Machens A, Hinze R, Thomusch O, et al. Pattern of nodal metastasis for primary and reoperative thyroid cancer. *World J Surg.* 2002;26(1):22–28. doi: 10.1007/s00268-001-0176-3
- American Joint Committee on Cancer. *Thyroid – medullary.* In: B Mahul, BE Stephen, LG Frederick, editors. *AJCC cancer staging manual.* 8th ed. (NY): Springer; 2017. p. 899–910.
- Wells SA, Asa SL, Dralle H, et al. Revised American thyroid association guidelines for the management of medullary thyroid carcinoma. *Thyroid: Offic J Am Thyroid Association.* 2015;25:567–610.
- of considerable interest
- Girelli M, Nacamulli D, Pelizzo M, et al. Medullary thyroid carcinoma: clinical features and long-term follow-up of seventy-eight patients treated between 1969 and 1986. *Thyroid: Offic J Am Thyroid Association.* 1998;8(6):517–523. doi: 10.1089/thy.1998.8.517

35. Kebebew E, Greenspan FS, Clark OH, et al. Extent of disease and practice patterns for medullary thyroid cancer. *J Am Coll Surg.* 2005;200(6):890–896. doi: 10.1016/j.jamcollsurg.2004.12.011
36. Tisell LE, Jansson S. Recent results of reoperative surgery in medullary carcinoma of the thyroid. *Wien Klin Wochenschr.* 1988;100(11):347–348.
37. Duh Q-Y, Sancho JJ, Greenspan FS. Medullary thyroid carcinoma the need for early diagnosis and total thyroidectomy. *Archives of Surgery.* 1989;124(10).
38. Tamagnini P, Bernante P, Piotta A, et al. Article original Réintervention pour carcinome médullaire de la thyroïde : résultats à long terme. *Ann Chir.* 2001;126(8):762–767. doi: 10.1016/S0003-3944(01)00609-5
39. Machens A, Dralle H. Benefit-risk balance of reoperation for persistent medullary thyroid cancer. *Ann Surg.* 2013;257(4):751–757. doi: 10.1097/SLA.0b013e31826bc239
40. Machens A, Dralle H. Surgical treatment of medullary thyroid cancer. Recent results in cancer research. Springer: (NY) LLC; 2015. p. 187–205. 2015 10.1007/978-3-319-22542-5_9
- of considerable interest
41. Pelizzo MR, Busnardo B, Bernante P, et al. Medullary thyroid carcinoma: prognostic factors. *Minerva Chir.* 1993;48(21–22):1289–1291.
42. Girelli ME, Dotto S, Nacamulli D, et al. Prognostic value of early postoperative calcitonin level in medullary thyroid carcinoma. *Tumori.* 1994;80(2):113–117. doi: 10.1177/030089169408000205
- of considerable interest
43. Kebebew E, Ituarte PHG, Siperstein AE, et al. Medullary thyroid carcinoma. *Cancer.* 2000;88(5):1139–1148. doi: 10.1002/(SICI)1097-0142(20000301)88:5<1139:AID-CNCR26>3.0.CO;2-Z
44. Modigliani E, Cohen R, Campos J-M, et al. Prognostic factors for survival and for biochemical cure in medullary thyroid carcinoma: results in 899 patients. *Clin Endocrinol.* 1998;48(3):265–273. doi: 10.1046/j.1365-2265.1998.00392.x
45. Pelizzo MR, Boschin IM, Bernante P, et al. Natural history, diagnosis, treatment and outcome of medullary thyroid cancer: 37 years experience on 157 patients. *Eur J Surg Oncol.* 2007;33(4):493–497. doi: 10.1016/j.ejso.2006.10.021
- of interest
46. Chen H, Sippel RS, O'Dorisio MS, et al. The north American neuroendocrine tumor society consensus guideline for the diagnosis and management of neuroendocrine tumors: pheochromocytoma, paraganglioma, and medullary thyroid cancer. *Pancreas.* 2010;39(6):775–783. doi: 10.1097/MPA.0b013e3181ebb4f0
- of interest
47. Moley JF, Lairmore TC, Phay JE. Hereditary endocrinopathies. *Curr Probl Surg.* 1999;36(9):653–762. doi: 10.1016/S0011-3840(99)80001-X
48. Mathiesen JS, Effraimidis G, Rossing M, et al. Multiple endocrine neoplasia type 2: a review. *Semin Cancer Biol.* 2022;79:163–179. doi: 10.1016/j.semcancer.2021.03.035
49. •Pelizzo MR, Torresan F, Boschin IM, et al. Early, prophylactic thyroidectomy in hereditary medullary thyroid carcinoma. *Am J Clin Oncol.* 2015;38(5):508–513. doi: 10.1097/COC.0b013e3182a78fec
- of considerable interest
50. Arrangoiz R, Cordera F, Caba D. Medullary thyroid carcinoma literature review and Current management. *J Clin Endocrinol Metab.* 2018;2.
- of considerable interest
51. Zordan P, Tavella S, Brizzolara A, et al. The immediate upstream sequence of the mouse ret gene controls tissue-specific expression in transgenic mice. *Int J Mol Med.* 2006. doi:10.3892/ijmm.18.4.601.
52. Pachnis V, Mankoo B, Costantini F. Expression of the c-ret proto-oncogene during mouse embryogenesis. *Development.* 1993;119(4):1005–1017. doi: 10.1242/dev.119.4.1005
53. Takahashi M, Ritz J, Cooper GM. Activation of a novel human transforming gene, ret, by DNA rearrangement. *Cell.* 1985;42(2):581–588. doi: 10.1016/0092-8674(85)90115-1
54. Mulligan LM, Kwok JBJ, Healey CS, et al. Germ-line mutations of the RET proto-oncogene in multiple endocrine neoplasia type 2A. *Nature.* 1993;363(6428):458–460. doi: 10.1038/363458a0
55. Carlson KM, Dou S, Chi D, et al. Single missense mutation in the tyrosine kinase catalytic domain of the RET protooncogene is associated with multiple endocrine neoplasia type 2B. *Proc Natl Acad Sci.* 1994;91:1579–1583.
56. Hofstra RMW, Landsvater RM, Ceccherini I, et al. A mutation in the RET proto-oncogene associated with multiple endocrine neoplasia type 2B and sporadic medullary thyroid carcinoma. *Nature.* 1994;367(6461):375–376. doi: 10.1038/367375a0
57. Eng C, Smlth DP, Mulligan LM, et al. Point mutation within the tyrosine kinase domain of the RET proto-oncogene in multiple endocrine neoplasia type 2B and related sporadic tumours. *Hum Mol Genet.* 1994;3(2):237–241. doi: 10.1093/hmg/3.2.237
58. Marsh DJ, Learoyd DL, Andrew SD, et al. Somatic mutations in the RET proto-oncogene in sporadic medullary thyroid carcinoma. *Clin Endocrinol (Oxf).* 1996;44(3):249–257. doi: 10.1046/j.1365-2265.1996.681503.x
59. Donis-Keller H, Dou S, Chi D, et al. Mutations in the RET proto-oncogene are associated with MEN 2A and FMTC. *Hum Mol Genet.* 1993;2(7):851–856. doi: 10.1093/hmg/2.7.851
60. Romei C, Ciampi R, Elisei R. A comprehensive overview of the role of the RET proto-oncogene in thyroid carcinoma. *Nat Rev Endocrinol Nature Publishing Group.* 2016;12:192–202.
- of interest
61. Ciampi R, Mian C, Fugazzola L, et al. Evidence of a low prevalence of RAS mutations in a large medullary thyroid cancer series. *Thyroid: Offic J Am Thyroid Association.* 2013;23(1):50–57. doi: 10.1089/thy.2012.0207
62. Boichard A, Croux L, Al Ghuzlan A, et al. Somatic RAS mutations occur in a large proportion of sporadic RET-negative medullary thyroid carcinomas and extend to a previously unidentified Exon. *J Clin Endocrinol Metab.* 2012;97(10):E2031–E2035. doi: 10.1210/jc.2012-2092
63. Moura MM, Cavaco BM, Pinto AE, et al. High Prevalence of RAS mutations in RET-negative sporadic medullary thyroid carcinomas. *J Clin Endocrinol Metab.* 2011;96(5):E863–E868. doi: 10.1210/jc.2010-1921
64. Santoro M, Melillo RM, Fusco A. RET/PTC activation in papillary thyroid carcinoma. *European Journal Of Endocrinology Prize Lecture Eur J Endocrinol.* 2006;155(5):645–653. doi: 10.1530/eje.1.02289
65. Ballerini P, Struski S, Cresson C, et al. RET fusion genes are associated with chronic myelomonocytic leukemia and enhance monocytic differentiation. *Leukemia.* 2012;26(11):2384–2389. doi: 10.1038/leu.2012.109
66. Kohno T, Ichikawa H, Totoki Y, et al. KIF5B-RET fusions in lung adenocarcinoma. *Nat Med.* 2012;18(3):375–377. doi: 10.1038/nm.2644
67. Amiel J, Sproat-Emison E, Garcia-Barcelo M, et al. Hirschsprung disease, associated syndromes and genetics: a review. *J Med Genet.* 2007;45(1):1–14. doi: 10.1136/jmg.2007.053959
68. Attié T, Pelet A, Ederly P, et al. Diversity of RET proto-oncogene mutations in familial and sporadic Hirschsprung disease. *Hum Mol Genet.* 1995;4(8):1381–1386. doi: 10.1093/hmg/4.8.1381
69. Elisei R, Romei C, Renzini G, et al. The timing of total thyroidectomy in RET gene mutation carriers could be personalized and safely planned on the basis of serum calcitonin: 18 years experience at one single center. *J Clin Endocrinol Metab.* 2012;97:426–435.
- of considerable interest
70. Elisei R, Bottici V, Luchetti F, et al. Impact of routine measurement of serum calcitonin on the diagnosis and outcome of medullary thyroid cancer: experience in 10,864 patients with nodular thyroid disorders. *J Clin Endocrinol Metab.* 2004;89(1):163–168. doi: 10.1210/jc.2003-030550
71. Pacini F, Fontanelli M, Fugazzola L, et al. Routine measurement of serum calcitonin in nodular thyroid diseases allows the preoperative diagnosis of unsuspected sporadic medullary thyroid carcinoma. *J Clin Endocrinol Metab.* 1994;78(4):826–829. doi: 10.1210/jc.78.4.826
72. Costante G, Filetti S. Early diagnosis of medullary thyroid carcinoma: Is systematic calcitonin screening appropriate in patients with nodular thyroid disease? *Oncology.* 2011;16(1):49–52. doi: 10.1634/theoncologist.2010-0344

73. Frank-Raue K, Machens A, Leidig-Bruckner G, et al. Prevalence and clinical spectrum of nonsecretory medullary thyroid carcinoma in a series of 839 patients with sporadic medullary thyroid carcinoma. *Thyroid: Offic J Am Thyroid Association*. 2013;23(3):294–300. doi: [10.1089/thy.2012.0236](https://doi.org/10.1089/thy.2012.0236)
74. Trimboli P, Giovanella L. Serum calcitonin negative medullary thyroid carcinoma: a systematic review of the literature. *Clin Chem Lab Med Walter de Gruyter GmbH*. 2015;53(2015):1507–1514.
75. Boschin IM, Torresan F, Toniato A, et al. Incidental medullary thyroid microcarcinoma revealed by mild increase of preoperative serum calcitonin levels: therapeutic implications. *Endocrine*. 2014;45(3):448–453. doi: [10.1007/s12020-013-0019-7](https://doi.org/10.1007/s12020-013-0019-7)
76. Gambardella C, Offi C, Clarizia G, et al. Medullary thyroid carcinoma with double negative calcitonin and CEA: a case report and update of literature review. *BMC Endocr Disord*. 2019;19(1):103. doi: [10.1186/s12902-019-0435-7](https://doi.org/10.1186/s12902-019-0435-7)
77. Yue W, Zhang Y. Oncologic outcomes of calcitonin-negative medullary thyroid carcinoma. *Front Endocrinol*. 2022;13: doi: [10.3389/fendo.2022.1025629](https://doi.org/10.3389/fendo.2022.1025629)
78. Jingzhu Z, Xiangqian Z, Ming G, et al. Clinical challenges with calcitonin-negative medullary thyroid carcinoma: three case reports and a review of the literature. *Ann R Coll Surg Engl*. 2022;104(3):221–230. doi: [10.1308/rcsann.2020.7118](https://doi.org/10.1308/rcsann.2020.7118)
79. Livolsi VA. Neuroendocrine tumors of the thyroid and their mimics. *Endocr Pathol*. 2021;32:211–221.
80. Verbeek HHG, de Groot JWB, Sluiter WJ. Calcitonin testing for detection of medullary thyroid cancer in people with thyroid nodules. *Cochrane database of systematic reviews*. 2020;2020(3).
81. Censi S, Cavedon E, Fernando SW, et al. Calcitonin measurement and immunoassay interference: A case report and literature review. *Clin Chem Lab Med Walter de Gruyter GmbH*. 2016;54(12):1861–1870. doi: [10.1515/cclm-2015-1161](https://doi.org/10.1515/cclm-2015-1161)
82. Alves TG, Kasamatsu TS, Yang JH, et al. Macrocalcitonin is a novel pitfall in the routine of serum calcitonin immunoassay. *J Clin Endocrinol Metab*. 2016;101(2):653–658. doi: [10.1210/jc.2015-3137](https://doi.org/10.1210/jc.2015-3137)
83. Goltzman D, Tischler AS. Characterization of the immunochemical forms of calcitonin Released by a medullary thyroid carcinoma in tissue culture. *J Clin Investig*. 1978;61(2):449–458. doi: [10.1172/JCI108956](https://doi.org/10.1172/JCI108956)
84. Austin LA, Heath H. Calcitonin. *N Engl J Med*. 1981;304(5):269–278. doi: [10.1056/NEJM198101293040505](https://doi.org/10.1056/NEJM198101293040505)
85. Milone F, Ramundo V, Chiofalo MG, et al. Predictive value of pentagastrin test for preoperative differential diagnosis between C-Cell hyperplasia and medullary thyroid carcinoma in patients with moderately elevated basal calcitonin levels. *Clin Endocrinol*. 2009. doi: [10.1111/j.1365-2265.2009.03759.x](https://doi.org/10.1111/j.1365-2265.2009.03759.x)
86. Baykan EK, Erdoğan M. Basal and pentagastrin-stimulated calcitonin cut-off values in diagnosis of preoperative medullary thyroid cancer. *Turk J Med Sci*. 2021;51(2):650–656.
87. Verdy M, Cholette JP, Cantin J, et al. Calcium infusion and pentagastrin injection in diagnosis of medullary thyroid carcinoma. *Can Med Assoc J*. 1978;119(1):29–35.
88. Colombo C, Verga U, Mian C, et al. Comparison of calcium and pentagastrin tests for the diagnosis and follow-up of medullary thyroid cancer. *J Clin Endocrinol Metab*. 2012;97(3):905–913. doi: [10.1210/jc.2011-2033](https://doi.org/10.1210/jc.2011-2033)
89. Mian C, Perrino M, Colombo C, et al. Refining calcium test for the diagnosis of medullary thyroid cancer: cutoffs, procedures, and safety. *J Clin Endocrinol Metab*. 2014;99(5):1656–1664. doi: [10.1210/jc.2013-4088](https://doi.org/10.1210/jc.2013-4088)
90. Russo M, Scollo C, Padova G, et al. Cardiac arrest after intravenous calcium administration for calcitonin stimulation test. *Thyroid Mary Ann Liebert Inc*. 2014;24(3):606–607. doi: [10.1089/thy.2013.0394](https://doi.org/10.1089/thy.2013.0394)
91. Boi F, Maurelli I, Pinna G, et al. Calcitonin measurement in wash-out fluid from fine needle aspiration of neck masses in patients with primary and metastatic medullary thyroid carcinoma. *J Clin Endocrinol Metab*. 2007;92(6):2115–2118. doi: [10.1210/jc.2007-0326](https://doi.org/10.1210/jc.2007-0326)
92. Ibrahim EY, Correa R. Diagnostic value of preoperative serum calcitonin levels in medullary thyroid carcinoma. *Clin Thyroidol*. 2022;34(2):85–88. doi: [10.1089/ct.2022;34.85-88](https://doi.org/10.1089/ct.2022;34.85-88)
93. Trimboli P, Treglia G, Guidobaldi L, et al. Detection rate of FNA cytology in medullary thyroid carcinoma: a meta-analysis. *Clin Endocrinol (Oxf)*. 2015;82(2):280–285. doi: [10.1111/cen.12563](https://doi.org/10.1111/cen.12563)
94. Cibas ES, Ali SZ. The 2017 Bethesda system for reporting thyroid cytopathology. *Thyroid: Offic J Am Thyroid Association*. 2017;27(11):1341–1346. doi: [10.1089/thy.2017.0500](https://doi.org/10.1089/thy.2017.0500)
95. Andrade F, Rondeau G, Boucai L, et al. Serum calcitonin nadirs to undetectable levels within 1 month of curative surgery in medullary thyroid cancer. *Arch Endocrinol Metab*. 2019. doi: [10.20945/2359-3997000000112](https://doi.org/10.20945/2359-3997000000112)
96. Laboureau-Soares Barbosa S, Rodien P, Leboulleux S, et al. Case history ectopic adrenocorticotrophic hormone-syndrome in medullary carcinoma of the thyroid: a retrospective analysis and review of the literature. *Thyroid: Offic J Am Thyroid Association*. 2005;15(6):618–623.
97. Corsello A, Ramunno V, Locantore P, et al. Medullary thyroid cancer with ectopic cushing's syndrome: a case report and systematic review of detailed cases from the literature. *Thyroid: Offic J Am Thyroid Association*. 2022;32(11):1281–1298. doi: [10.1089/thy.2021.0696](https://doi.org/10.1089/thy.2021.0696)
98. Kudo T, Miyauchi A, Ito Y, et al. Diagnosis of medullary thyroid carcinoma by calcitonin measurement in fine-needle aspiration biopsy specimens. *Thyroid: Offic J Am Thyroid Association*. 2007;17(7):635–638. doi: [10.1089/thy.2006.0338](https://doi.org/10.1089/thy.2006.0338)
99. Robbins KT, Medina JE, Wolfe GT, et al. Standardizing neck dissection terminology: official report of the academy's committee for head and neck surgery and oncology. *Arch Otolaryngol Head Neck Surg*. 1991;117(6):601–605. doi: [10.1001/archotol.1991.01870180037007](https://doi.org/10.1001/archotol.1991.01870180037007)
100. Russ G, Bonnema SJ, Erdogan MF, et al. European thyroid Association guidelines for ultrasound malignancy risk stratification of thyroid nodules in adults: the EU-TIRADS. *Eur Thyroid J S Karger AG*. 2017;6(5):225–237. doi: [10.1159/000478927](https://doi.org/10.1159/000478927)
101. Pellizzo' MR, Bernante P, Piotta' A, et al. The extent of surgery for thyroid medullary cancer. *Tumori*. 1994;80(6):427–432. doi: [10.1177/030089169408000604](https://doi.org/10.1177/030089169408000604)
102. Frank-Raue K, Raue F, Buhr HJ, et al. Localization of occult persisting medullary thyroid carcinoma before microsurgical reoperation: high sensitivity of selective venous catheterization. *Thyroid: Offic J Am Thyroid Association*. 1992;2(2):113–117. doi: [10.1089/thy.1992.2.113](https://doi.org/10.1089/thy.1992.2.113)
103. Ben Mrad MD, Gardet P, Roche A, et al. Value of venous catheterization and calcitonin studies in the treatment and management of clinically inapparent medullary thyroid carcinoma. *Cancer*. 1989;63(1):133–138. doi: [10.1002/1097-0142\(19890101\)63:1<133: Aid-Cncr2820630121>3.0.Co;2-3](https://doi.org/10.1002/1097-0142(19890101)63:1<133: Aid-Cncr2820630121>3.0.Co;2-3)
104. National Comprehensive Cancer Network [internet]. Thyroid carcinoma version 2.2023 — may 18, 2023. Plymouth Meeting, (PA). Cited May 20, 2023. Available from: https://www.nccn.org/professionals/physician_gls/pdf/thyroid.pdf
105. Bozkurt MF, Virgolini I, Balogova S, et al. Guideline for PET/CT imaging of neuroendocrine neoplasms with 68Ga-DOTA-conjugated somatostatin receptor targeting peptides and 18F-DOPA. *Eur J Nucl Med Mol Imaging*. 2017;44(9):1588–1601. doi: [10.1007/s00259-017-3728-y](https://doi.org/10.1007/s00259-017-3728-y)
106. Roseland ME, Dewaraja YK, Wong KK. Advanced imaging and theranostics in thyroid cancer. *Curr Opin Endocrinol Diabetes Obes*. 2022;29(5):456–465. doi: [10.1097/MED.0000000000000740](https://doi.org/10.1097/MED.0000000000000740)
107. Asa S, Sonmezoglu K, Uslu-Besli L, et al. Evaluation of F-18 DOPA PET/CT in the detection of recurrent or metastatic medullary thyroid carcinoma: comparison with GA-68 DOTA-TATE PET/CT. *Ann Nucl Med*. 2021;35(8):900–905. doi: [10.1007/s12149-021-01627-2](https://doi.org/10.1007/s12149-021-01627-2)
108. Kushchayev SV, Kushchayeva YS, Tella SH, et al. Medullary thyroid carcinoma: an update on imaging. *J Thyroid Res*. 2019;2019(2019):1–17. doi: [10.1155/2019/1893047](https://doi.org/10.1155/2019/1893047)
109. Wong KK, Laird AM, Moubayed A, et al. How has the management of medullary thyroid carcinoma changed with the advent of 18F-FDG and non- 18F-FDG PET radiopharmaceuticals. *Nucl Med Commun*. 2012;33(7):679–688. doi: [10.1097/MNM.0b013e3283529bf7](https://doi.org/10.1097/MNM.0b013e3283529bf7)

110. Delorme S, Raue F. Imaging. In: Raue F, editor. Vol. 204, Medullary thyroid carcinoma. Cham: Springer; 2015. p. 91–116.
111. Zhang D, Colombo C, Sun H, et al. Unilateral surgery for medullary thyroid carcinoma: seeking for clinical practice guidelines. *Front Endocrinol.* 2022;13. doi: 10.3389/fendo.2022.875875
112. Cho SW. A high frequency of lobectomy instead of total thyroidectomy to treat medullary thyroid cancer in Korea: data from the Korean national health insurance service. *Endocrinol Metab (EnM).* 2020;35(4):784–785. doi: 10.3803/EnM.2020.408
113. Singer S, Husson O, Tomaszewska IM, et al. Quality-of-life priorities in patients with thyroid cancer: a multinational European organisation for research and treatment of cancer phase I study. *Thyroid: Offic J Am Thyroid Association.* 2016;26(11):1605–1613. doi: 10.1089/thy.2015.0640
114. Rosato L, Avenia N, Bernante P, et al. Complications of thyroid surgery: analysis of a multicentric study on 14,934 patients operated on in Italy over 5 years. *World J Surg.* 2004;28(3):271–276. doi: 10.1007/s00268-003-6903-1
115. Gršić K, Bumber B, Curčić Radivojević R, et al. Prophylactic central neck dissection in well-differentiated thyroid cancer. *Acta Clin Croat.* 2020;59:87–95. doi:10.20471/acc.2020.59.s1.11
116. Sippel RS, Chen H. Controversies in the surgical management of newly diagnosed and recurrent/residual thyroid cancer. *Thyroid: Offic J Am Thyroid Association.* 2009;19(12):1373–1380. doi: 10.1089/thy.2009.1606
117. Contrera KJ, Gule-Monroe MK, Hu MI, et al. Neoadjuvant selective RET inhibitor for medullary thyroid cancer: a case series. *Thyroid: Offic J Am Thyroid Association.* 2023;33(1):129–132. doi: 10.1089/thy.2022.0506
118. Tsang V. The role of a neoadjuvant RET inhibitor in medullary thyroid cancer. *Clin Thyroidol.* 2023;35(2):71–74. doi: 10.1089/ct.2023;35.71-74
119. Roh JL, Kim DH, Park CIL. Prospective identification of chyle leakage in patients undergoing lateral neck dissection for metastatic thyroid cancer. *Ann Surg Oncol.* 2008;15(2):424–429. doi: 10.1245/s10434-007-9692-1
120. Lorenz K, Abuazab M, Sekulla C, et al. Management of lymph fistulas in thyroid surgery. *Langenbecks Arch Surg.* 2010;395(7):911–917. doi: 10.1007/s00423-010-0686-2
121. Steven. Objective Comparison of physical dysfunction after neck dissection.
122. Merante Boschini I, Meduri F, Toniato A, et al. Cervical lymphorrhea after nodal dissection: role of fasting based on clinical evidence. *Minerva Chir.* 2006;61(1):57–62.
123. Tisell LE, Hansson G, Jansson S, et al. Reoperation in the treatment of asymptomatic metastasizing medullary thyroid carcinoma. *Surgery.* 1986;99(1):60–66.
124. Torresan F, Censi S, Pennelli G, et al. Prophylactic and early thyroidectomy in RET germline mutation carriers in pediatric and adult population: long-term outcomes of a series of 63 patients. *Cancers (Basel).* 2022;14(24):6226. doi: 10.3390/cancers14246226
125. Machens A, Elwerr M, Thanh PN, et al. Impact of central node dissection on postoperative morbidity in pediatric patients with suspected or proven thyroid cancer. *Surgery.* 2016;160(2):484–492. doi: 10.1016/j.surg.2016.03.007
126. Kiriakopoulos A, Dimopoulou A, Nastos C, et al. Medullary thyroid carcinoma in children: current state of the art and future perspectives. *J Pediatr Endocrinol Metab.* 2022;35(1):1–10. doi: 10.1515/jpem-2021-0502
127. Haddad RI, Bischoff L, Ball D, et al. Thyroid carcinoma, version 2.2022 NCCN CLINICAL PRACTICE GUIDELINES in ONCOLOGY. *J Natl Compr Canc Netw.* 2022;20(8):925–951. doi: 10.6004/jnccn.2022.0040
128. Boccalatte LA, Gómez NL, Musumeci M, et al. PET/TC 4D 18F-colina en el hiperparatiroidismo: correlación entre datos bioquímicos y parámetros del estudio. *Rev Esp Med Nucl Imagen Mol.* 2020;39(5):273–278. doi: 10.1016/j.remnm.2020.03.017
129. RUBELLO D, SALADINI G, CASARA D, et al. Parathyroid imaging with pertechneate plus perchlorate/MIBI subtraction scintigraphy. *Clin Nucl Med.* 2000;25(7):527–531. doi: 10.1097/00003072-200007000-00007
130. Kiernan CM, Grubbs EG. Surgical management of multiple endocrine neoplasia 1 and multiple endocrine neoplasia 2. *Surgical Clinic North Am.* 2019;99(4):693–709. doi: 10.1016/j.suc.2019.04.015
131. Dottorini ME, Assi A, Sironi M, et al. Multivariate analysis of patients with medullary thyroid carcinoma: prognostic significance and impact on treatment of clinical and pathologic variables. *Cancer.* 1996;77(8):1556–1565. doi: 10.1002/(SICI)1097-0142(19960415)77:8<1556:AID-CNCR20>3.0.CO;2-Y
132. Saad MF, Ordóñez NG, Rashid RK, et al. Medullary carcinoma of the thyroid. A study of the clinical features and prognostic factors in 161 patients. *Medicine.* 1984;63(6):319–342. doi: 10.1097/00005792-19841000-00001
133. Valenta LJ, Michel-Bechet M, Mattson JC, et al. Microfollicular thyroid carcinoma with amyloid rich stroma, resembling the medullary carcinoma of the thyroid (MCT). *Cancer.* 1977;39(4):1573–1586. doi: 10.1002/1097-0142(197704)39:4<1573:AID-CNCR2820390433>3.0.CO;2-A
134. Santosh K, Raychaudhuri H, Subramanya S, et al. Cytology of hyalinizing trabecular adenoma-like variant of medullary thyroid carcinoma. *J Cancer Res Ther.* 2011;7(2):189. doi: 10.4103/0973-1482.82916
135. Golouh R, Us-Krasovec J, Bondi A, et al. Amphicrine—composite calcitonin and Mucin-producing—carcinoma of the thyroid. *Ultrastructural Pathology.* 1985;8(2–3):197–206. doi: 10.3109/01913128509142153
136. Wang YX, Yang SJ. Spindle cell variant of medullary thyroid carcinoma: a clinicopathologic study of four cases. *Diagn Pathol.* 2021;16(1):112. doi: 10.1186/s13000-021-01152-w
137. Landon G, Ordóñez NG. Clear cell variant of medullary carcinoma of the thyroid. *Hum Pathol.* 1985;16(8):844–847. doi: 10.1016/S0046-8177(85)80257-4
138. Beskid M, Lorenc R, Rościszewska A. C-cell thyroid adenoma in man. *J Pathol.* 1971;103(1):1–4. doi: 10.1002/path.1711030102
139. HARACH HR, WILLIAMS ED. Glandular (tubular and follicular) variants of medullary carcinoma of the thyroid. *Histopathology.* 1983;7(1):83–97. doi: 10.1111/j.1365-2559.1983.tb02218.x
140. Kakudo K, Miyauchi A, Ogihara T, et al. Medullary carcinoma of the thyroid. Giant cell type. *Arch Pathol Lab Med.* 1978;102(9):445–447.
141. BEERMAN H, RIGAUD C, BOGOMOLETZ WV, et al. Melanin production in black medullary thyroid carcinoma (MTC). *Histopathology.* 1990;16(3):227–233. doi: 10.1111/j.1365-2559.1990.tb01108.x
142. Dominguez-Malagon H, Delgado-Chavez R, Torres-Najera M, et al. Oxyphil and squamous variants of medullary thyroid carcinoma. *Cancer.* 1989;63(6):1183–1188. doi: 10.1002/1097-0142(19890315)63:6<1183:AID-CNCR2820630624>3.0.CO;2-3
143. Sambade C, Baldaque-Faria A, Cardoso-Oliveira M, et al. Follicular and papillary variants of medullary carcinoma of the thyroid. *Pathol Res Pract.* 1988;184(1):98–103. doi: 10.1016/S0344-0338(88)80198-5
144. Huss LJ, Mendelsohn G. Medullary carcinoma of the thyroid gland: an encapsulated variant resembling the hyalinizing trabecular (paraganglioma-like) adenoma of thyroid. *Mod Pathol.* 1990;3(5):581–585.
145. Collina G, Maiorana A, Fano RA, et al. Medullary carcinoma of the thyroid gland with sustentacular cell-like cells in a patient with multiple endocrine neoplasia, type IIA. Report of a case with ultrastructural and immunohistochemical studies. *Arch Pathol Lab Med.* 1994;118(10):1041–1044.
146. Kawanishi N, Norimatsu Y, Ohsaki H, et al. Diagnosis of pseudopapillary variant of medullary thyroid carcinoma by fine-needle aspiration cytology. *Diagn Cytopathol.* 2014;42(9):823–826. doi: 10.1002/dc.23020
147. Albores-Saavedra J, LiVolsi VA, Williams ED. Medullary carcinoma. *Semin Diagn Pathol.* 1985;2(2):137–146.
148. Pusztaszeri MP, Bongiovanni M, Faquin WC. Update on the Cytologic and molecular features of medullary thyroid carcinoma. *Adv Anat Pathol.* 2014;21(1):26–35. doi: 10.1097/PAP.0000000000000004
149. van Veelen W, de Groot JWB, Acton DS, et al. Medullary thyroid carcinoma and biomarkers: past, present and future. *J Intern Med.* 2009;266(1):126–140. doi: 10.1111/j.1365-2796.2009.02106.x

150. Juweid ME, Hajjar G, Swayne LC, et al. Phase I/II trial of 131I-MN-14 F (ab)2 anti-carcinoembryonic antigen monoclonal antibody in the treatment of patients with metastatic medullary thyroid carcinoma. *Cancer*. 1999;85(8):1828–1842. doi: [10.1002/\(SICI\)1097-0142\(19990415\)85:8<1828::AID-CNCR25>3.0.CO;2-H](https://doi.org/10.1002/(SICI)1097-0142(19990415)85:8<1828::AID-CNCR25>3.0.CO;2-H)
151. Schröder S, Klöppel G. Carcinoembryonic antigen and nonspecific cross-reacting antigen in thyroid cancer an immunocytochemical study using polyclonal and monoclonal antibodies. *Am J Surg Pathol*. 1987;11(2):100–108. doi: [10.1097/00000478-198702000-00003](https://doi.org/10.1097/00000478-198702000-00003)
152. Munitiz V, Martinez-Barba E, Riquelme J, et al. Elevated basal calcitonin levels in a patient with a Hürthle-cell carcinoma of the thyroid and neuroendocrine differentiation: report of a case. *Surg Today*. 2005;35(5):404–406. doi: [10.1007/s00595-004-2928-9](https://doi.org/10.1007/s00595-004-2928-9)
153. Kargi A, Yörükoğlu S, Aktaş FS, et al. Neuroendocrine differentiation in non-neuroendocrine thyroid carcinoma. *Thyroid: Offic J Am Thyroid Association*. 1996;6(3):207–210. doi: [10.1089/thy.1996.6.207](https://doi.org/10.1089/thy.1996.6.207)
154. Hales M, Rosenau W, Okerlund MD, et al. Carcinoma of the thyroid with a mixed medullary and follicular pattern morphologic, immunohistochemical, and clinical laboratory studies. *Cancer*. 1982;50(7):1352–1359. doi: [10.1002/1097-0142\(19821001\)50:7<1352::AID-CNCR2820500722>3.0.CO;2-Q](https://doi.org/10.1002/1097-0142(19821001)50:7<1352::AID-CNCR2820500722>3.0.CO;2-Q)
155. Lindsey SC, Ganly I, Palmer F, et al. Response to initial therapy predicts clinical outcomes in medullary thyroid cancer. *Thyroid: Offic J Am Thyroid Association*. 2015;25(2):242–249. doi: [10.1089/thy.2014.0277](https://doi.org/10.1089/thy.2014.0277)
156. Mian C, Pennelli G, Barollo S, et al. Combined RET and Ki-67 assessment in sporadic medullary thyroid carcinoma: a useful tool for patient risk stratification. *Eur J Endocrinol*. 2011;164(6):971–976. doi: [10.1530/EJE-11-0079](https://doi.org/10.1530/EJE-11-0079)
157. Xu B, Fuchs TL, Ahmadi S, et al. International medullary thyroid carcinoma grading system: a validated grading system for medullary thyroid carcinoma. *J Clin Oncol*. 2022;40(1):96–104. doi: [10.1200/JCO.21.01329](https://doi.org/10.1200/JCO.21.01329)
158. Endo M, Huang EC, Roth MY. Newly developed pathologic grading system predicts clinical outcomes in medullary thyroid carcinoma. *Clin Thyroidol*. 2022;34(2):89–91. doi: [10.1089/ct.2022.34.89-91](https://doi.org/10.1089/ct.2022.34.89-91)
159. Araque KA, Gubbi S, Klubo-Gwiedzinska J. Updates on the management of thyroid cancer. *Hormone Metab Res*. 2020;52(8):562–577. doi: [10.1055/a-1089-7870](https://doi.org/10.1055/a-1089-7870)
160. Priya SR, Dravid CS, Digumarti R, et al. Targeted therapy for medullary thyroid cancer: a review. *Front Oncol*. 2017;7. [10.3389/fonc.2017.00238](https://doi.org/10.3389/fonc.2017.00238).
161. Schlumberger M, Jarzab B, Cabanillas ME, et al. A phase II trial of the multitargeted tyrosine kinase inhibitor Lenvatinib (E7080) in advanced medullary thyroid cancer. *Clin Cancer Res*. 2016;22(1):44–53. doi: [10.1158/1078-0432.CCR-15-1127](https://doi.org/10.1158/1078-0432.CCR-15-1127)
162. Kim M, Kim BH. Current guidelines for management of medullary thyroid carcinoma. *Endocrinol Metab*. 2021;36(3):514–524. doi: [10.3803/EnM.2021.1082](https://doi.org/10.3803/EnM.2021.1082)
163. Baek H-S, Ha J, Ha S, et al. Initial Experiences of selective RET inhibitor selpercatinib in adults with metastatic differentiated thyroid carcinoma and medullary thyroid carcinoma: real-World case series in Korea. *Current Oncol*. 2023;30(3):3020–3031. doi: [10.3390/curroncol30030229](https://doi.org/10.3390/curroncol30030229)
164. Jozaghi Y, Zafereo M, Williams MD, et al. Neoadjuvant selpercatinib for advanced medullary thyroid cancer. *Head Neck*. 2021;43(1):E7–E12. doi: [10.1002/hed.26527](https://doi.org/10.1002/hed.26527)
165. Reubi JC, Schaer JC, Waser B, et al. Expression and localization of somatostatin receptor SSTR1, SSTR2, and SSTR3 messenger RNAs in primary human tumors using in situ hybridization. *Cancer Res*. 1994;54(13):3455–3459.
166. Parghane RV, Naik C, Talole S, et al. Clinical utility of ¹⁷⁷Lu-DOTATATE PRRT in somatostatin receptor-positive metastatic medullary carcinoma of thyroid patients with assessment of efficacy, survival analysis, prognostic variables, and toxicity. *Head Neck*. 2020;42(3):401–416. doi: [10.1002/hed.26024](https://doi.org/10.1002/hed.26024)
167. Maghsoomi Z, Emami Z, Malboosbaf R, et al. Efficacy and safety of peptide receptor radionuclide therapy in advanced radioiodine-refractory differentiated thyroid cancer and metastatic medullary thyroid cancer: a systematic review. *BMC Cancer*. 2021;21(1):579. doi: [10.1186/s12885-021-08257-x](https://doi.org/10.1186/s12885-021-08257-x)
168. Iten F, Müller B, Schindler C, et al. Response to [90Yttrium-DOTA]-TOC treatment is associated with long-term survival benefit in metastasized medullary thyroid cancer: a phase II clinical trial. *Clin Cancer Res*. 2007;13(22):6696–6702. doi: [10.1158/1078-0432.CCR-07-0935](https://doi.org/10.1158/1078-0432.CCR-07-0935)
169. Grossrubatscher E, Fanciulli G, Pes L, et al. Advances in the management of medullary thyroid carcinoma: focus on peptide receptor radionuclide therapy. *J Clin Med MDPI*. 2020;9(2020):1–16.
170. Bhoj VG, Li L, Parvathaneni K, et al. Adoptive T cell immunotherapy for medullary thyroid carcinoma targeting GDNF family receptor alpha 4. *Mol Ther Oncolytics*. 2021;20:387–398. doi: [10.1016/j.omto.2021.01.012](https://doi.org/10.1016/j.omto.2021.01.012)
171. Fuziwara CS, de Mello DC, Kimura ET. Gene editing with CRISPR/Cas methodology and thyroid cancer: where are we? *Cancers (Basel)*. 2022;14:844. doi: [10.3390/cancers14030844](https://doi.org/10.3390/cancers14030844)

•• of considerable interest